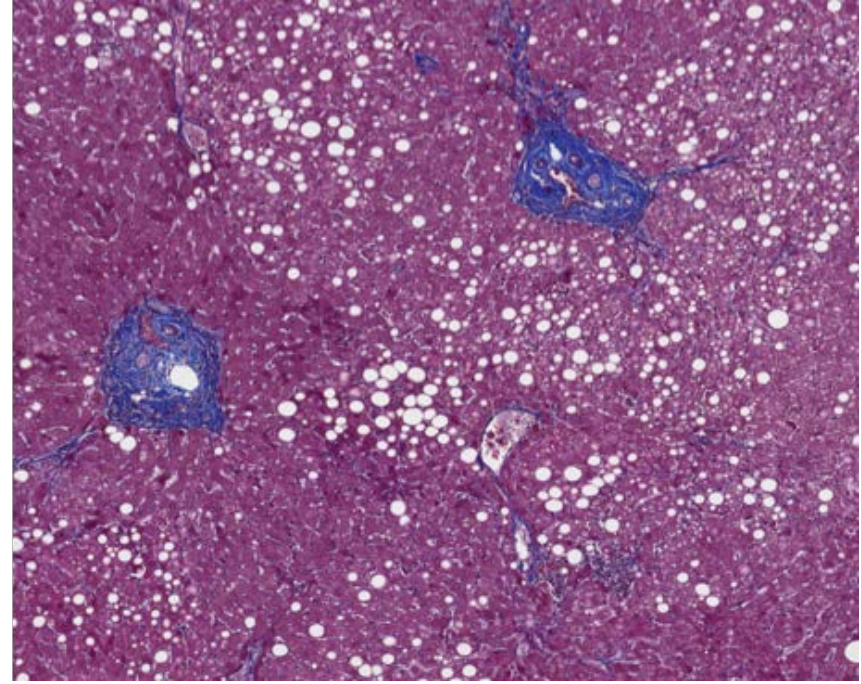
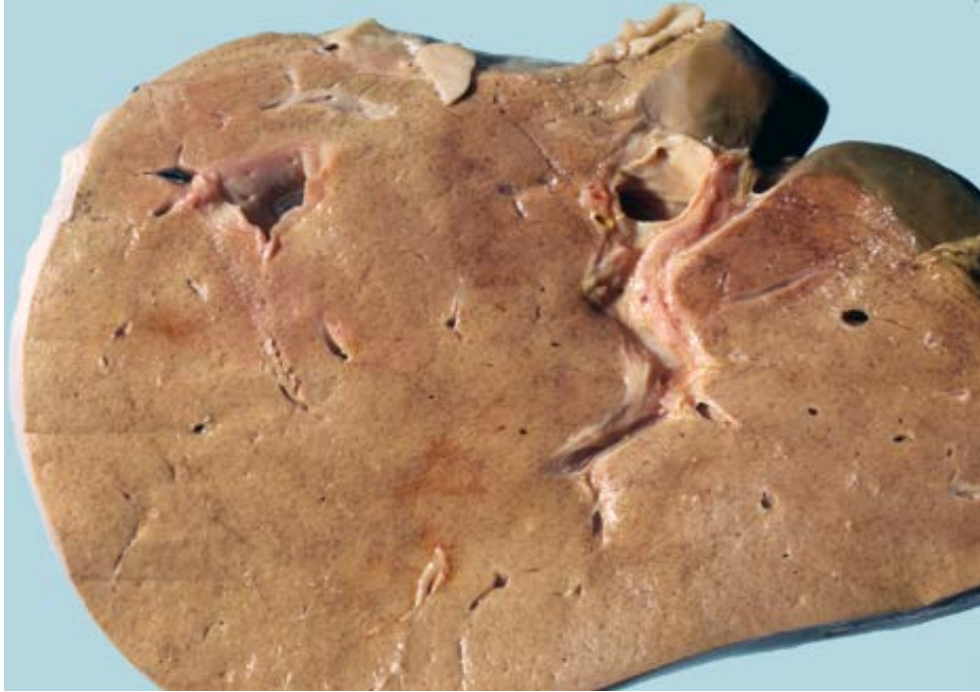

Stéatose

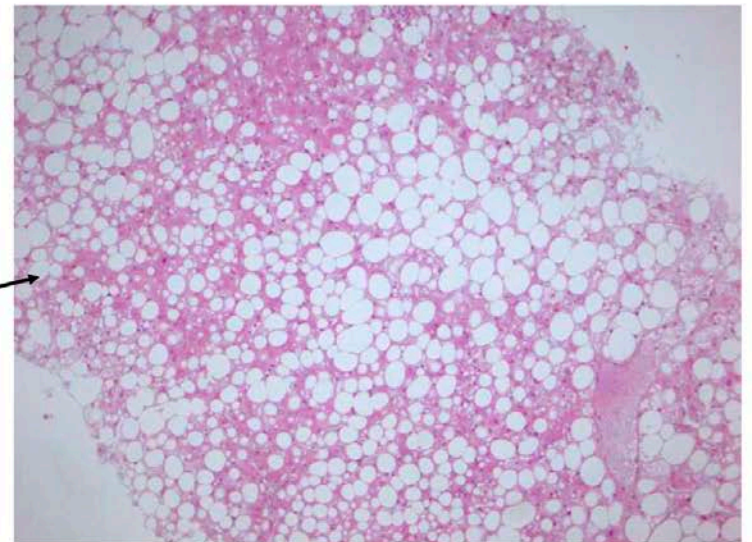
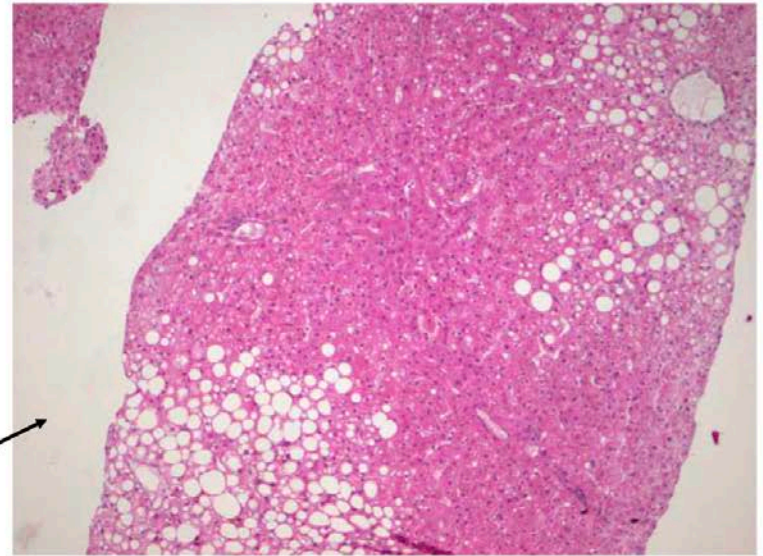
- US : hyperéchogène
- TDM : hypodense
- IRM : hypointense en T1 out of phase
- Stéatose peut être hétérogène

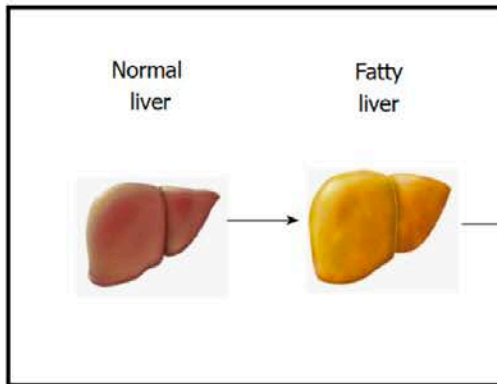




Stéatose

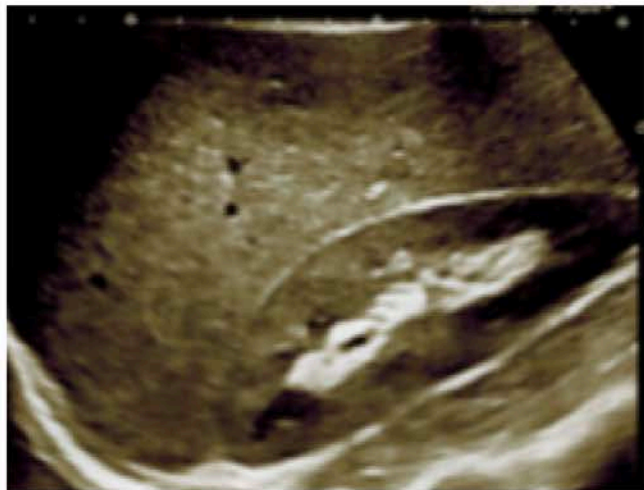- Gradation : 5 stades
 - 0 % / 1-5 %
 - 6-33 %
 - 34-66 %
 - ≥ 67 %...





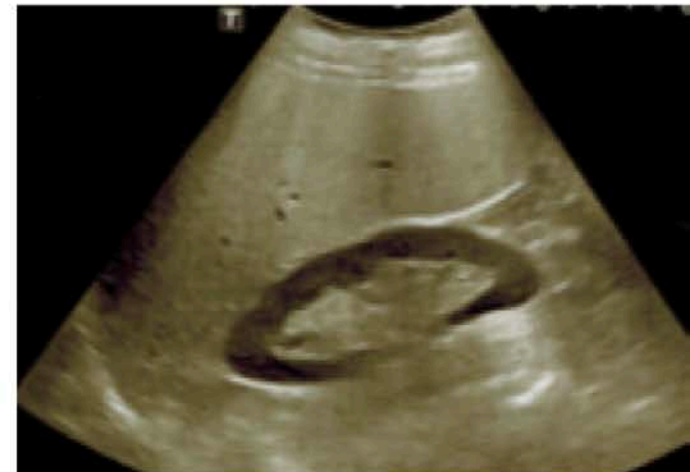Stéatose

enjeu de l'échographie



hyperéchogénicité :
objective

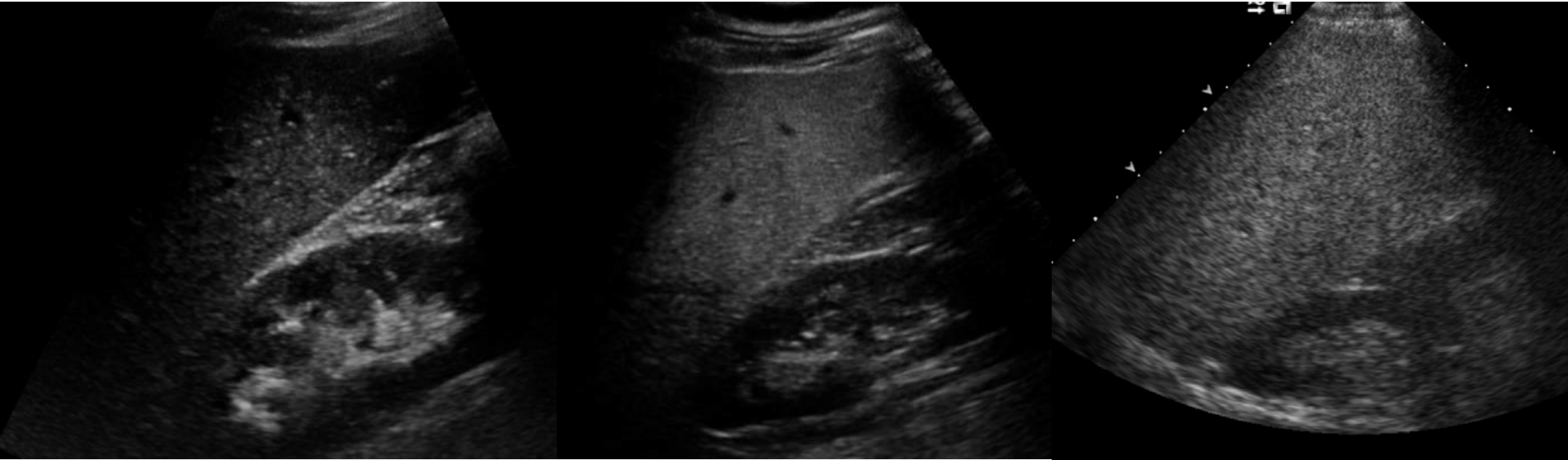diffuse



signes écho à partir de 30 %
hyperéchogénicité % teneur en graisse

gradient hépato rénal facile
mais difficile de quantifier et non spécifique

US et maladie de surcharge: stéatose // hémochromatose

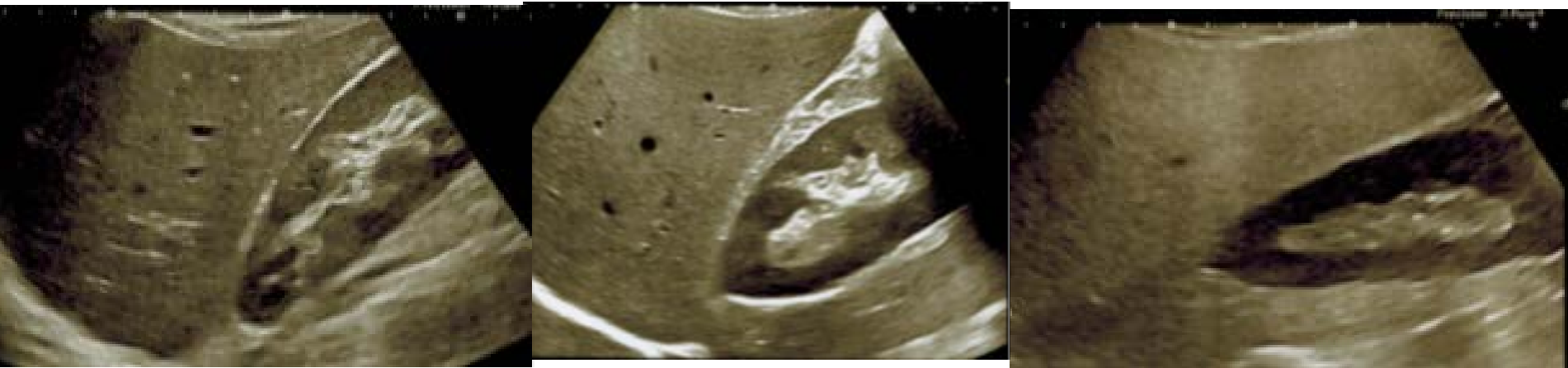

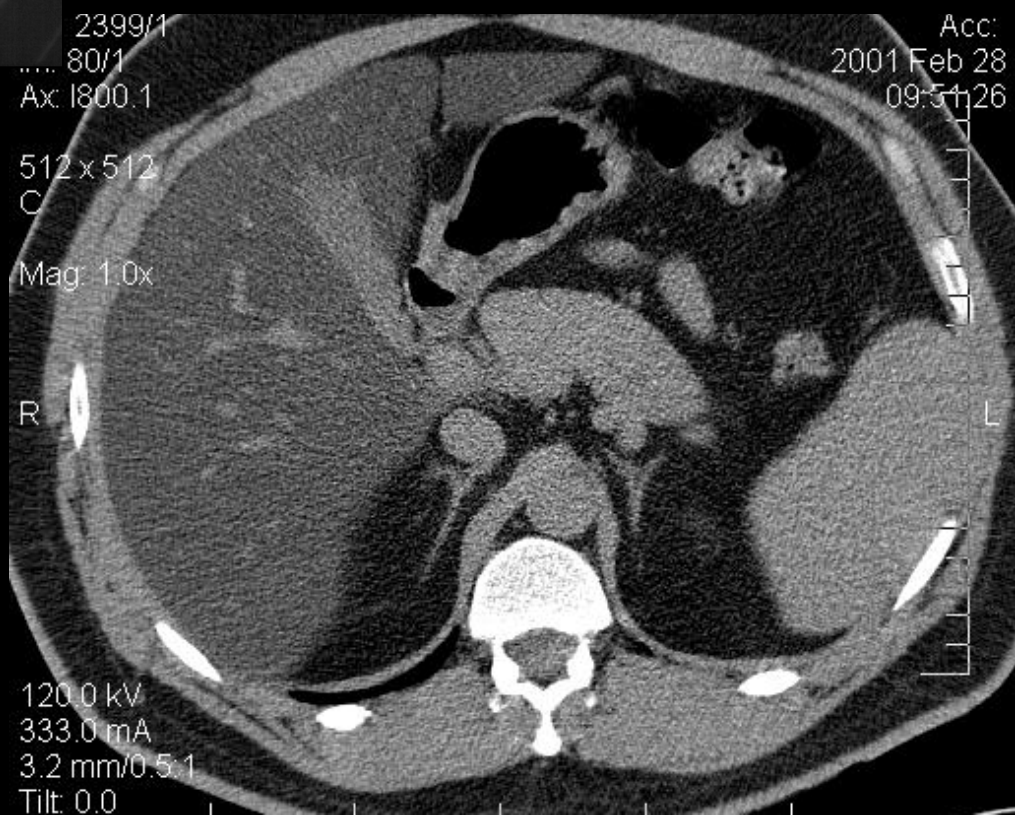
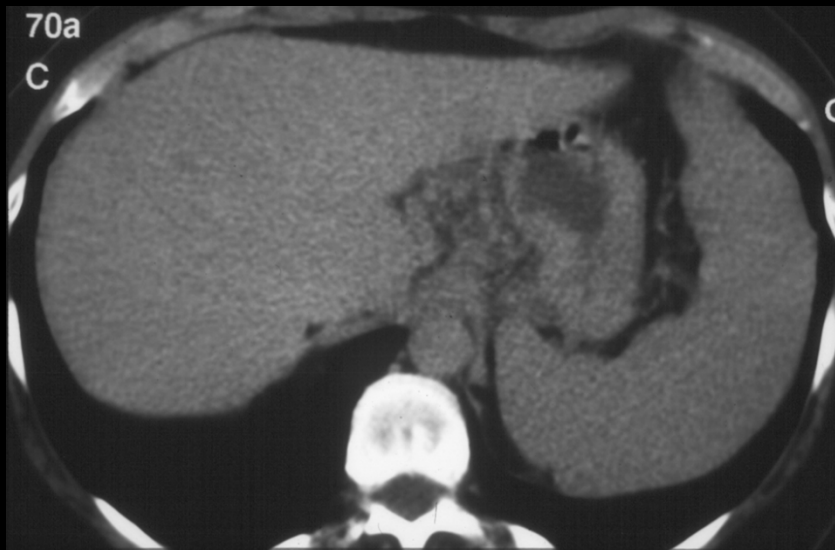
Gradient hépato-rénal:

- normal-

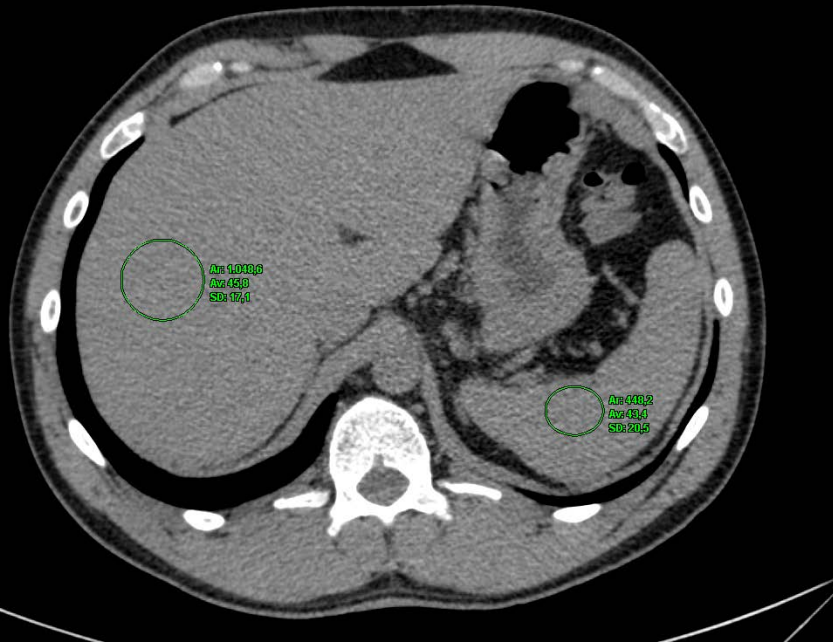
- majoré-

- majoré

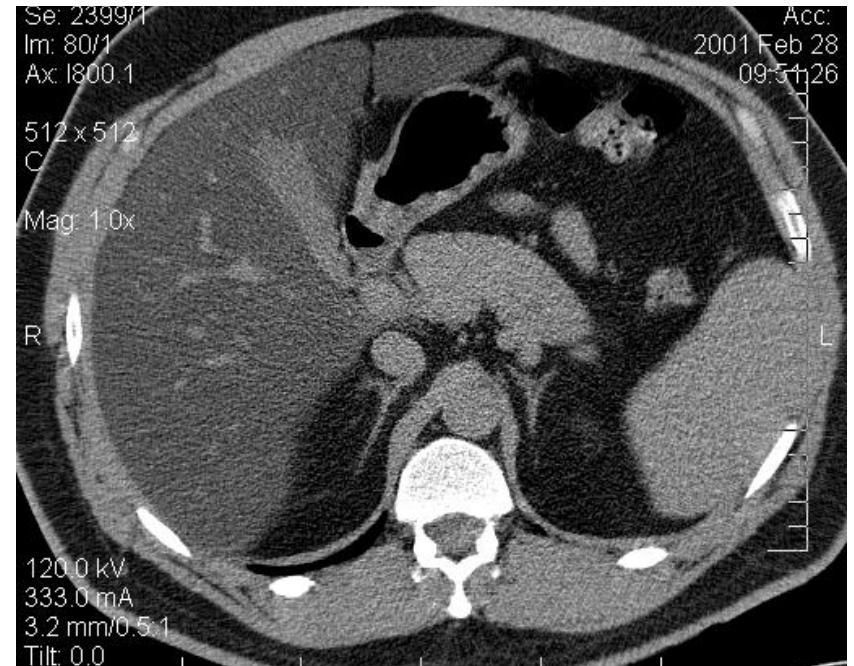




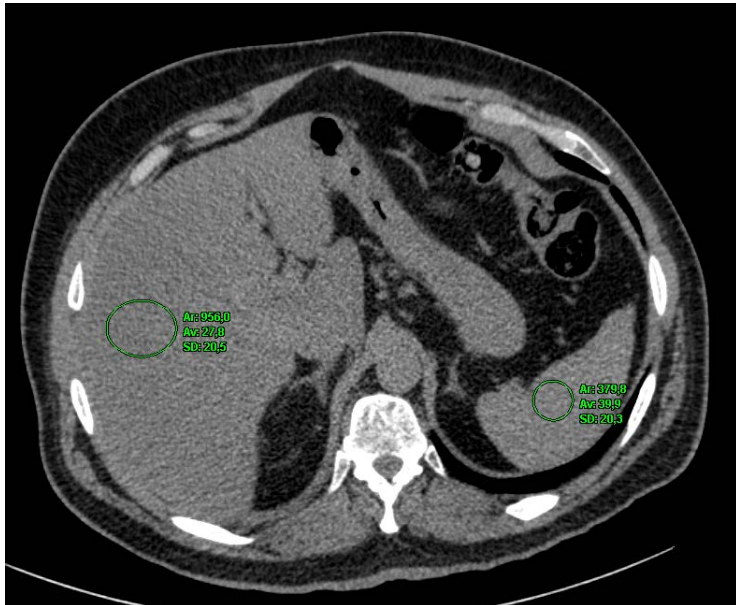
CT et maladie de surcharge : stéatose



Densité UH foie 46 et rate 43

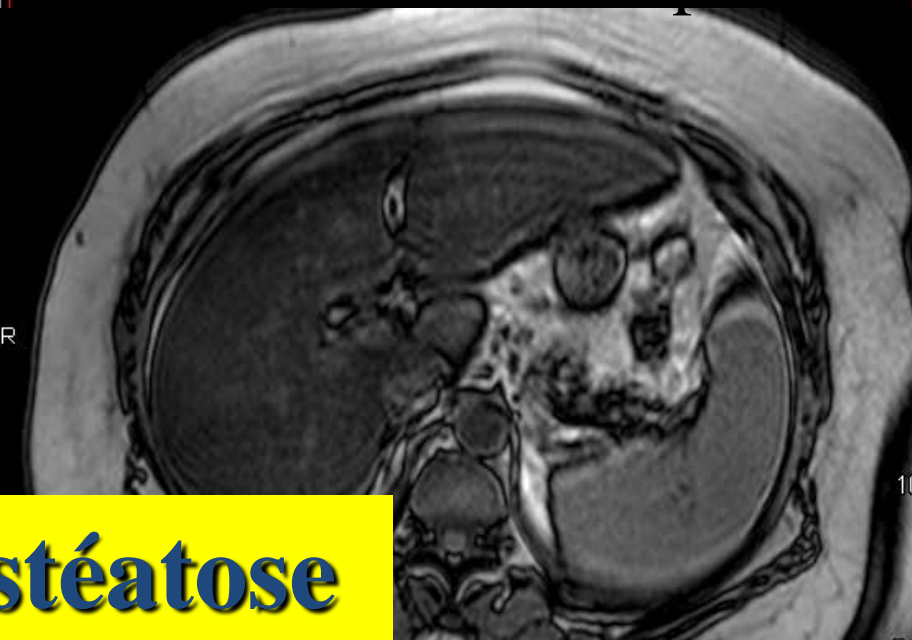
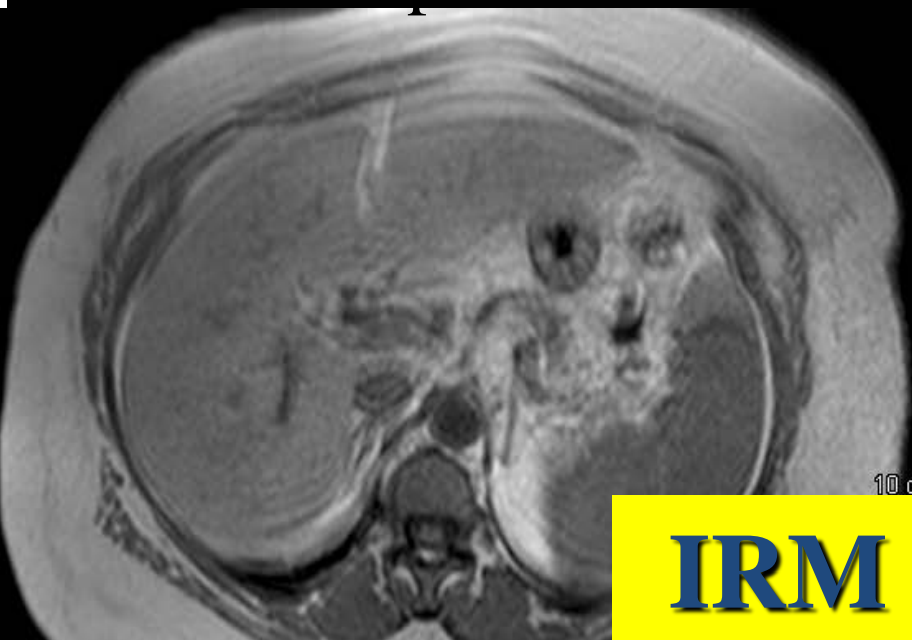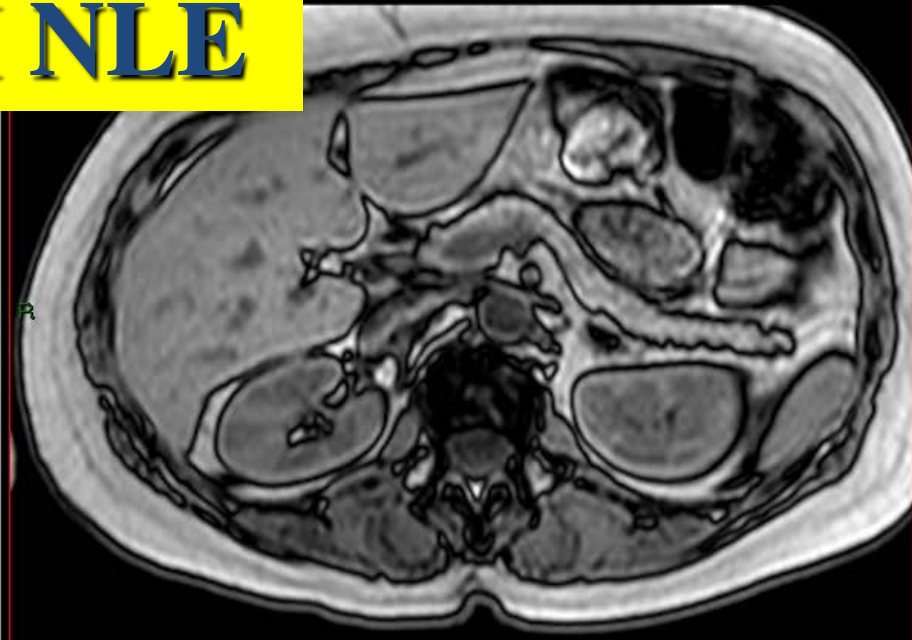
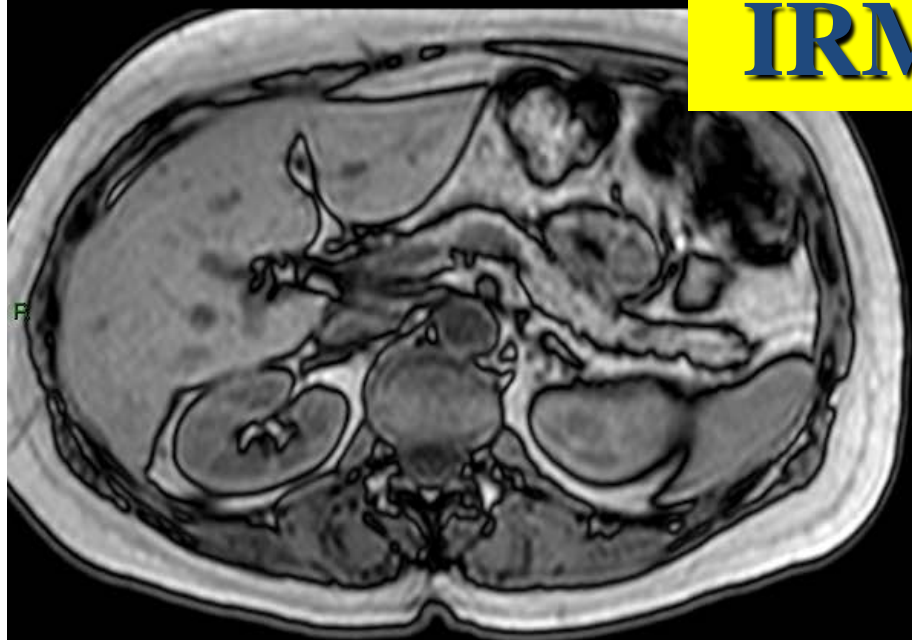


CT sans injection

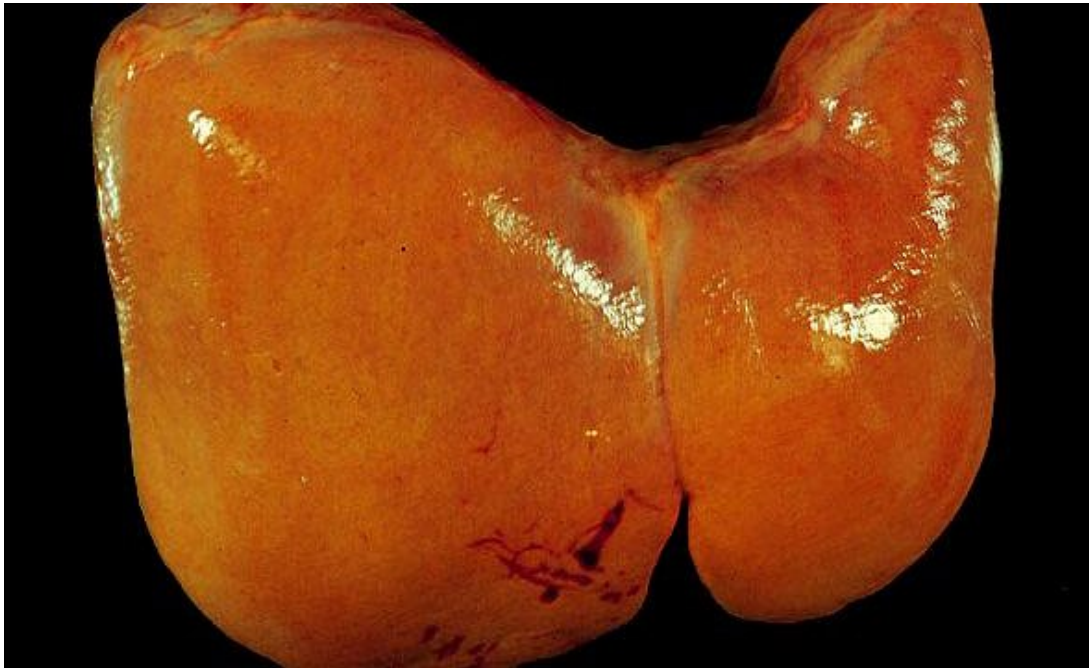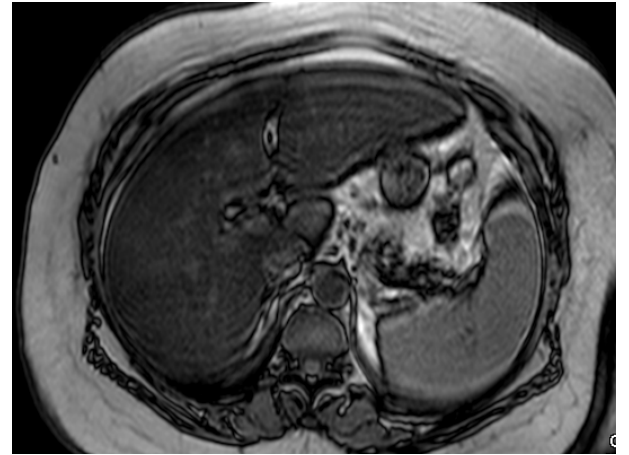
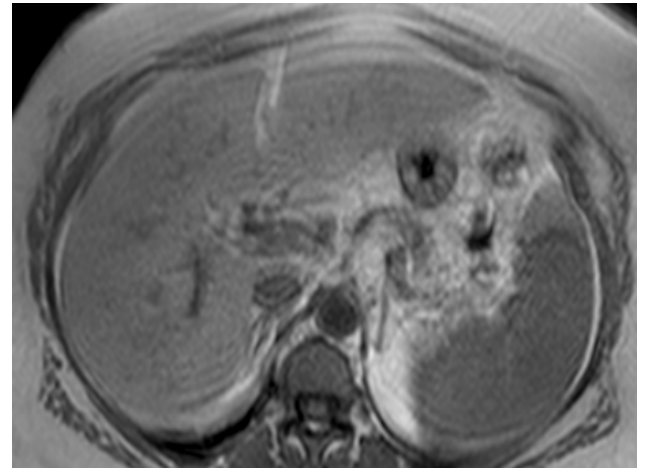
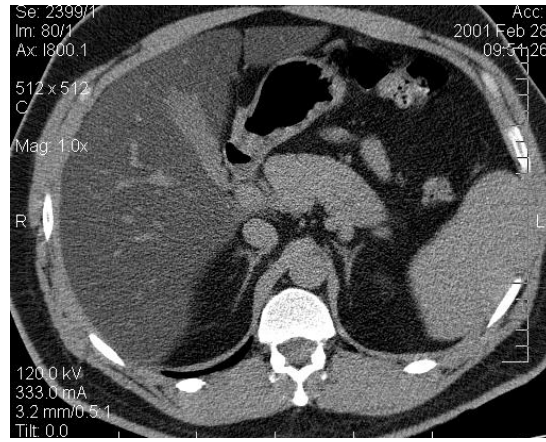
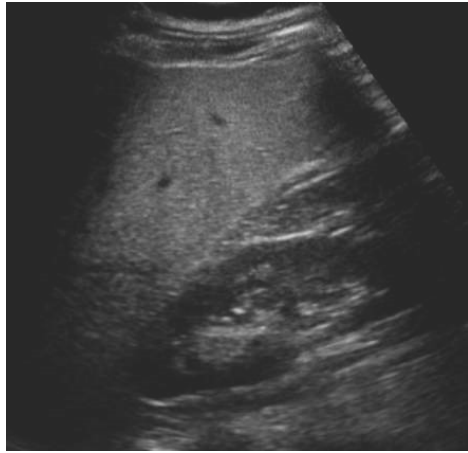


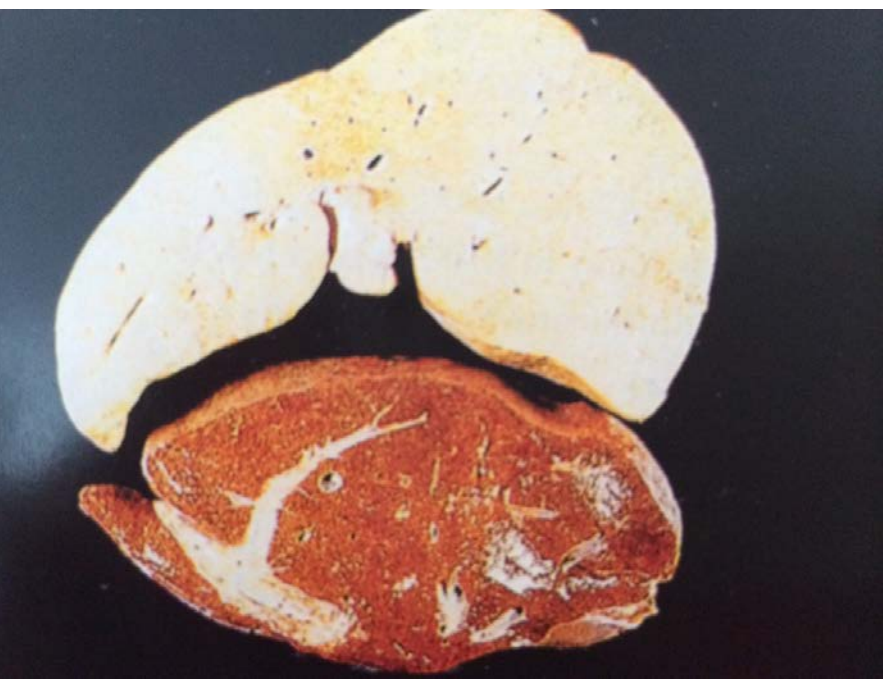Densité UH foie 27 et rate 40

IRM NLE

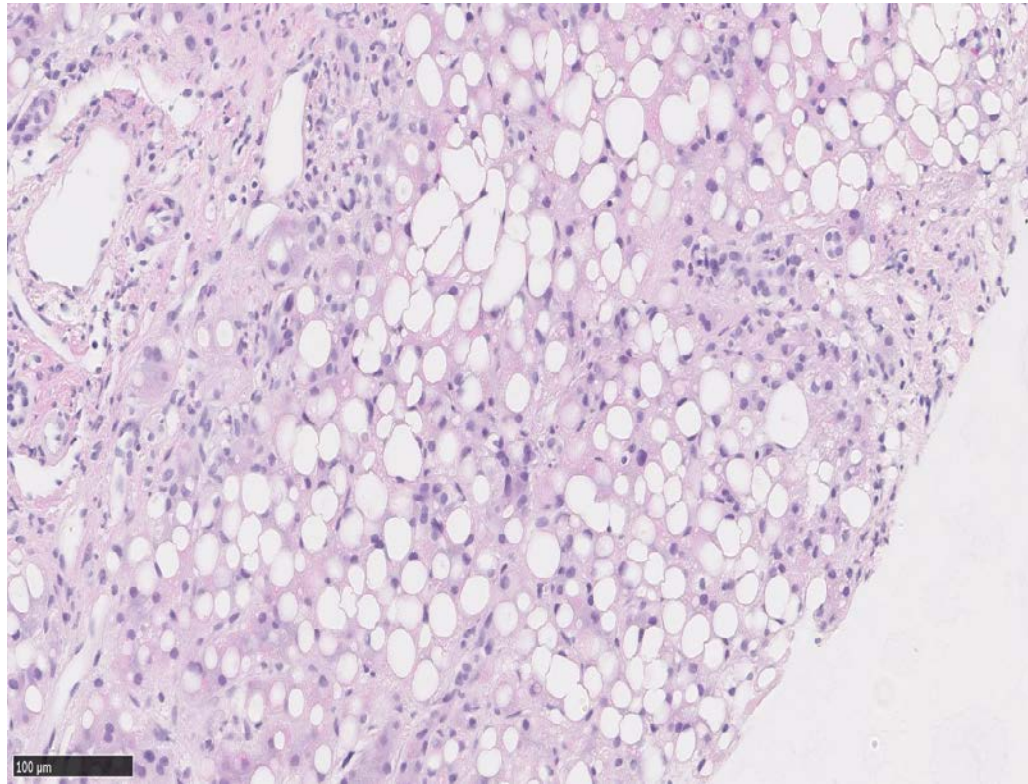


IRM stéatose



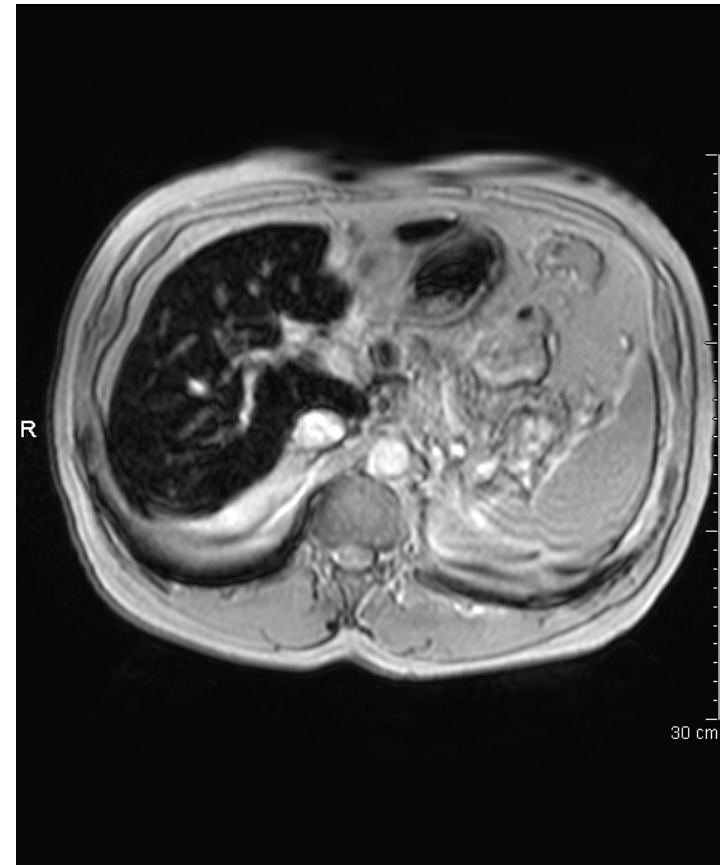


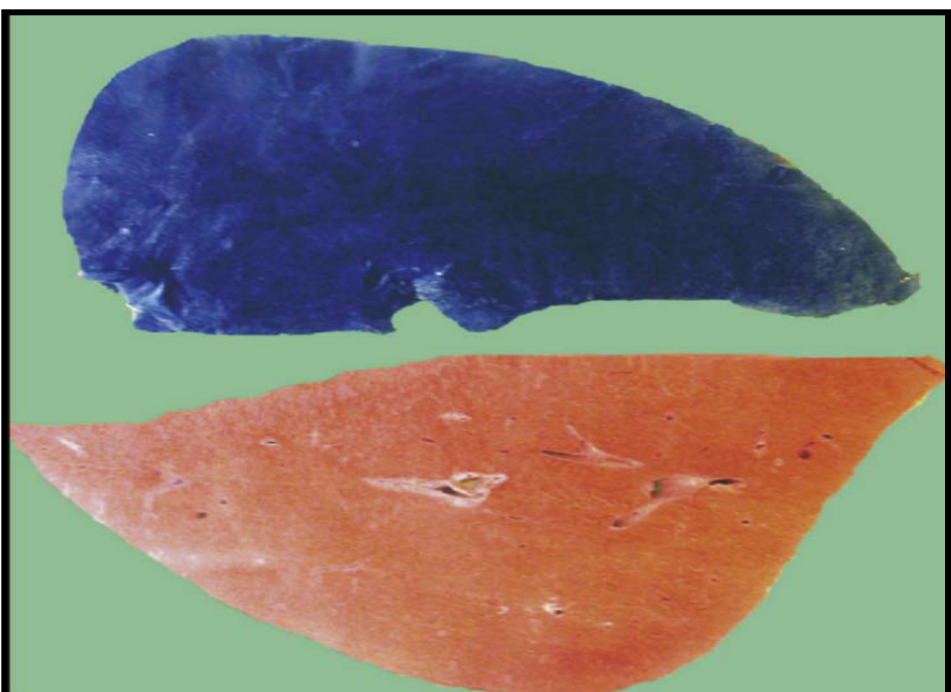
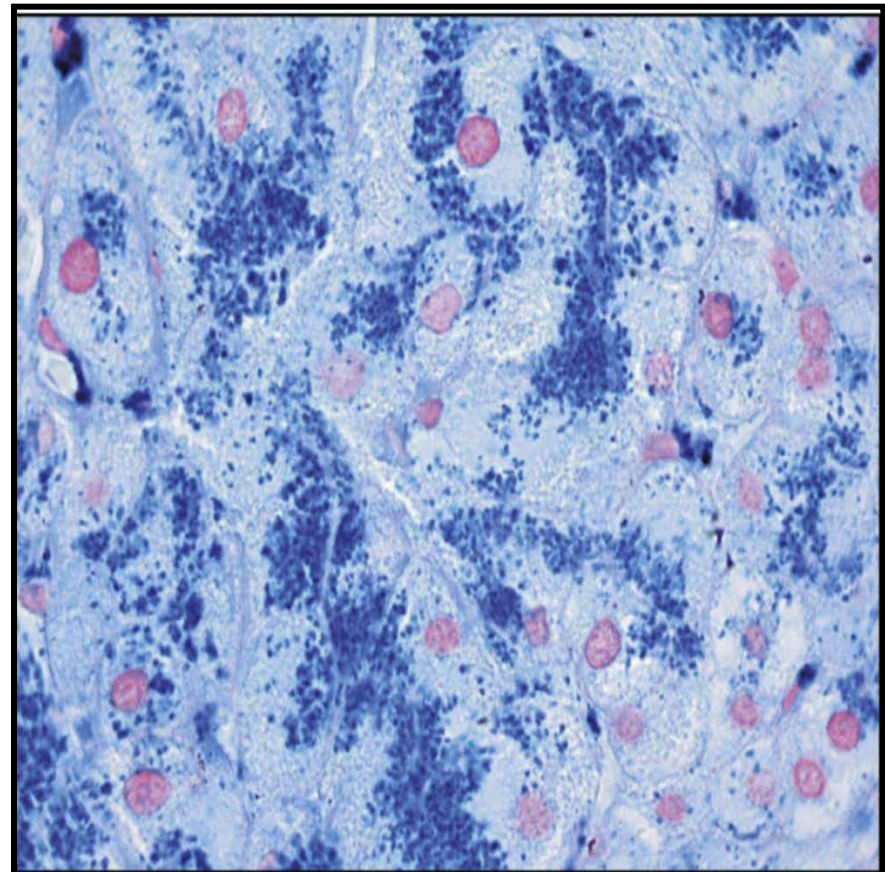
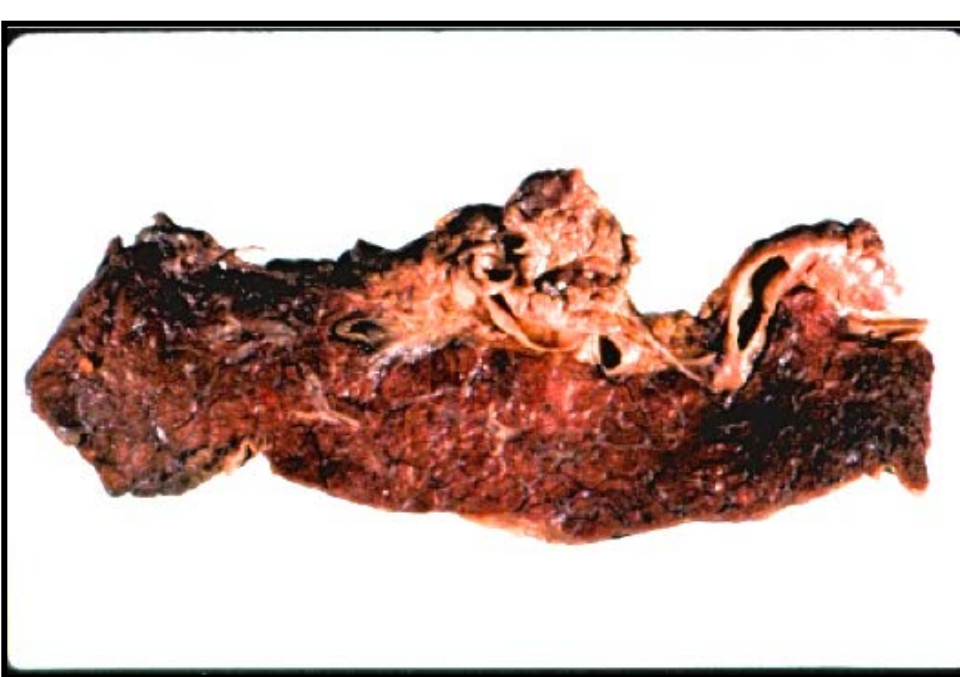Steatose



Hémochromatose

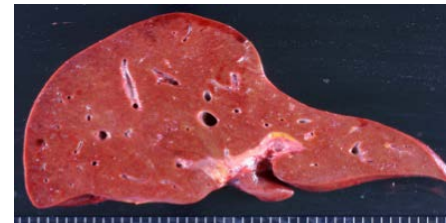
- IRM : hyposignal en particulier en T2 et en écho de gradient
- Méthode de Calcul automatisée





Hémochromatose-Stéatose

- Hémochromatose :
 - isolée : pas de signe de surcharge en fer visible en écho
 - compliquée d'une stéatose : on voit la stéatose en écho
 - Évolution vers la fibrose puis la cirrhose et ses complications
- Hyperferritinémie
 - NAFLD et AFLD



Cirrhose

- Atrophie en particulier du lobe droit
- Hypertrophie du lobe caudé et du lobe gauche
- Contours nodulaires
- Hypertension portale
 - Splénomégalie
 - Ascite
 - Circulation veineuse portosytémique
 - Diminution de la vitesse dans la veine porte
- TIPSS

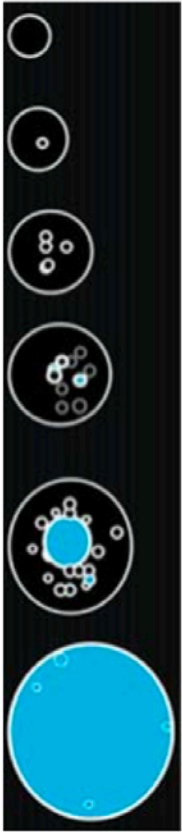
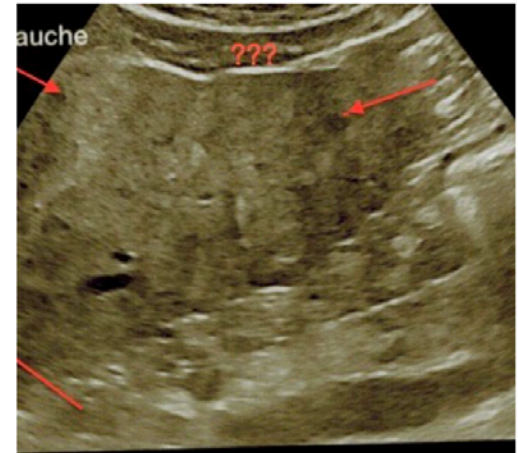
cirrhose



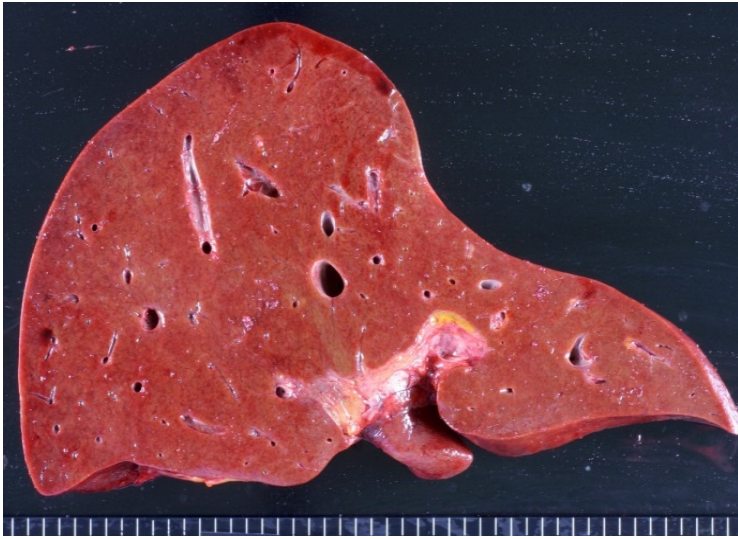Nodule de régénération

Nodule dysplasique

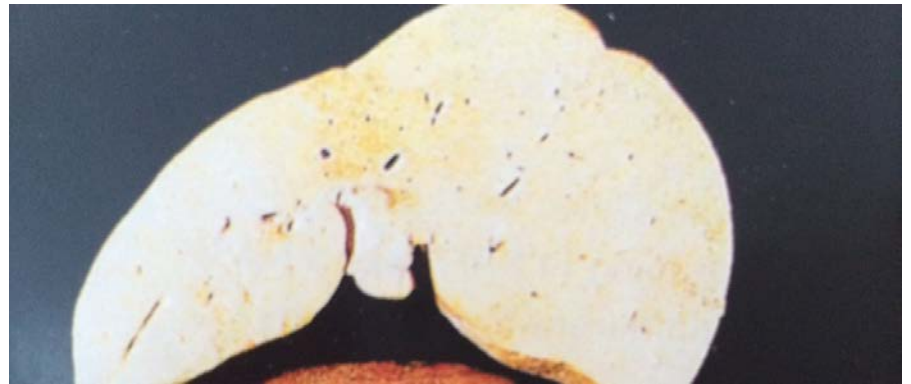Carcinome hépatocellulaire



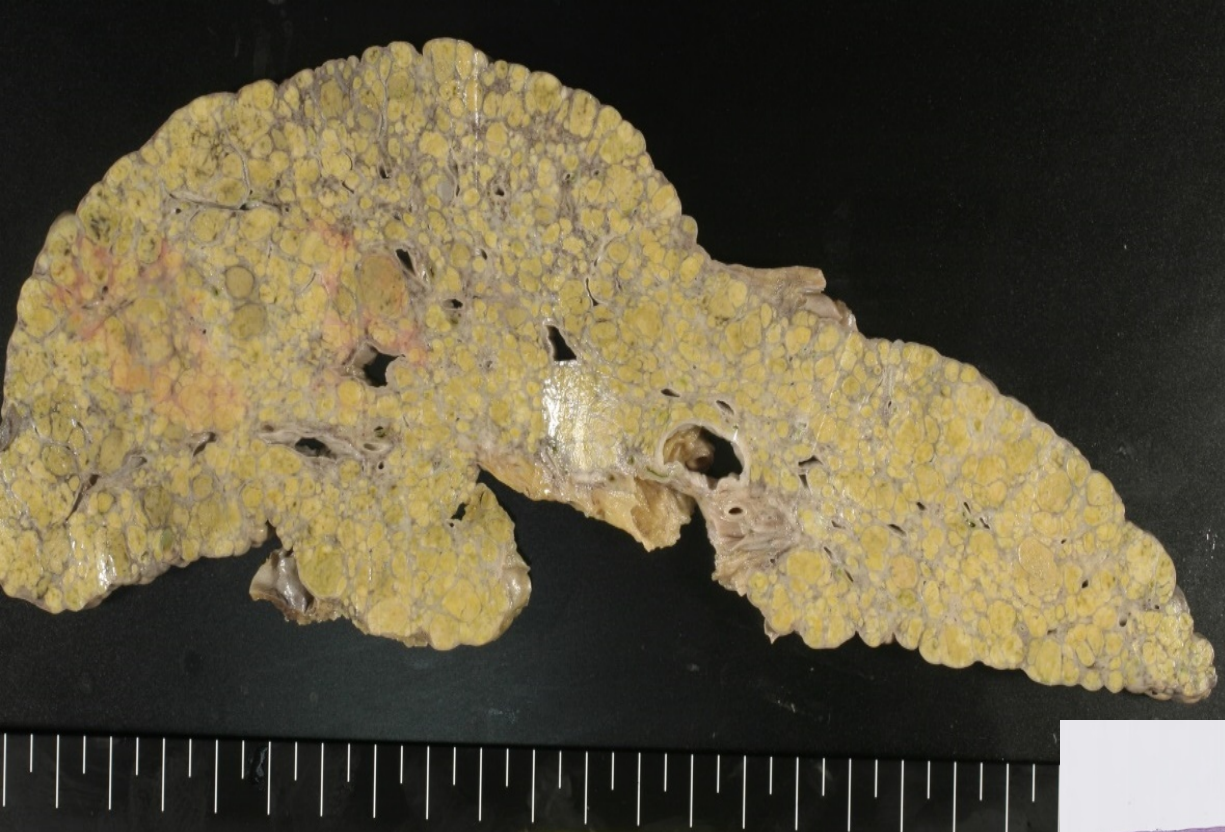Il semble exister un continuum évolutif entre ces trois entités, ces transitions s'accompagnant d'une augmentation de la taille, de la cellularité et de la néoangiogenèse de ces différents nodules



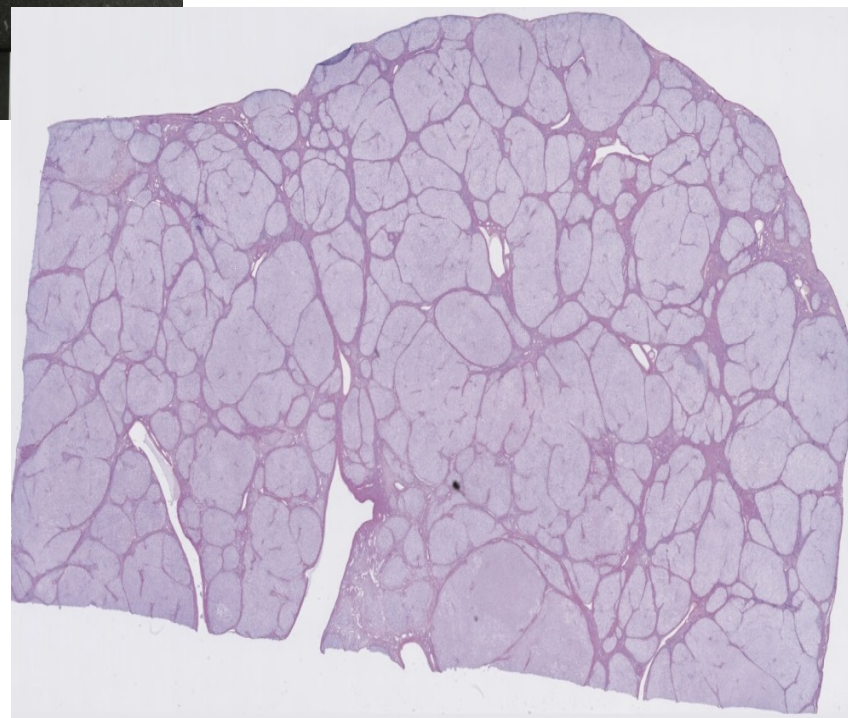
Foie normal



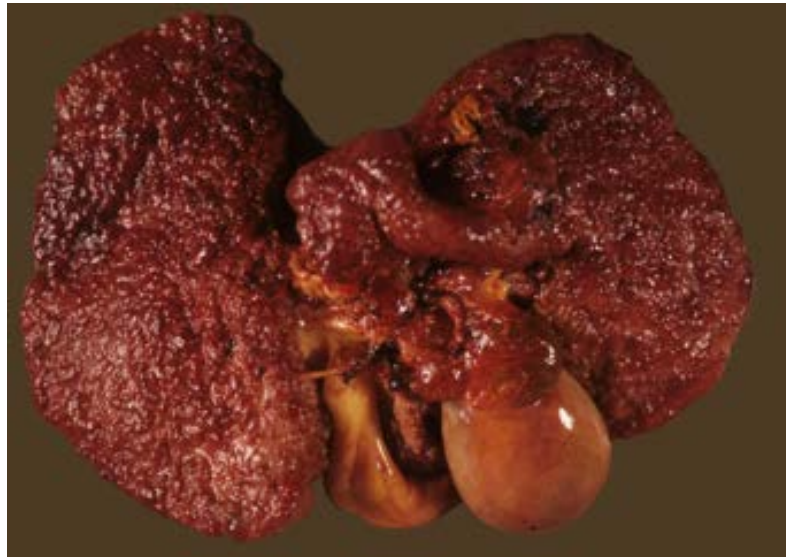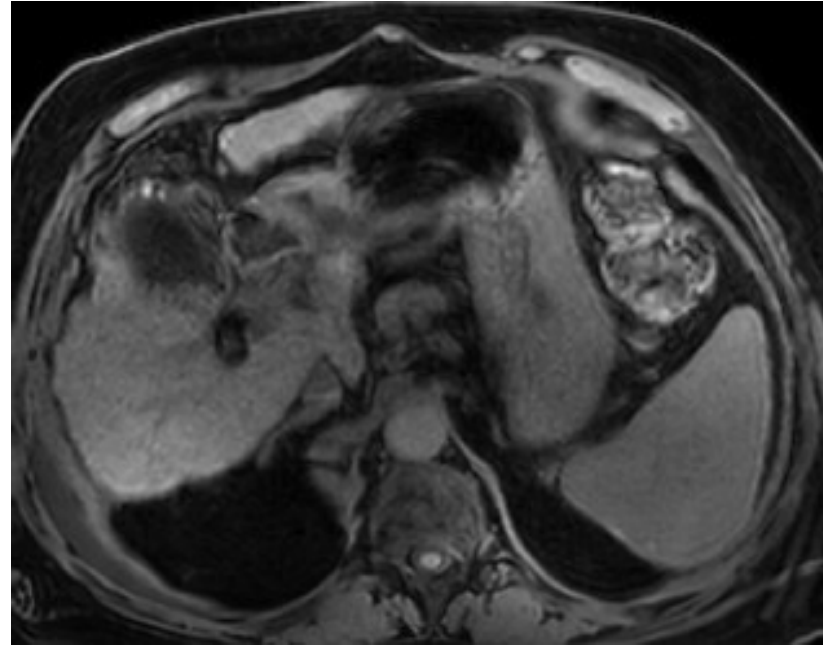
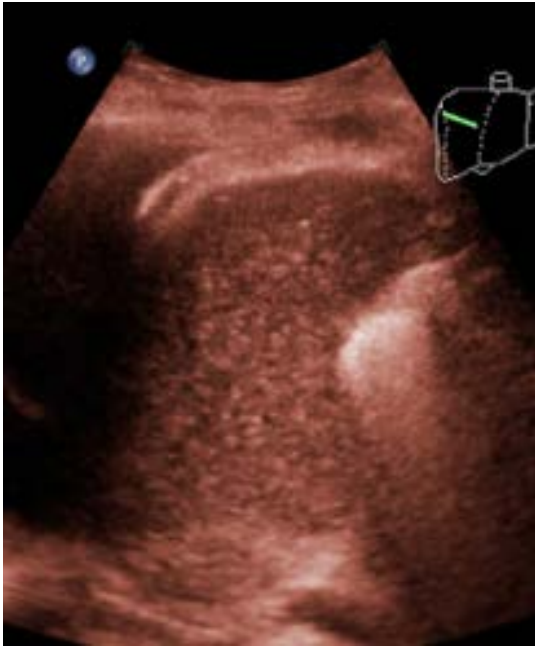Foie stéatosique



Foie cirrhotique

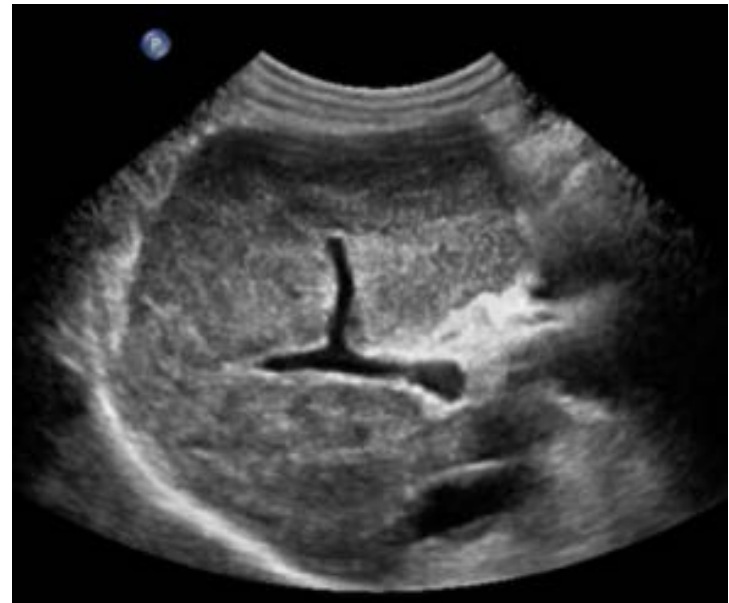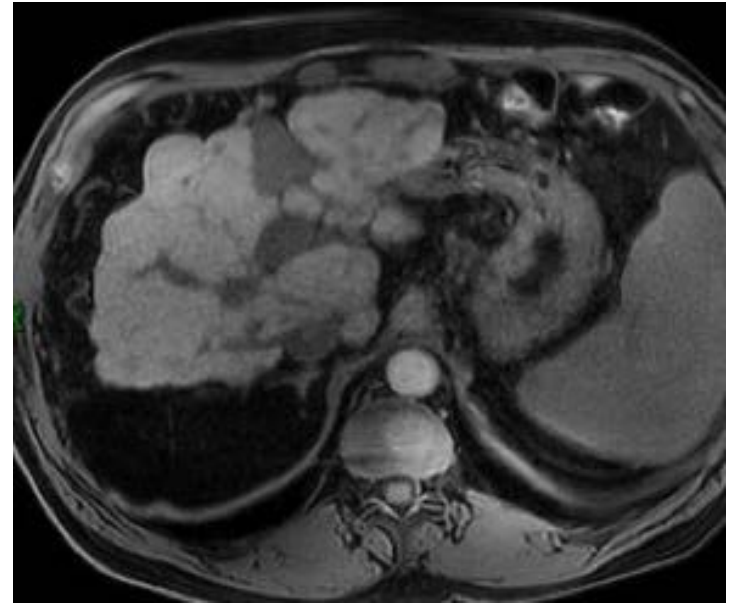
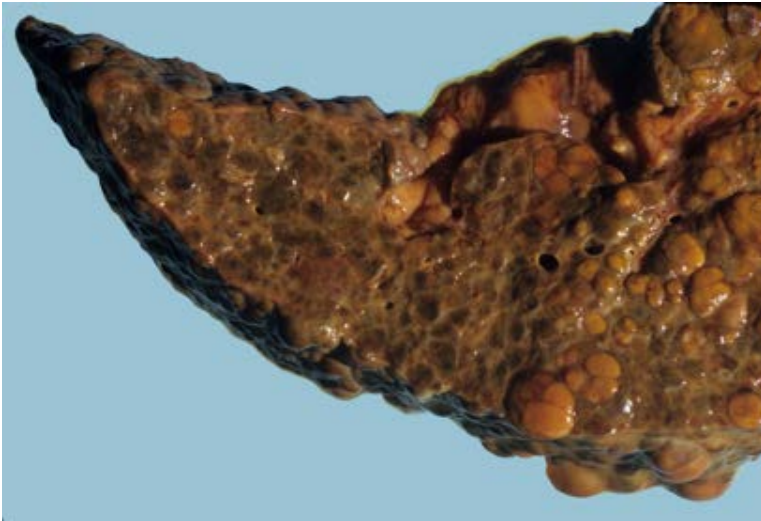


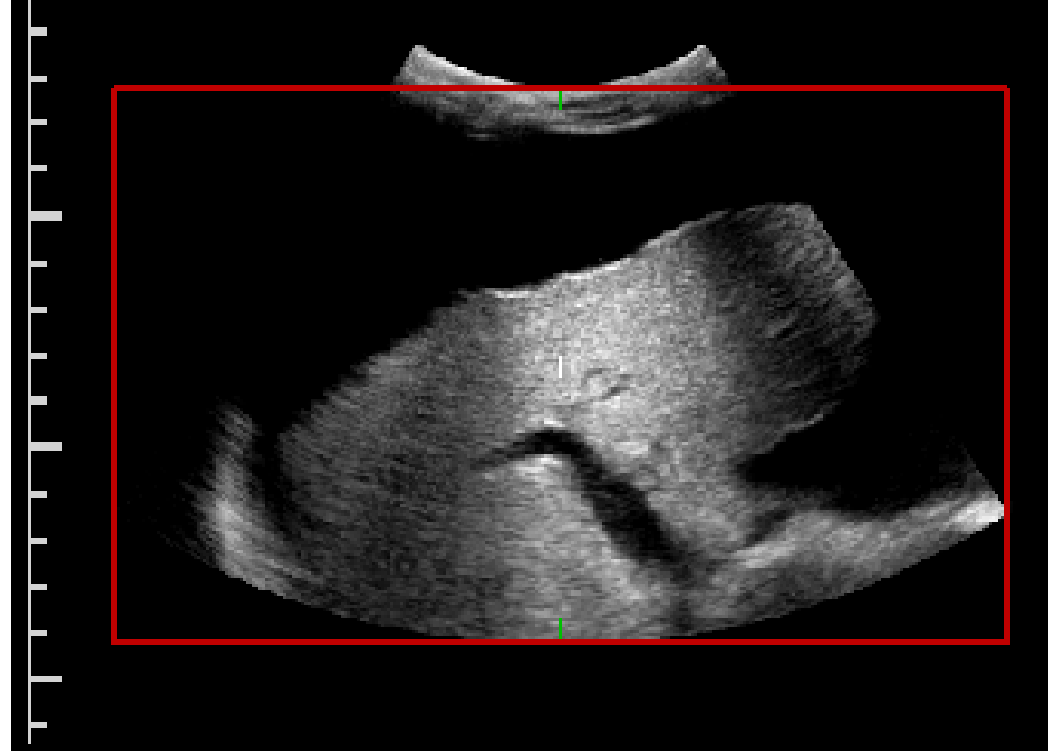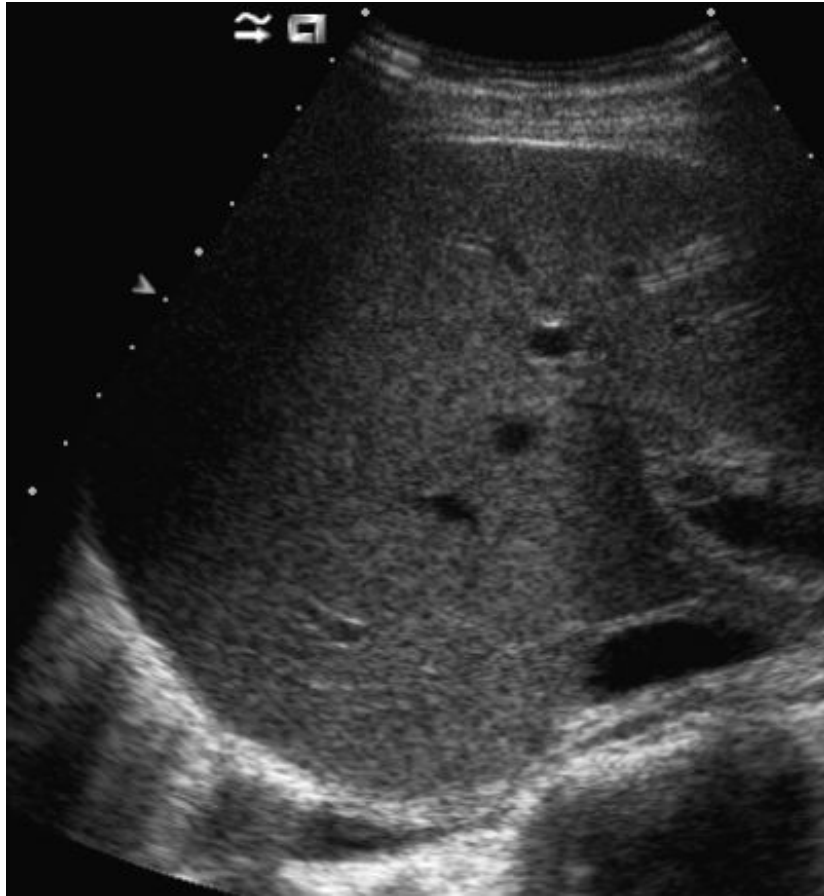cirrhose





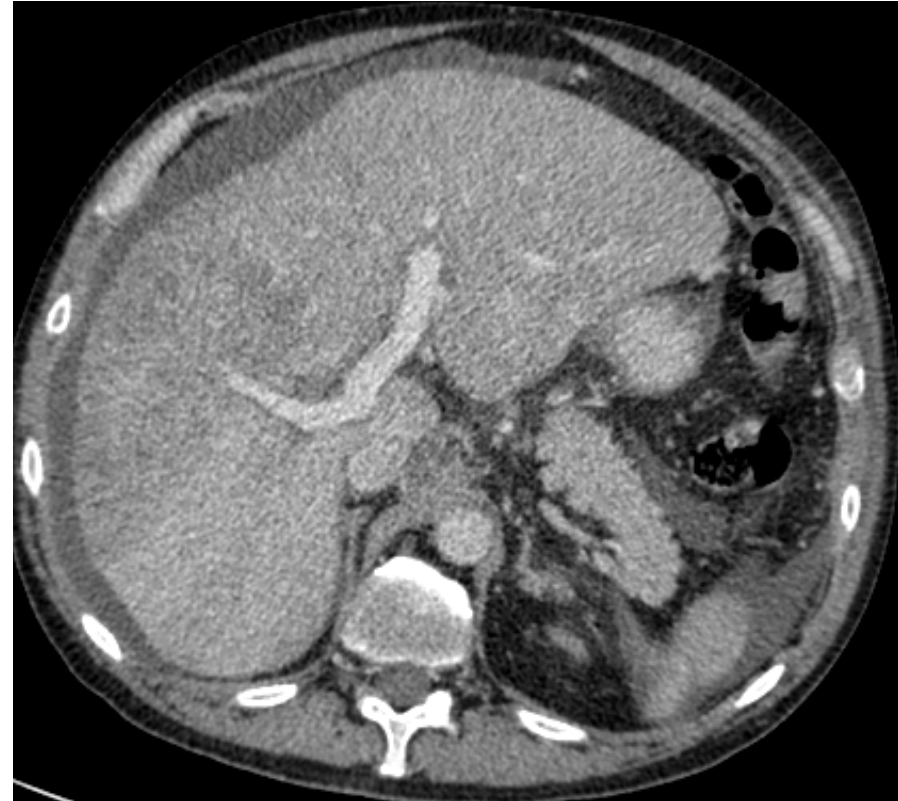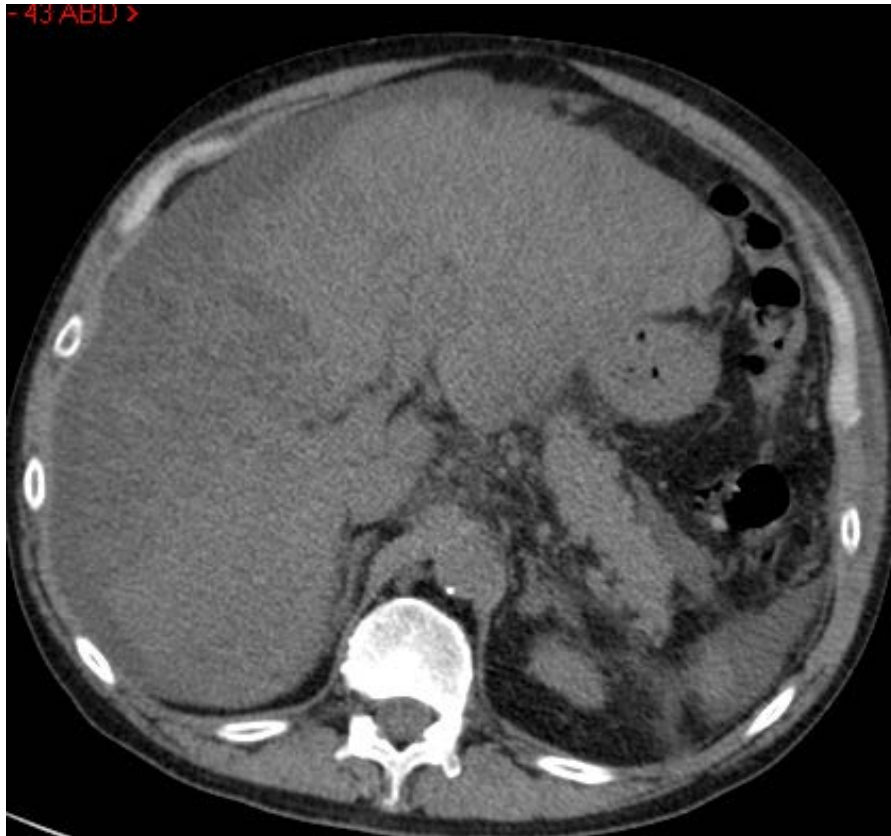cirrhose





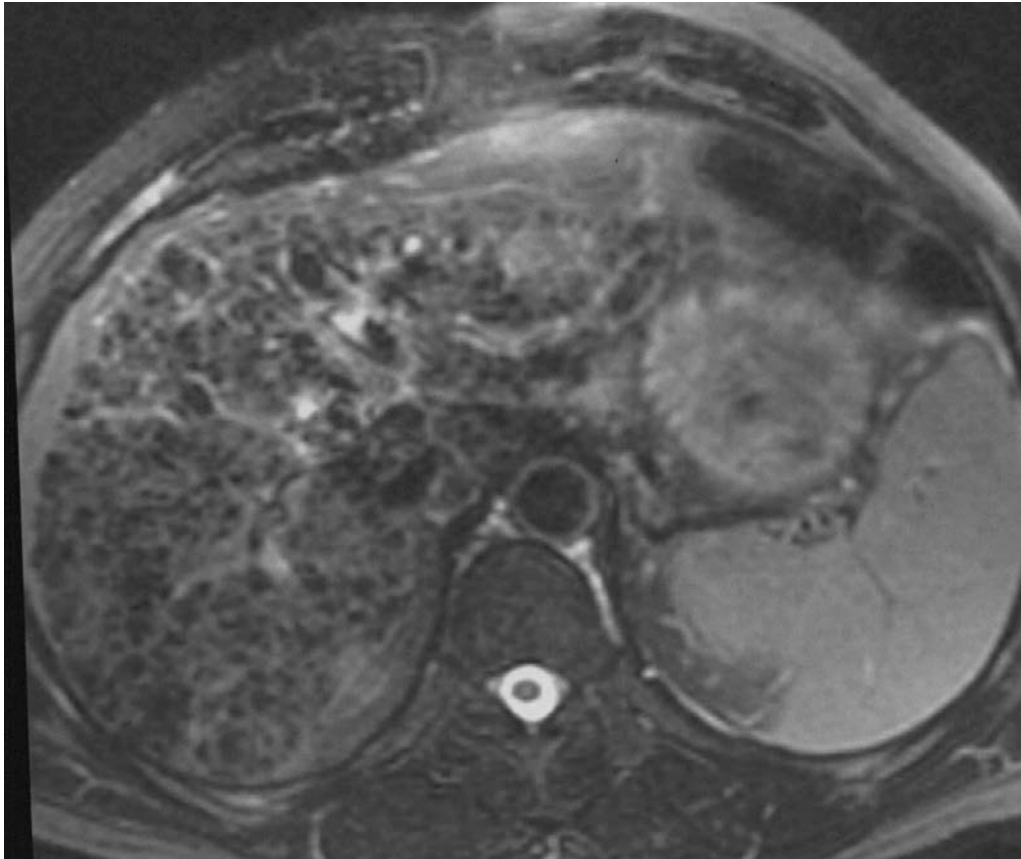
US et Cirrhose décompensée:

- Veine porte ? Ascite ?
- Hépatocarcinome ?



CT et cirrhose décompensée:

- Veine porte ?
- Hépatocarcinome ?
- Autre problème : intestin (ischémie, perforation)



IRM et cirrhose décompensée:

- Veine porte ?
- Hépatocarcinome ?

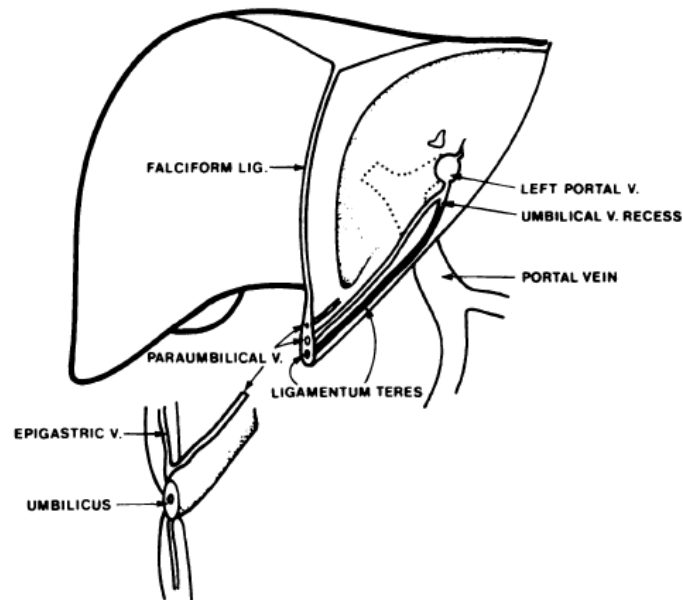


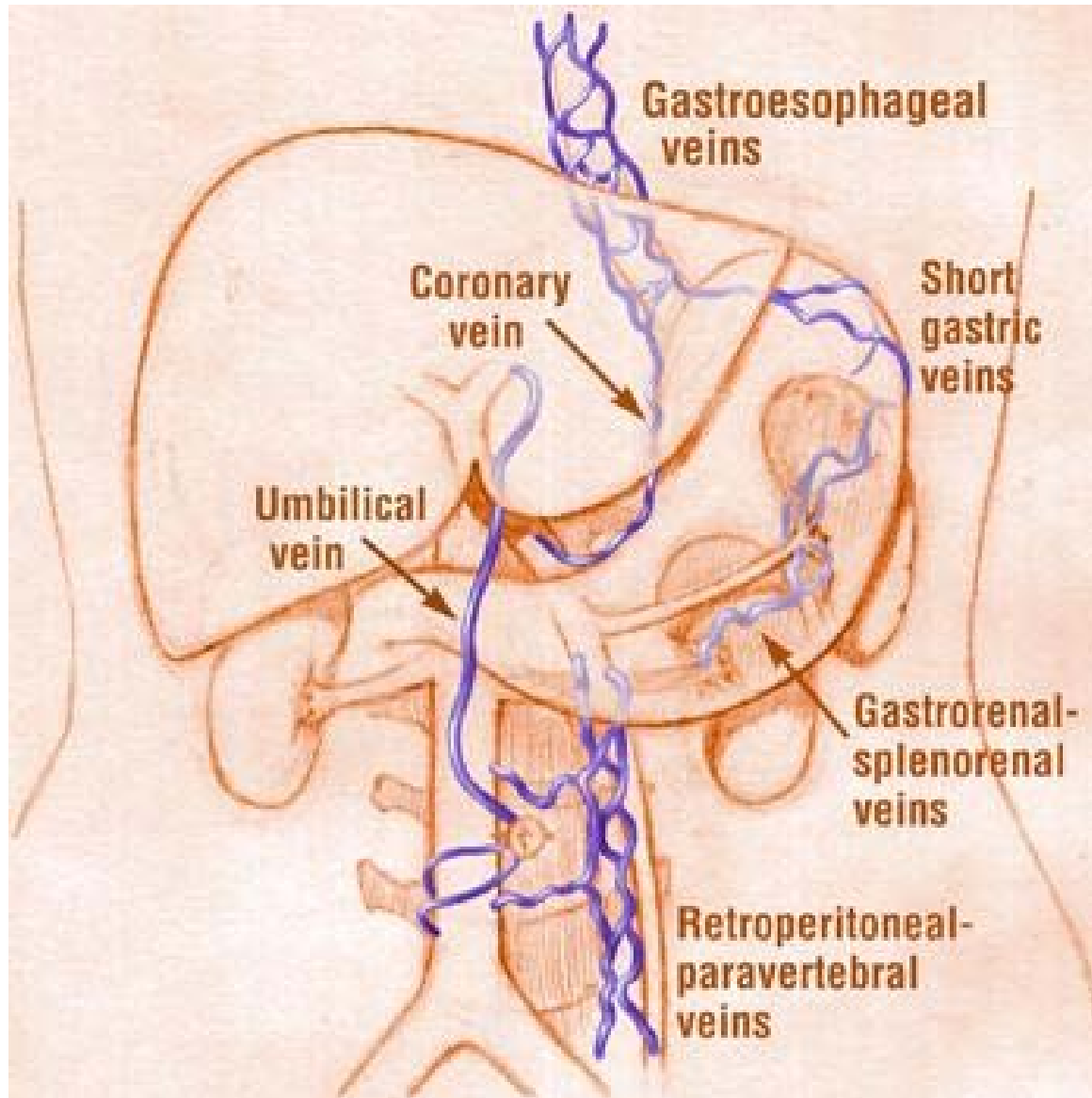
Fig. 1.—Anatomy of falciform ligament showing umbilical vein recess (Baumgarten recess) and its relation to paraumbilical vein.

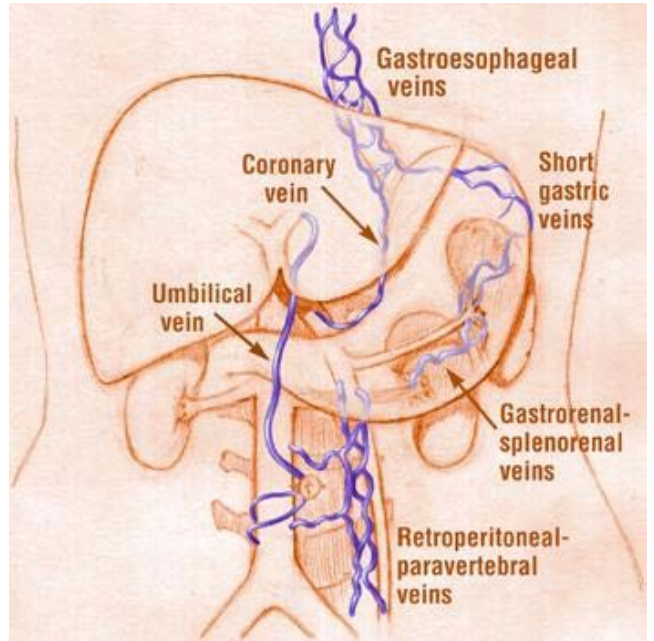
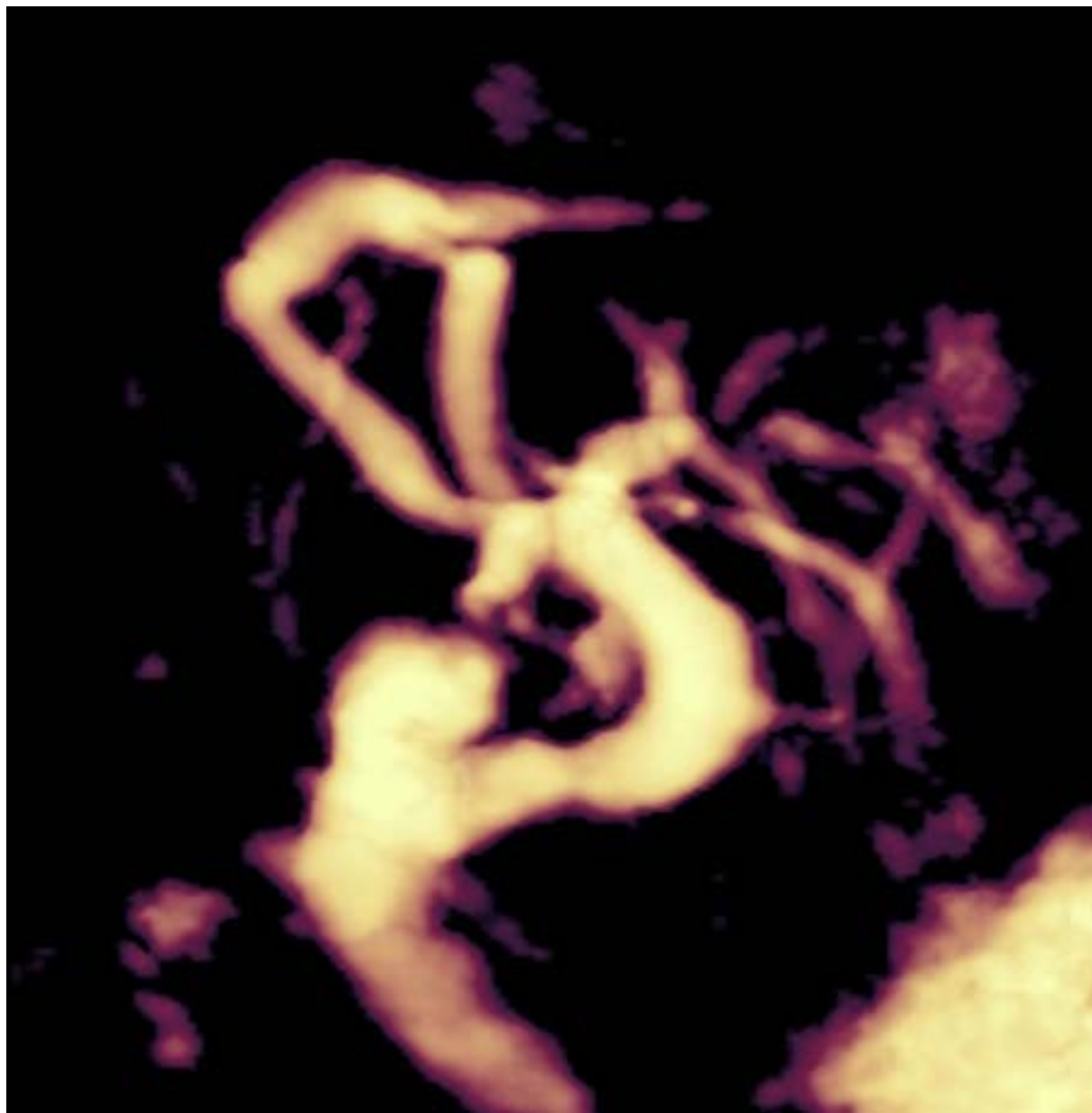
The Recanalized Umbilical Vein in Portal Hypertension: A Myth

AJR 144:549-553, March 1985
 0361-803X/85/1443-0549
 © American Roentgen Ray Society

Michel Lafortune¹
 André Constantin¹
 Guy Breton¹
 André G. Légaré¹
 Pierre Lavioie²

The demonstration of a vessel in the falciform ligament, traditionally presumed to be a reopened umbilical vein, is an important sonographic sign of portal hypertension. This vessel was sought in 200 umbilicoportographies (all portal hypertensive) and in 41 autopsy-dissected falciform ligaments (34 normal and seven cirrhotic). The normal falciform ligament contained one to three tiny collapsed paraumbilical veins. In cirrhotics, the number and caliber of paraumbilical veins increased. A reopened umbilical vein was never found. The authors conclude that the umbilical vein does not recanalize in portal hypertension. The vessel involved is actually an enlarged paraumbilical vein.





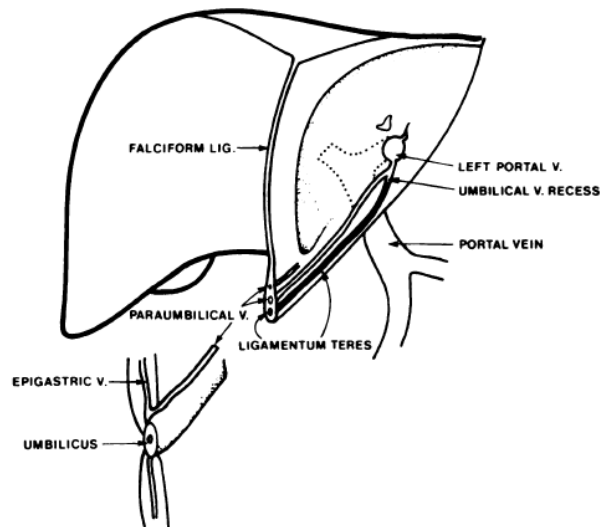
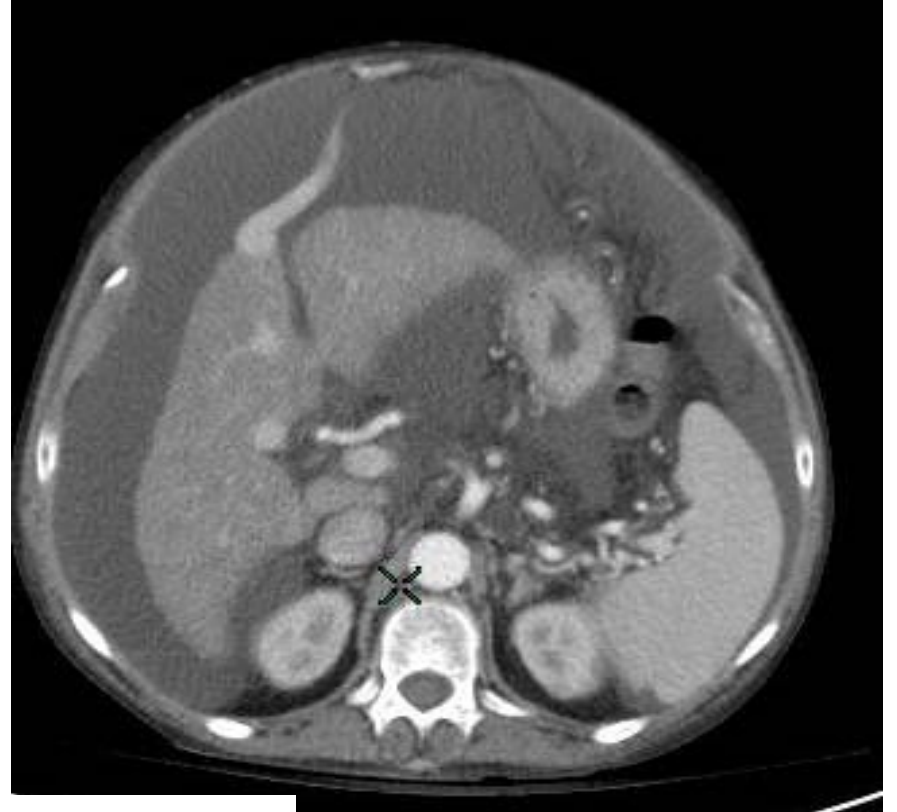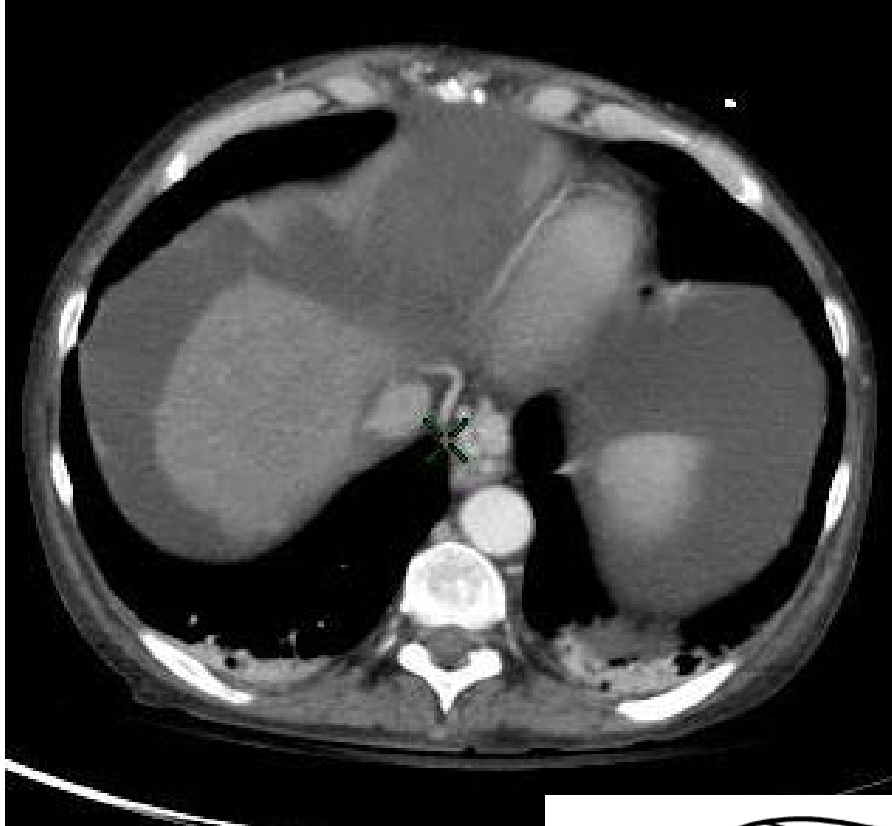

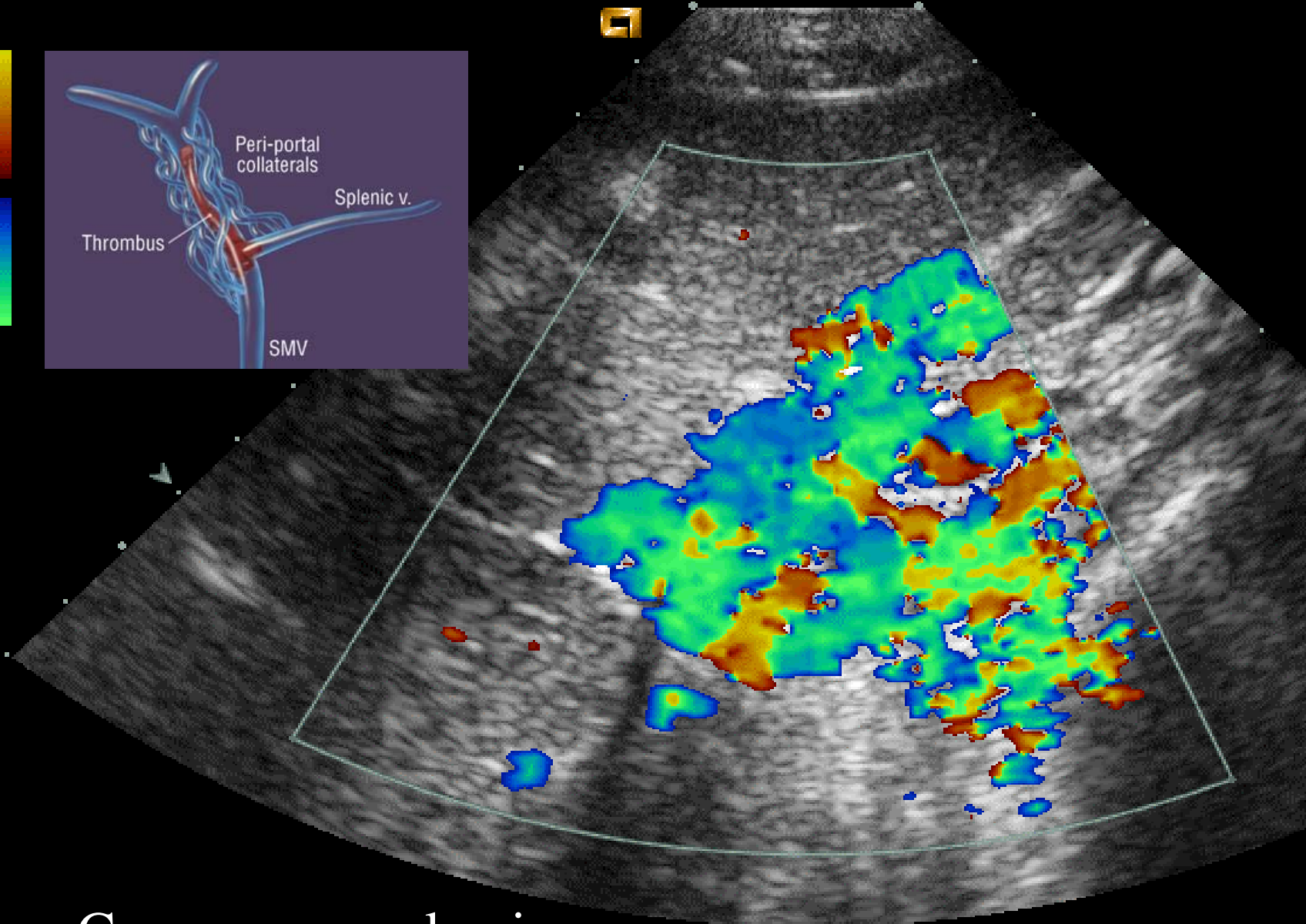
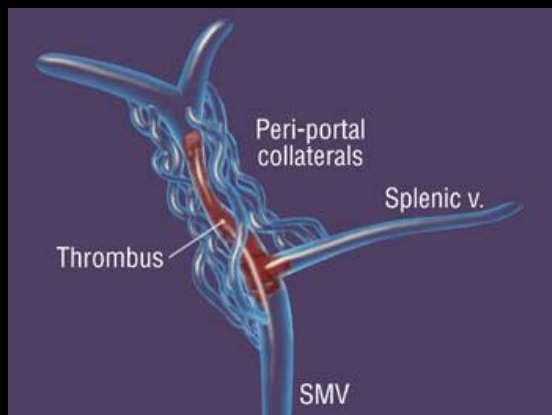


Fig. 1.—Anatomy of falciform ligament showing umbilical vein recess (Baumgarten recess) and its relation to paraumbilical vein.

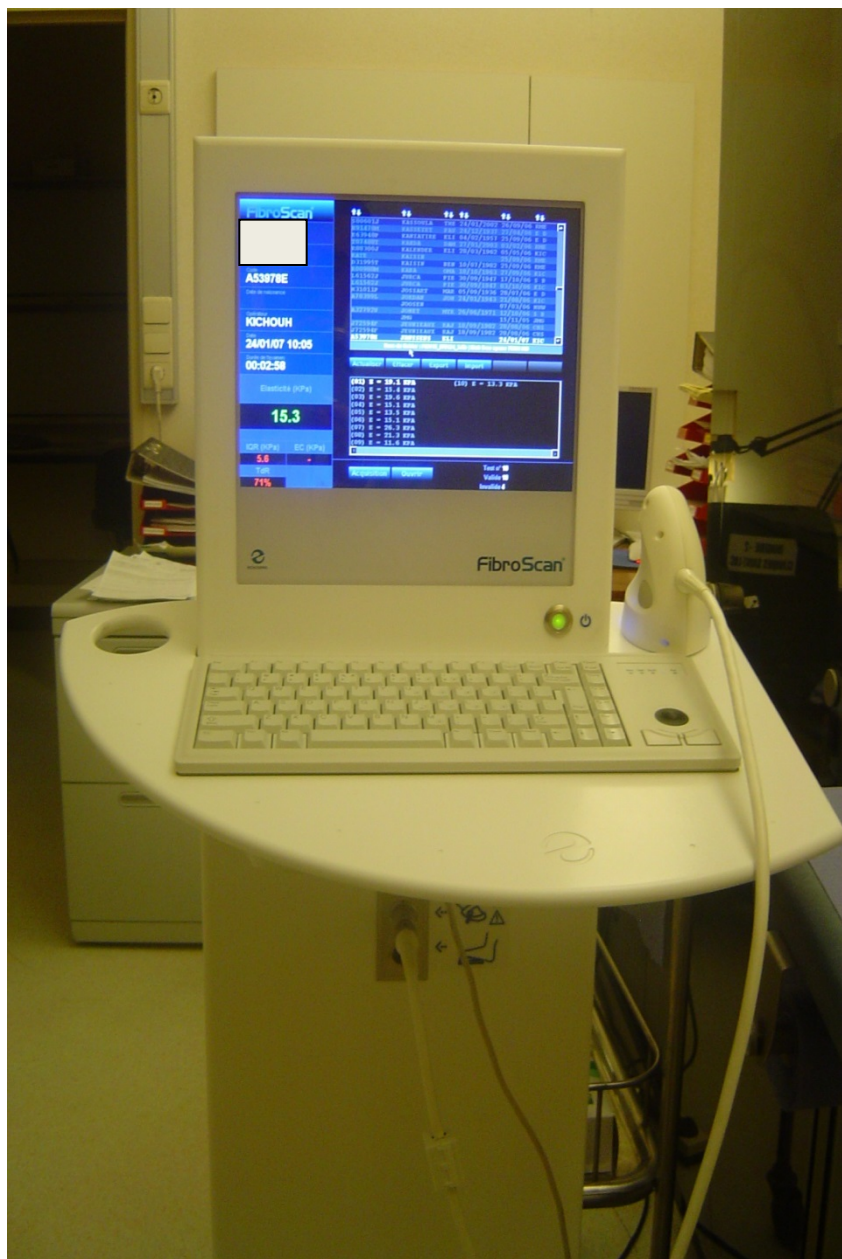.12




.12



Cavernome « classique »





Le Fibroscan® est un dispositif médical d'aide au diagnostic. L'examen doit être réalisé par un opérateur certifié. Les résultats doivent être interprétés par un médecin spécialiste du foie en fonction du contexte clinique de la maladie et des données issues de la littérature scientifique.

STOP

TIS0.9 MI 1.3

C5-1
65Hz
RP

2D
61%
Dyn R 55
P Med
Gen

FlastQ

✦ Liver EQI 9

EQI Avg 12.2 kPa
EQI Med 12.0 kPa
EQI IQR/Med 16 %

✧ Liver EQI 10

EQI Avg 12.2 kPa
EQI Med 12.0 kPa
EQI IQR/Med 12 %


◇ Liver EQI 1

EQI Avg 11.6 kPa
EQI Med 11.6 kPa
EQI IQR/Med 17 %

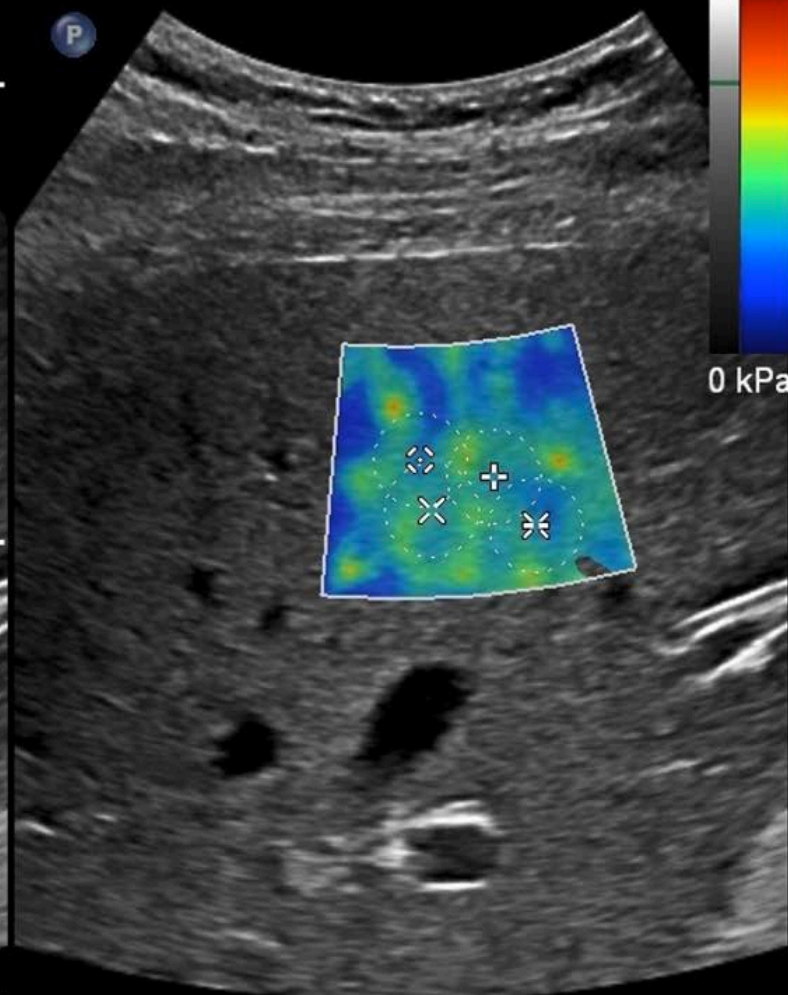
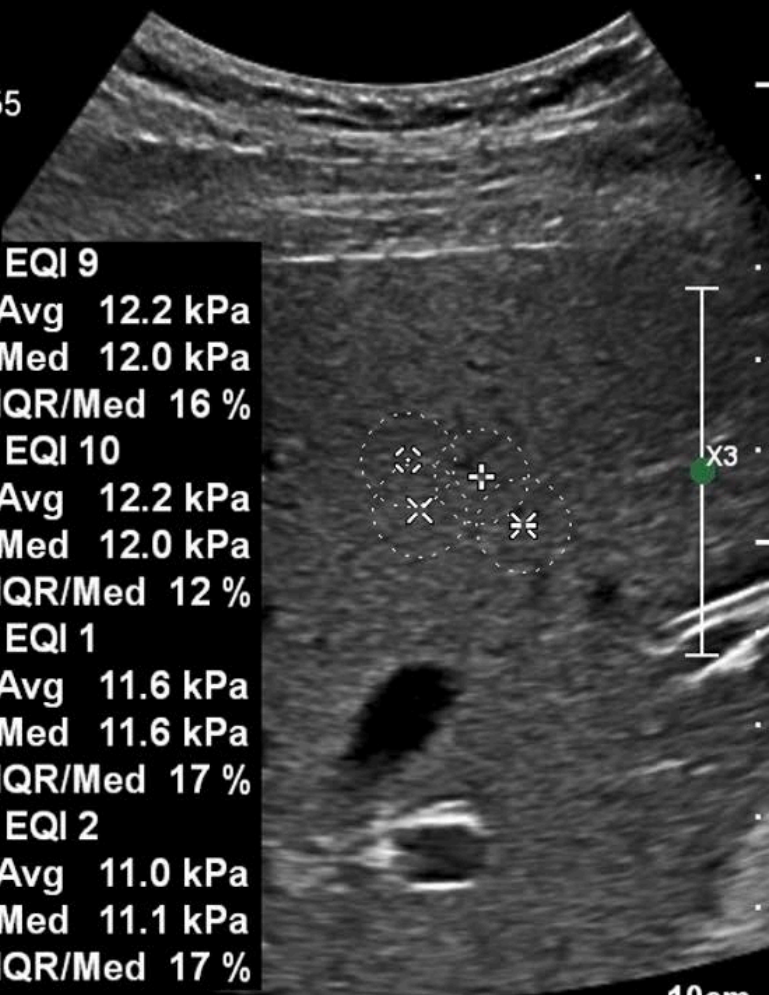
⊗ Liver EQI 2

EQI Avg 11.0 kPa
EQI Med 11.1 kPa
EQI IQR/Med 17 %

M3 M2
30 kPa



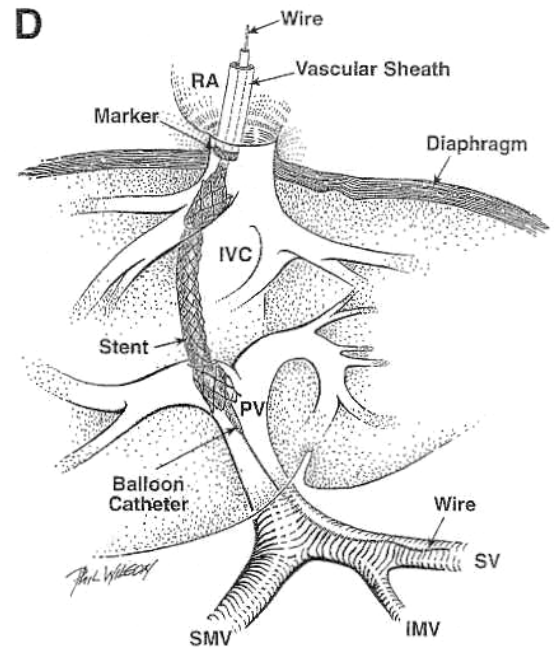
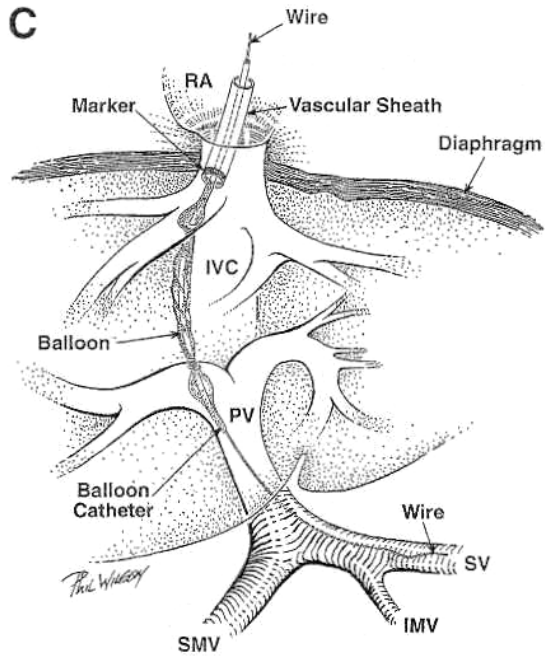
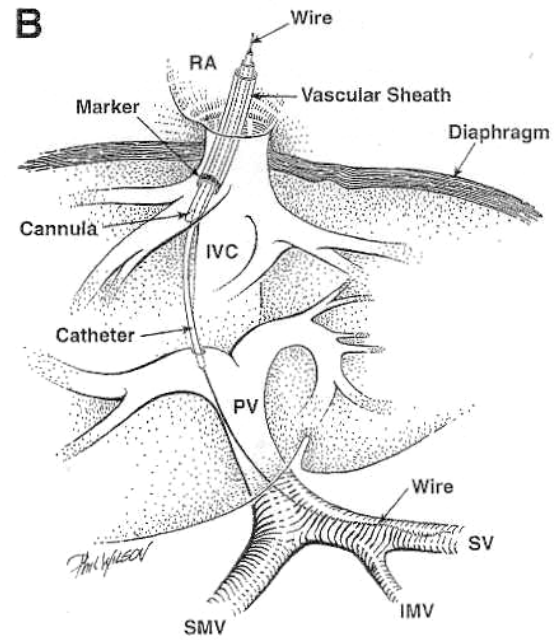
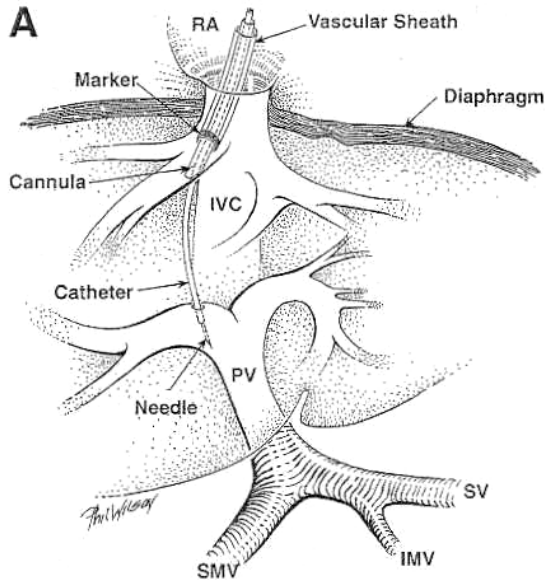
0 kPa

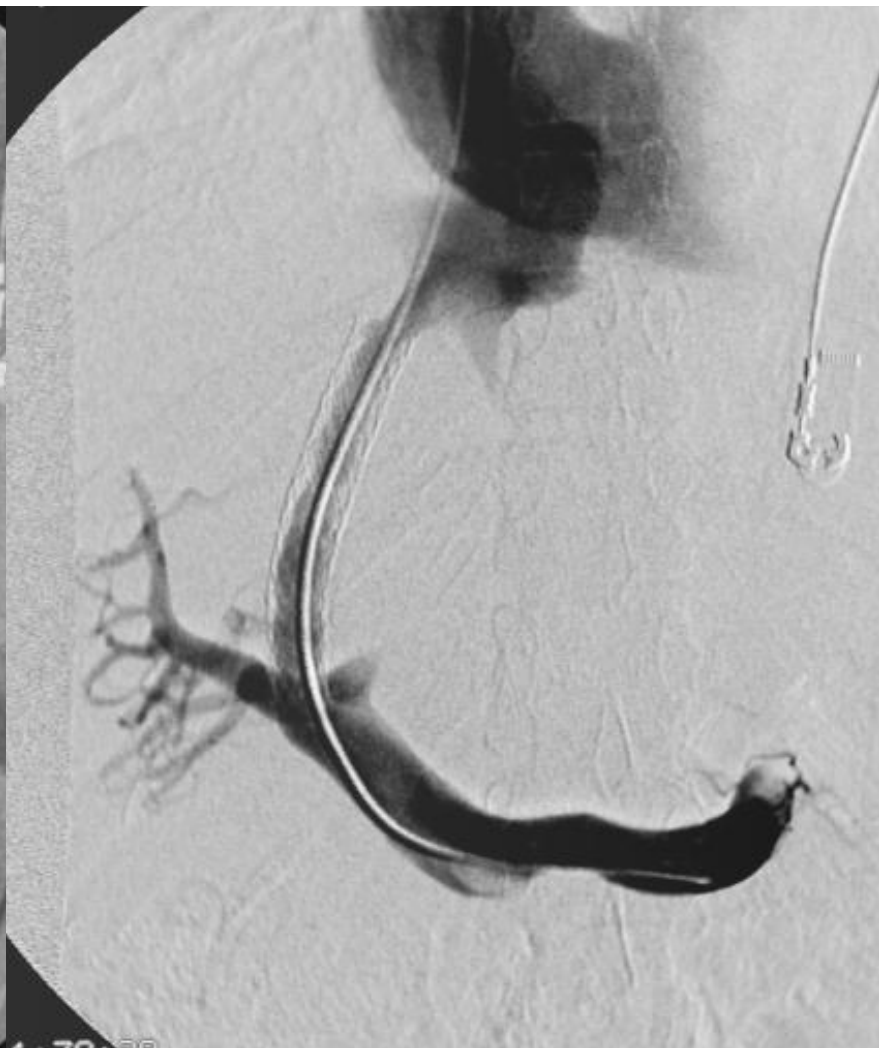
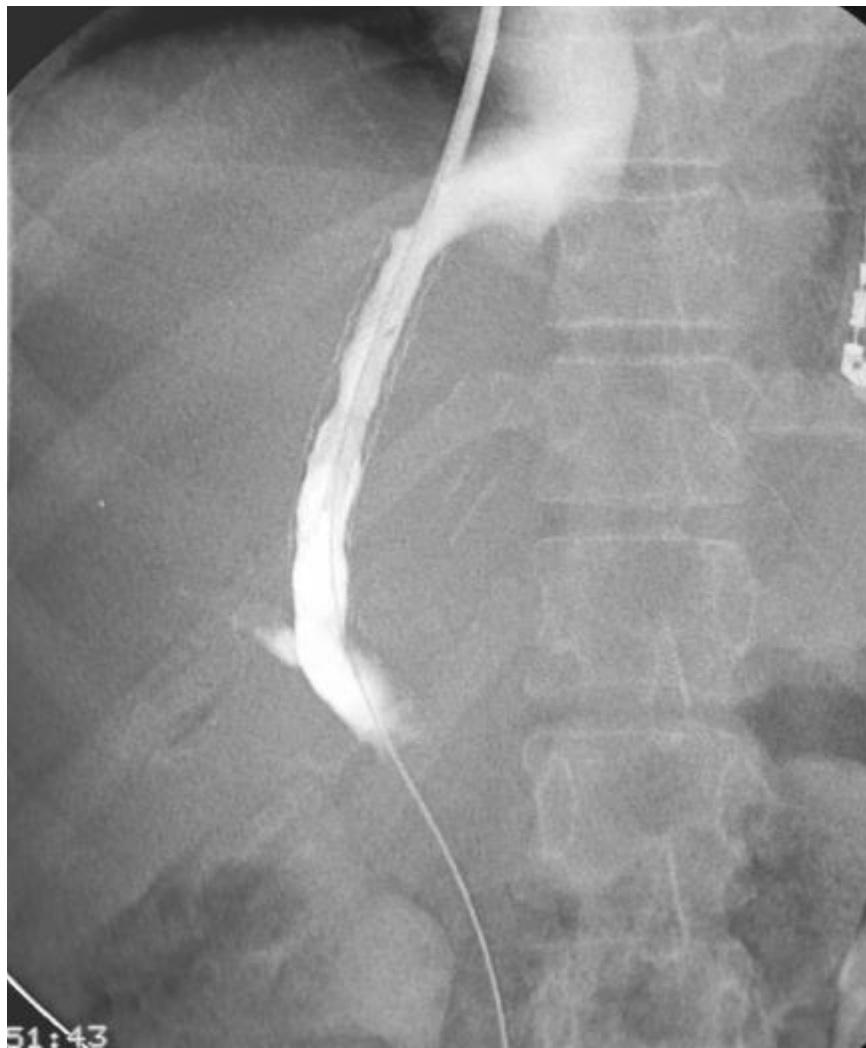
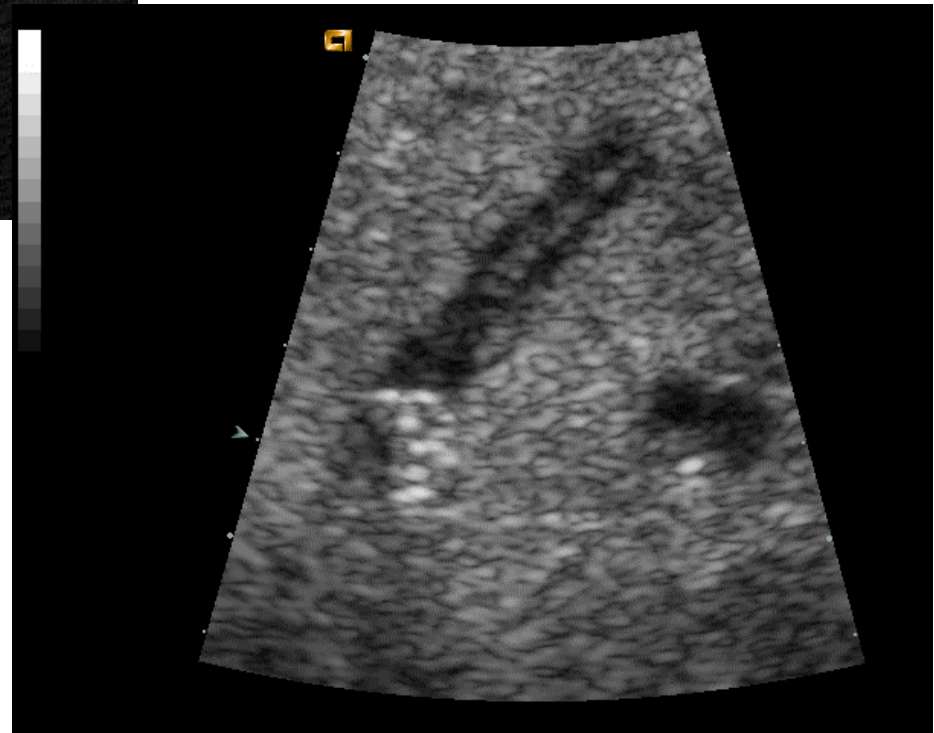
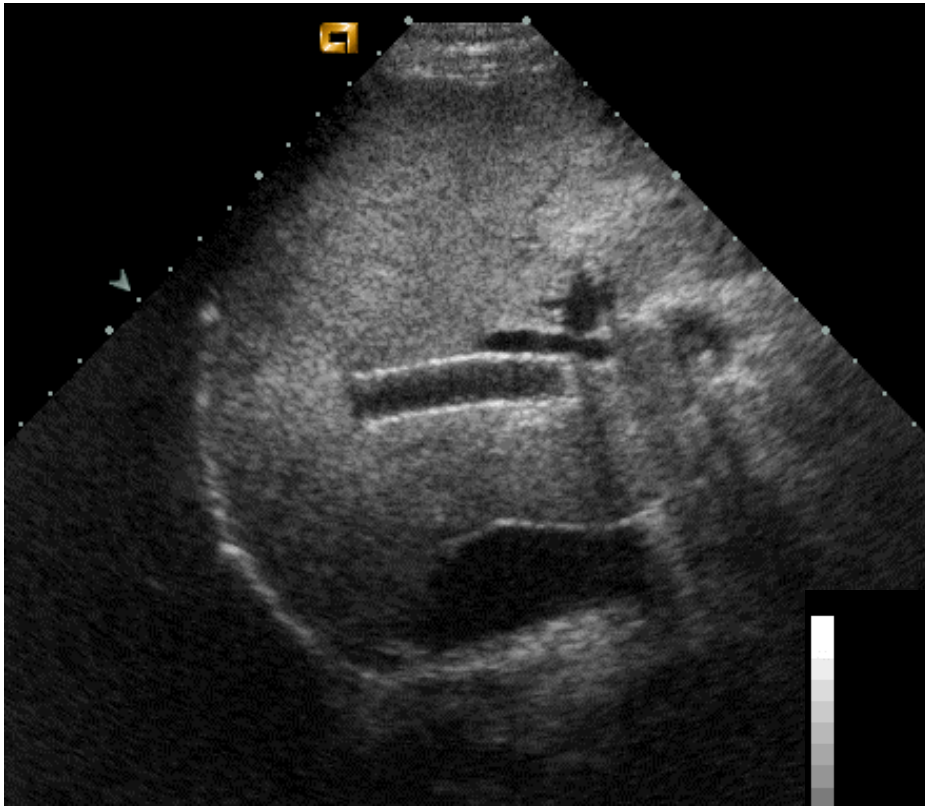
10cm-

Shunts porto-caves intra-hépatiques par voie transjugulaire (TIPS)

- Indications:
 - Ascites médico-résistantes
 - Hémorragies par rupture de VO récidivantes
 - Budd-Chiari









.64

