



Université catholique de Louvain

Secteur des Sciences de la Santé

Secteur Endocrinologie MED 22
WMEDI2225

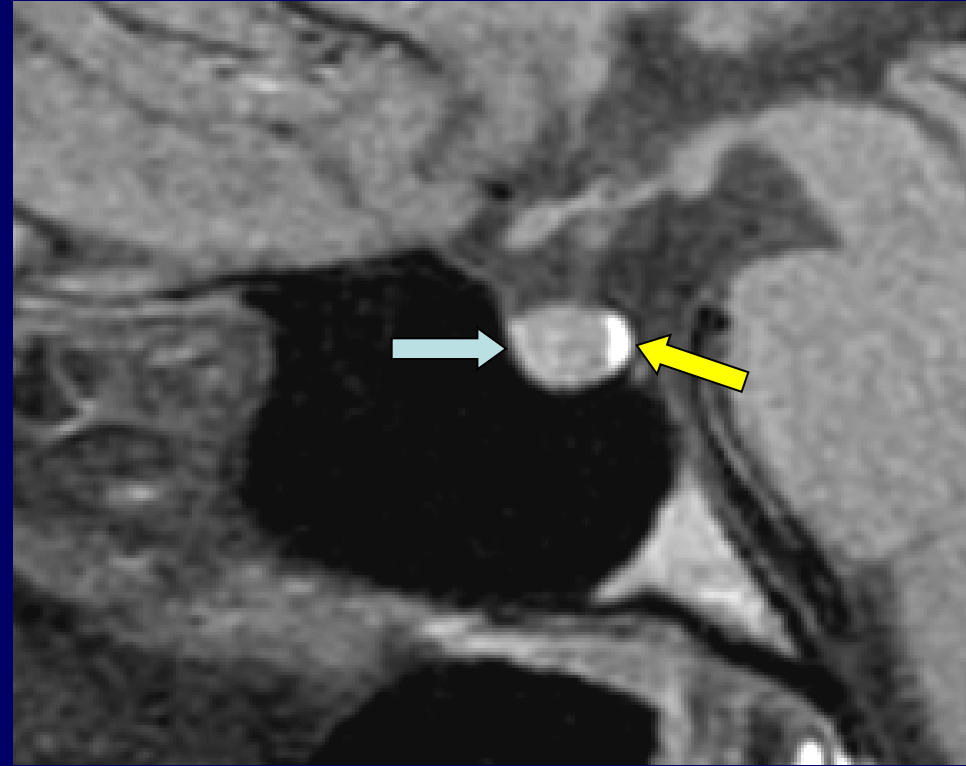
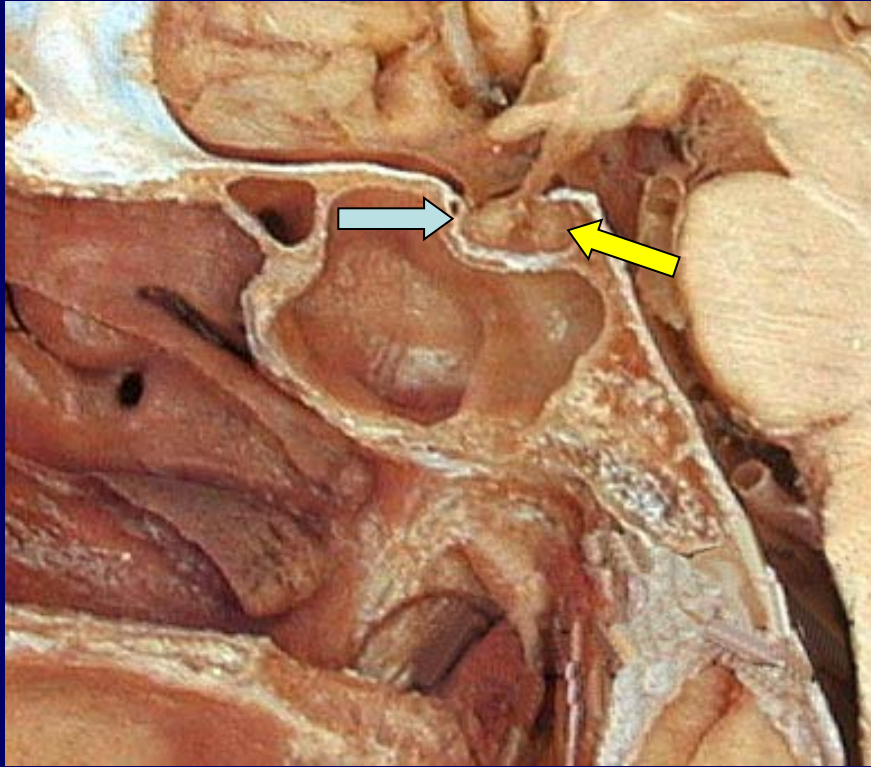
Année académique 2019-2020

Sémiologie radiologique de la pathologie hypophysaire

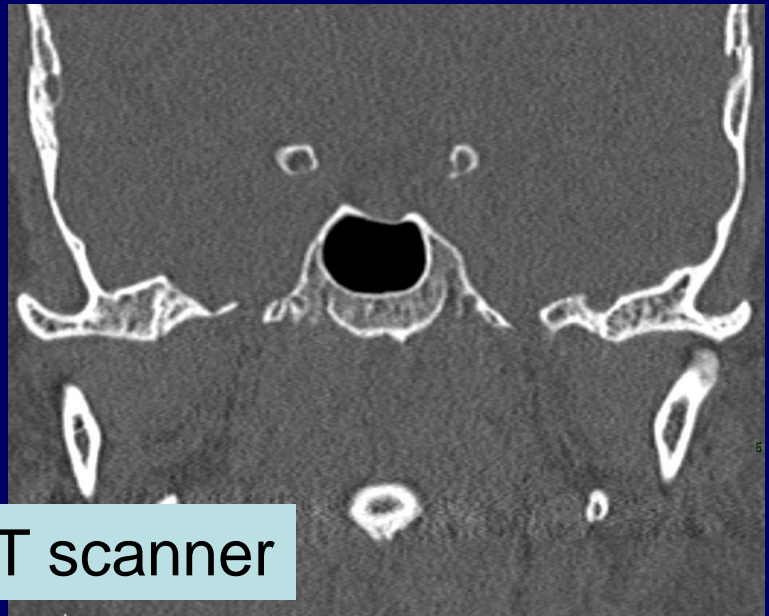
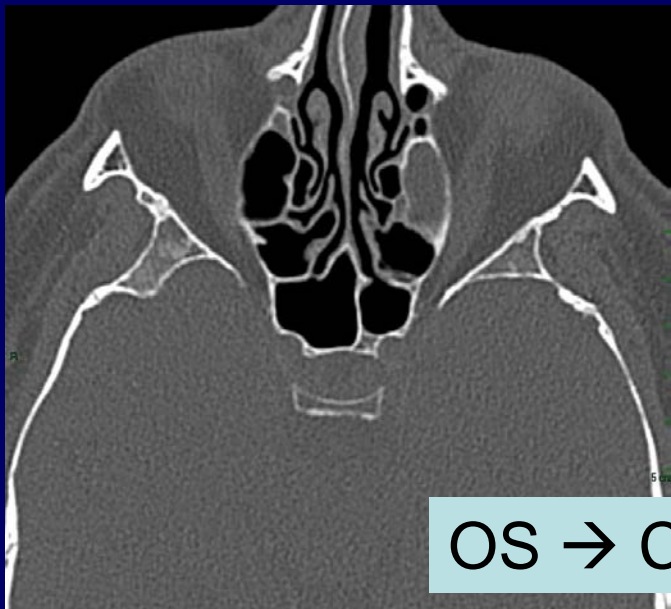
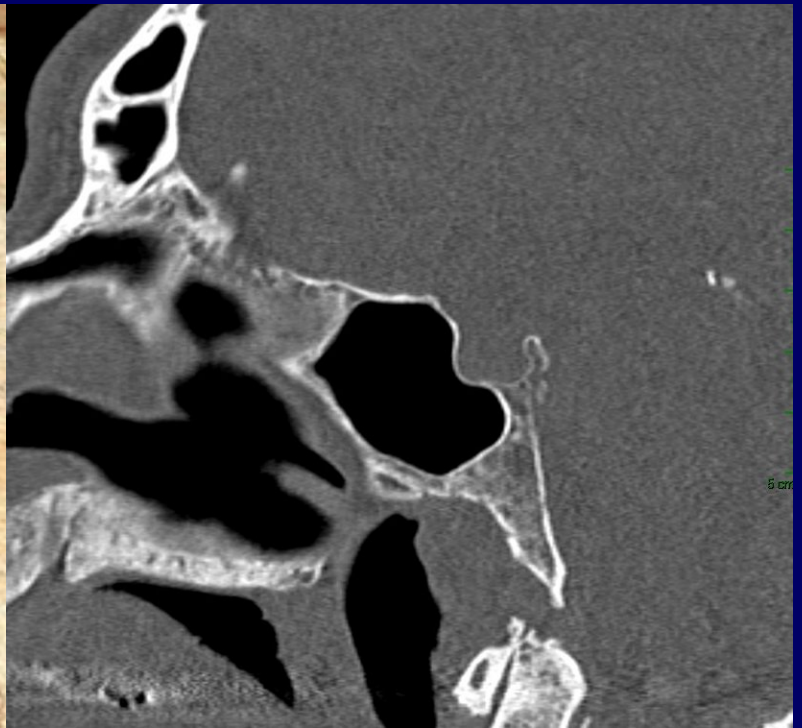
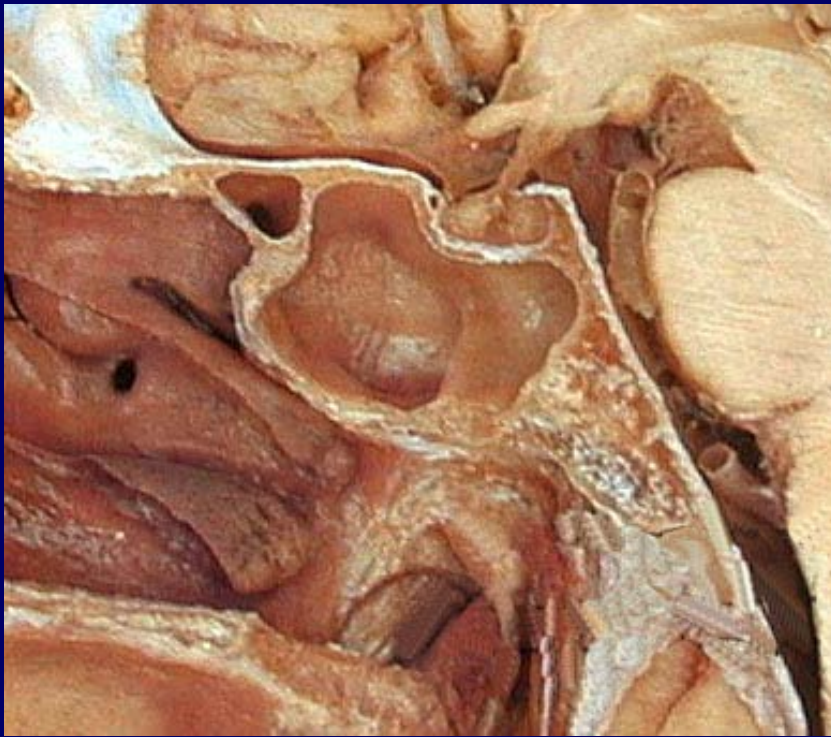Dr. Thierry DUPREZ
Service de Radiologie
Professeur Clinique UCL
Chef de Clinique UCL-St-Luc

20 mars 2020

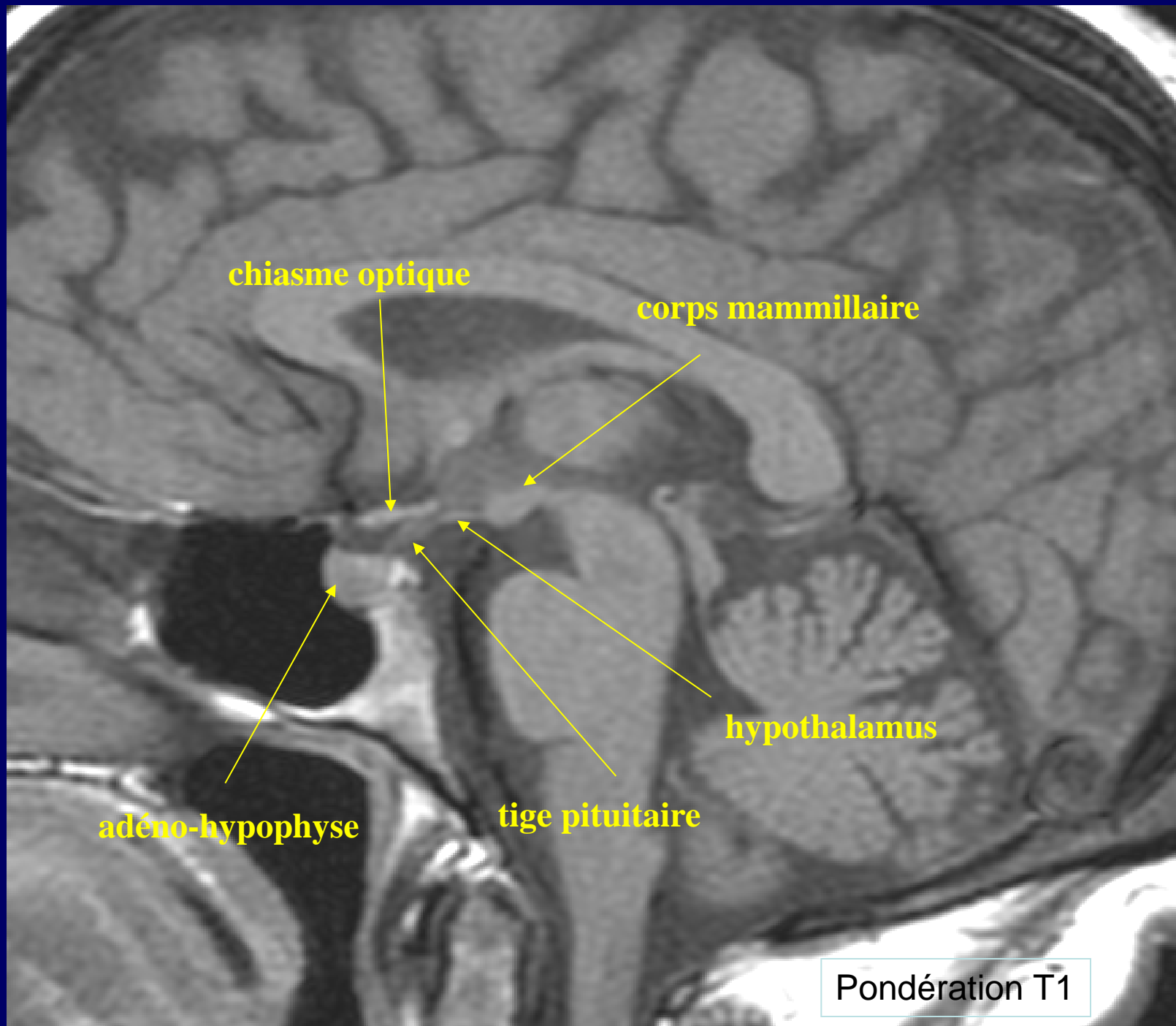
Semaine 7 – 1heure (12h-13h)



Parenchyme → IRM



OS → CT scanner



chiasme optique

corps mammillaire

adéno-hypophyse

tige pituitaire

hypothalamus

Pondération T1

Pondération T2

carotide interne

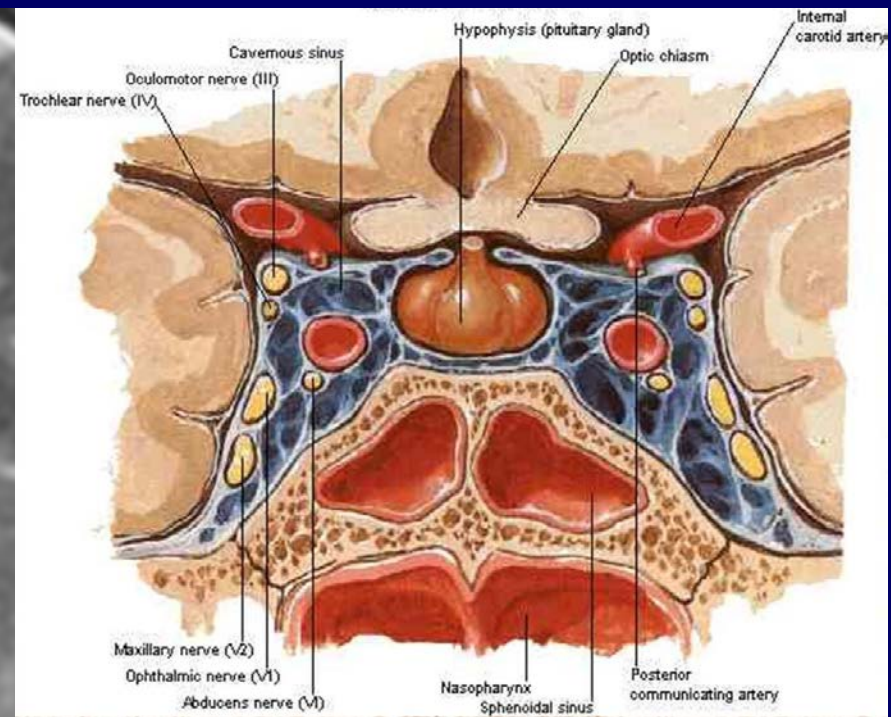
chiasma optique

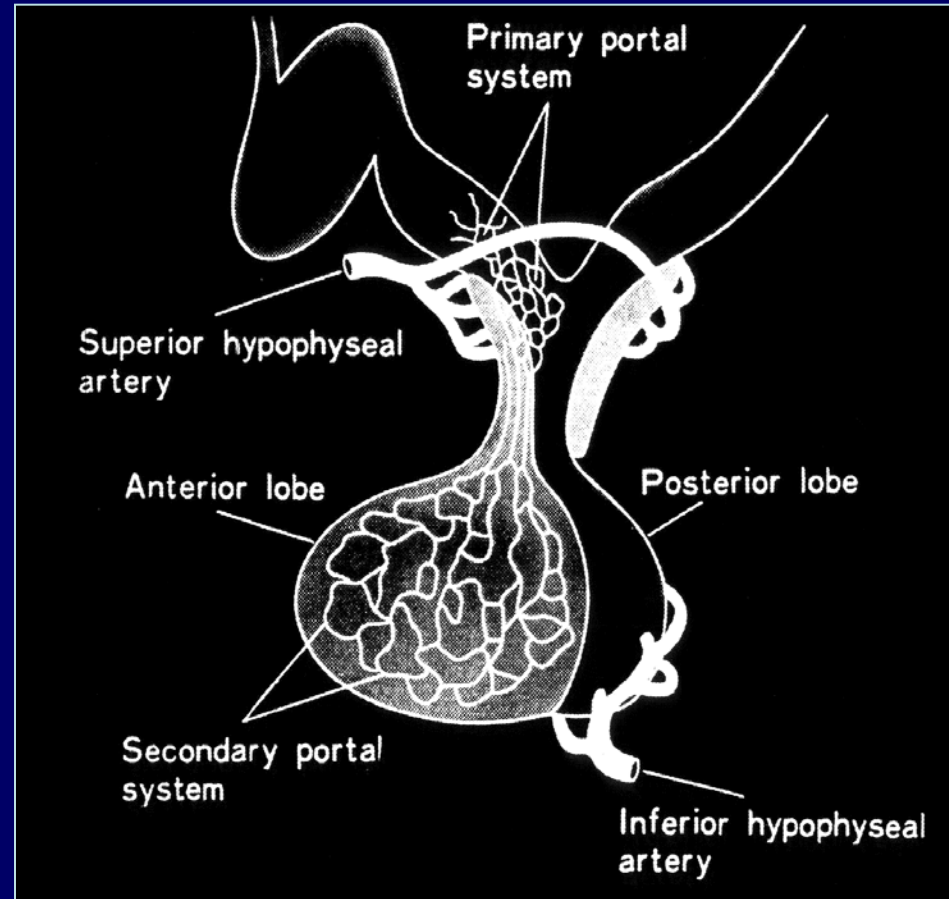
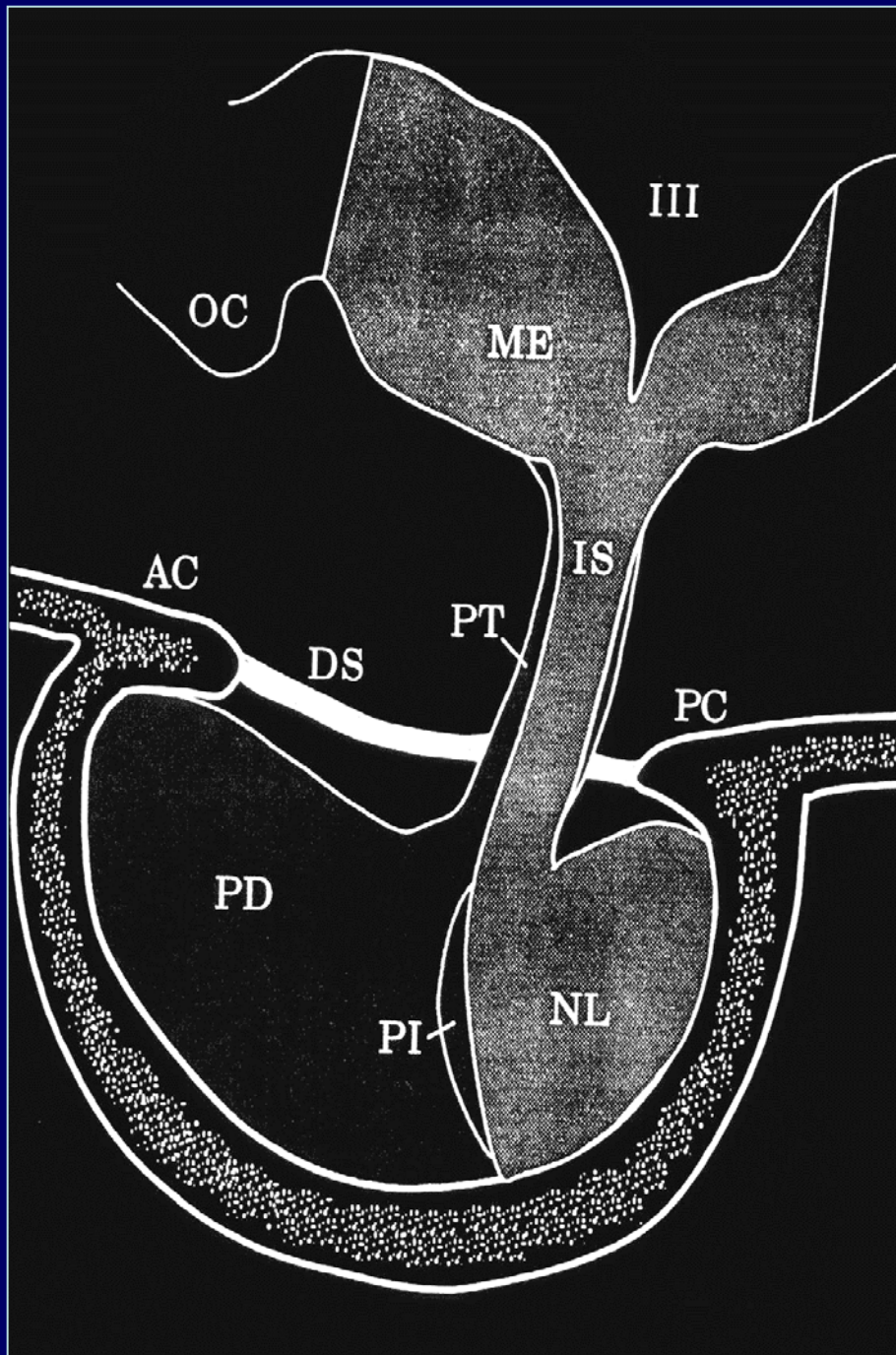
tige pituitaire

hypophyse

Sinus caverneux :

- Carotide
- Plexus veineux
- III
- IV
- V1
- V2
- VI

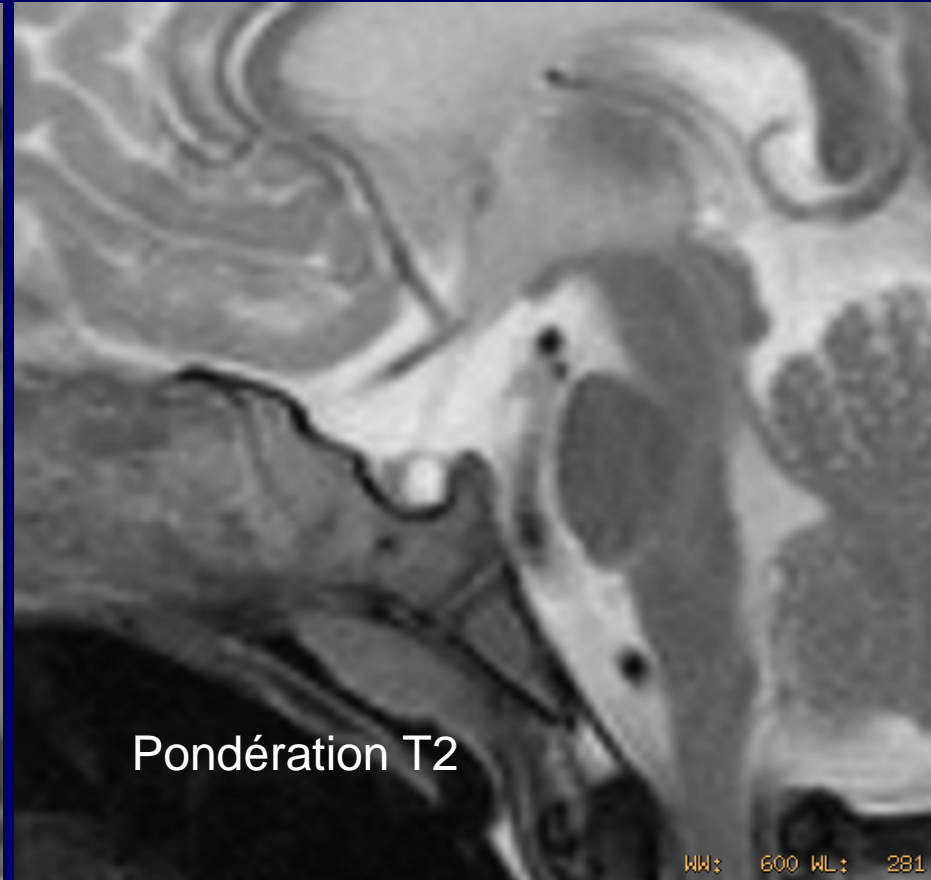
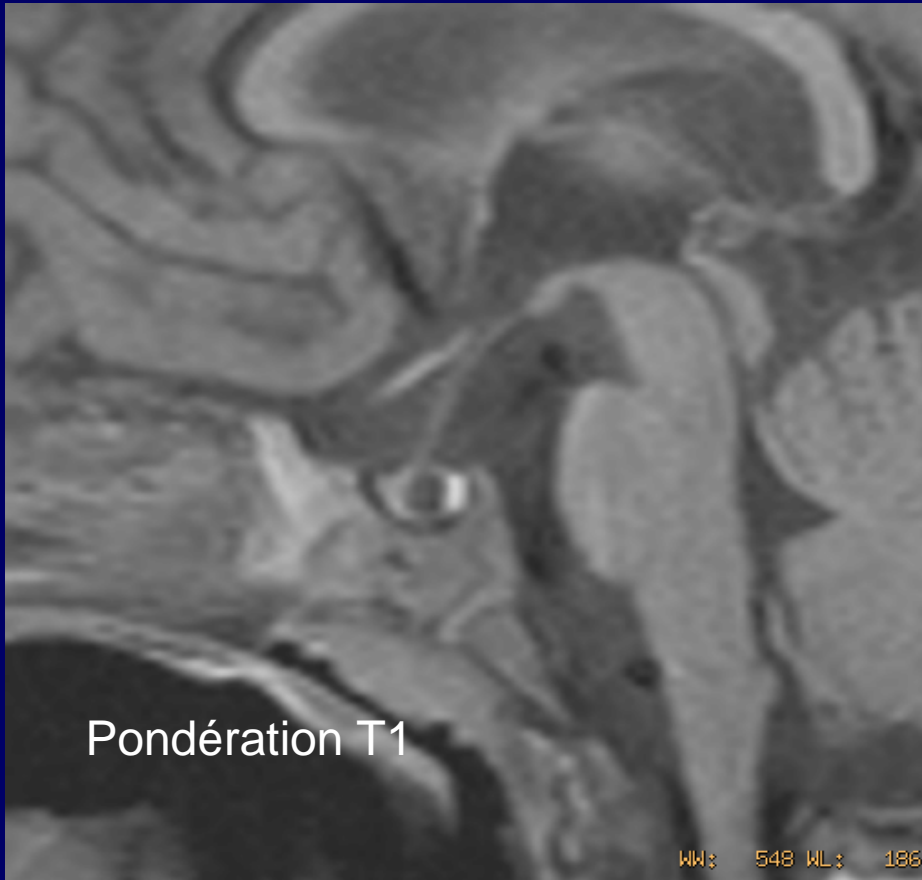



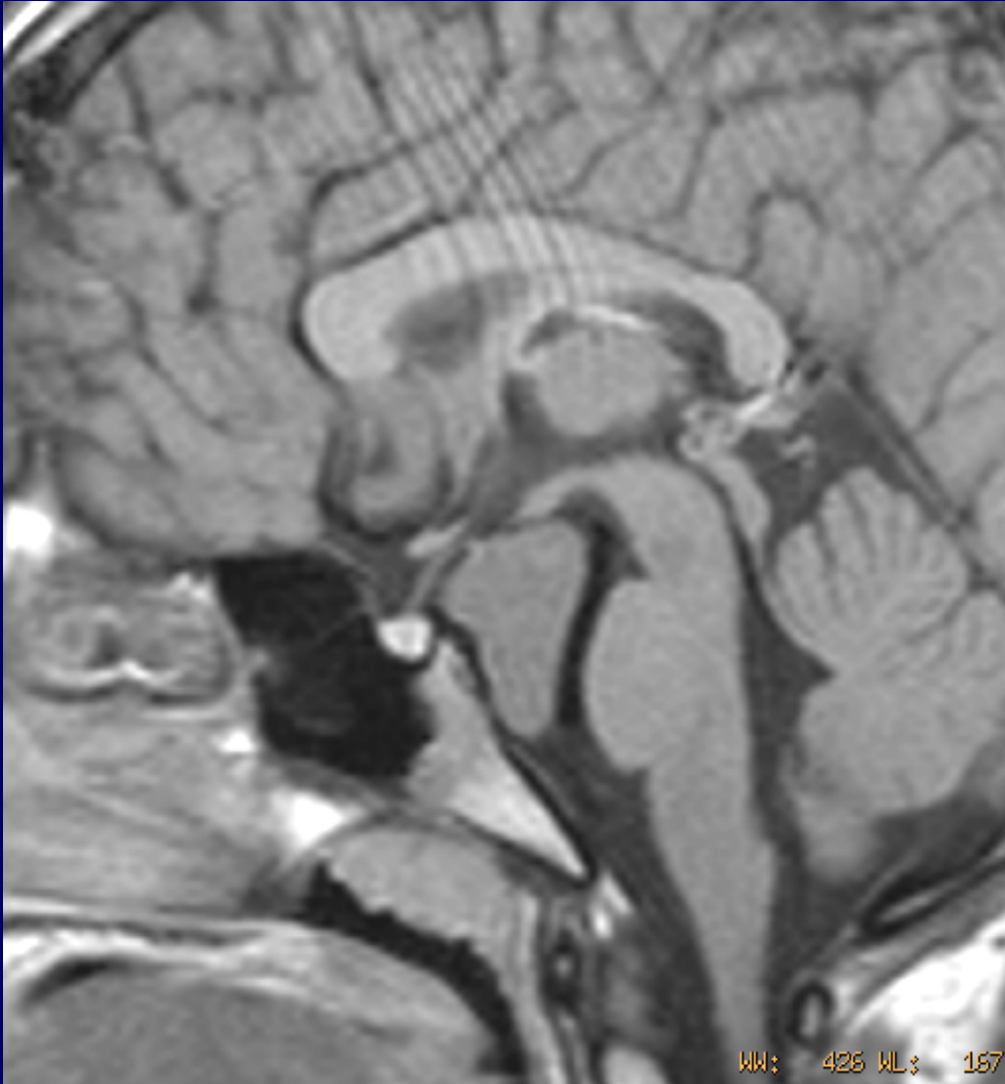
Pathologies (particularismes) développementales

- Kyste de la *Pars intermedia*
- Hamartome du *Tuber cinereum*
- Nanisme hypophysaire (*pituitary dwarfism*)

Kyste de la *pars intermedia*



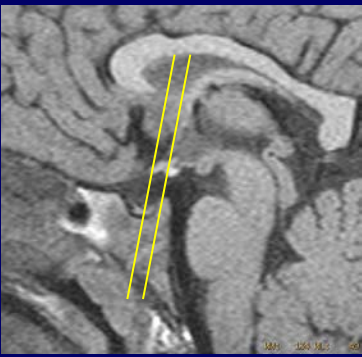
Hamartome du *tuber cinereum* hamatome hypothalamique



= ectopie *dysembryoplasique*
(non polymitotique)

- * puberté précoce
- * E. partielle complexe
(crises gélastiques)

Nanisme hypophysaire (‘pituitary dwarfism’)



Pondération T1

plan de coupe ‘antérieur’

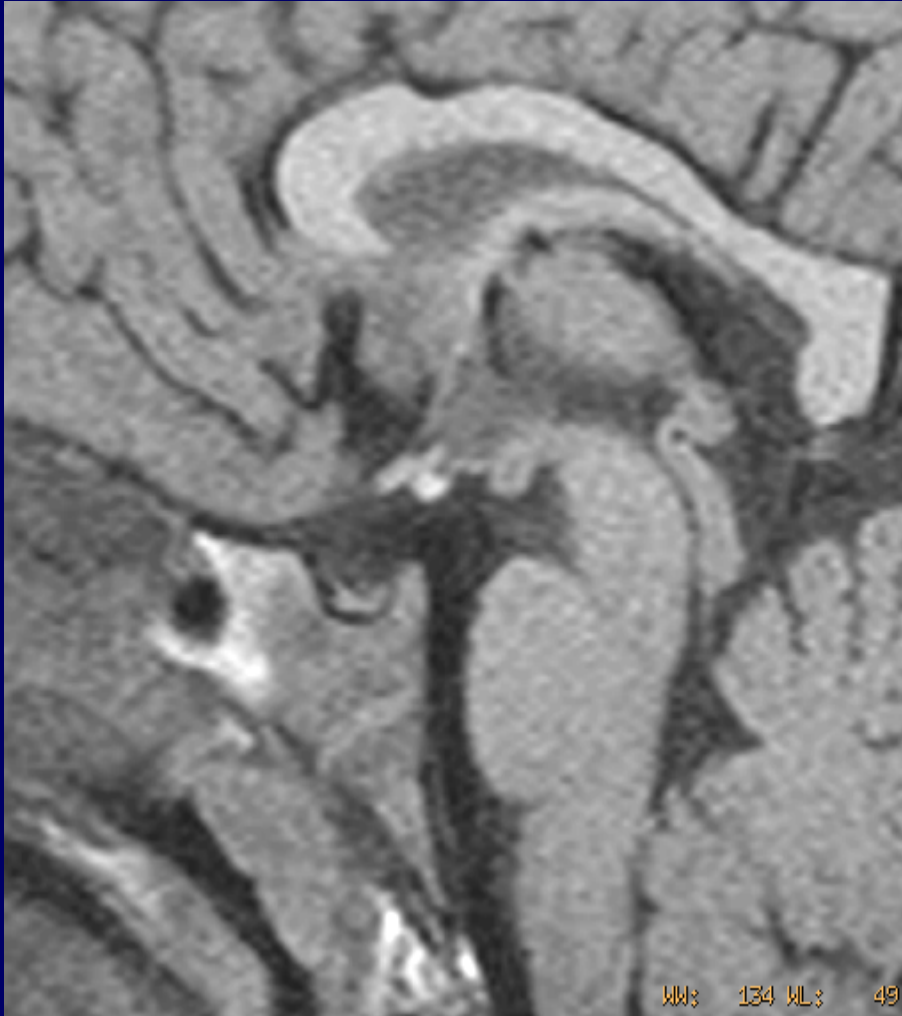WM: 188 WL: 53

Pondération T1

plan de coupe ‘postérieur’

WM: 200 WL: 53

Nanisme hypophysaire



post-hypophyse ectopique
(‘bright spot’)

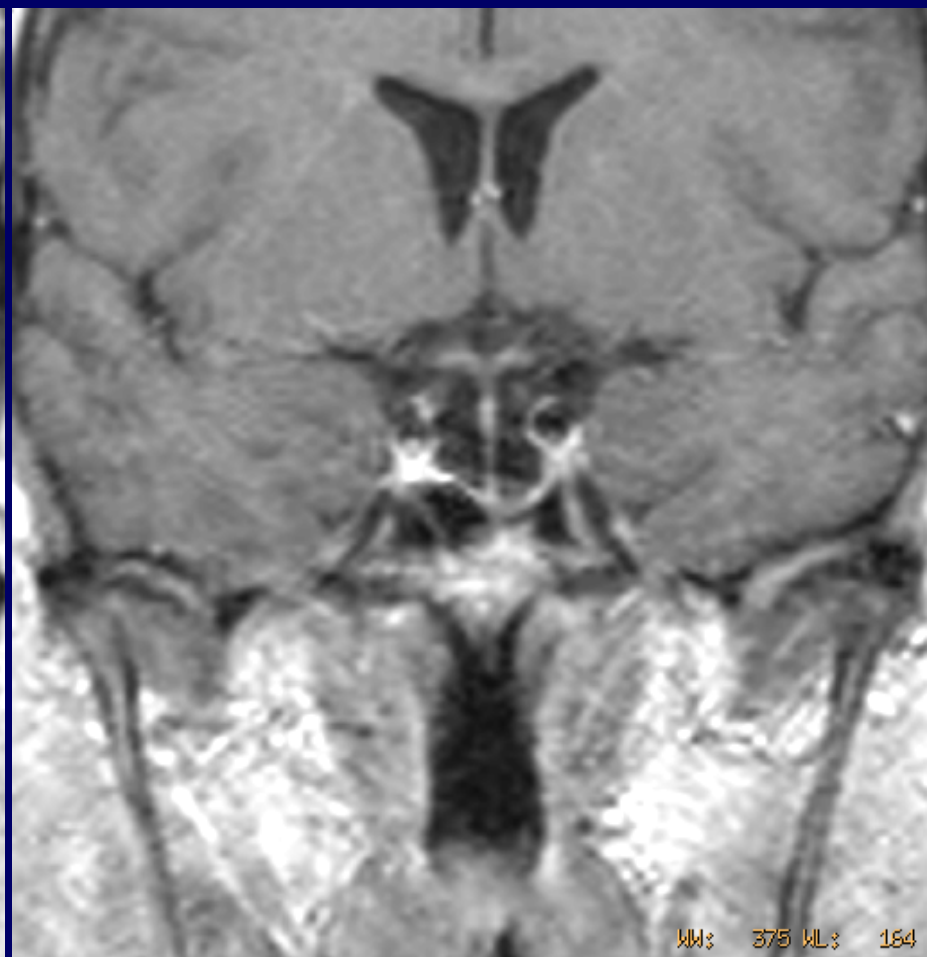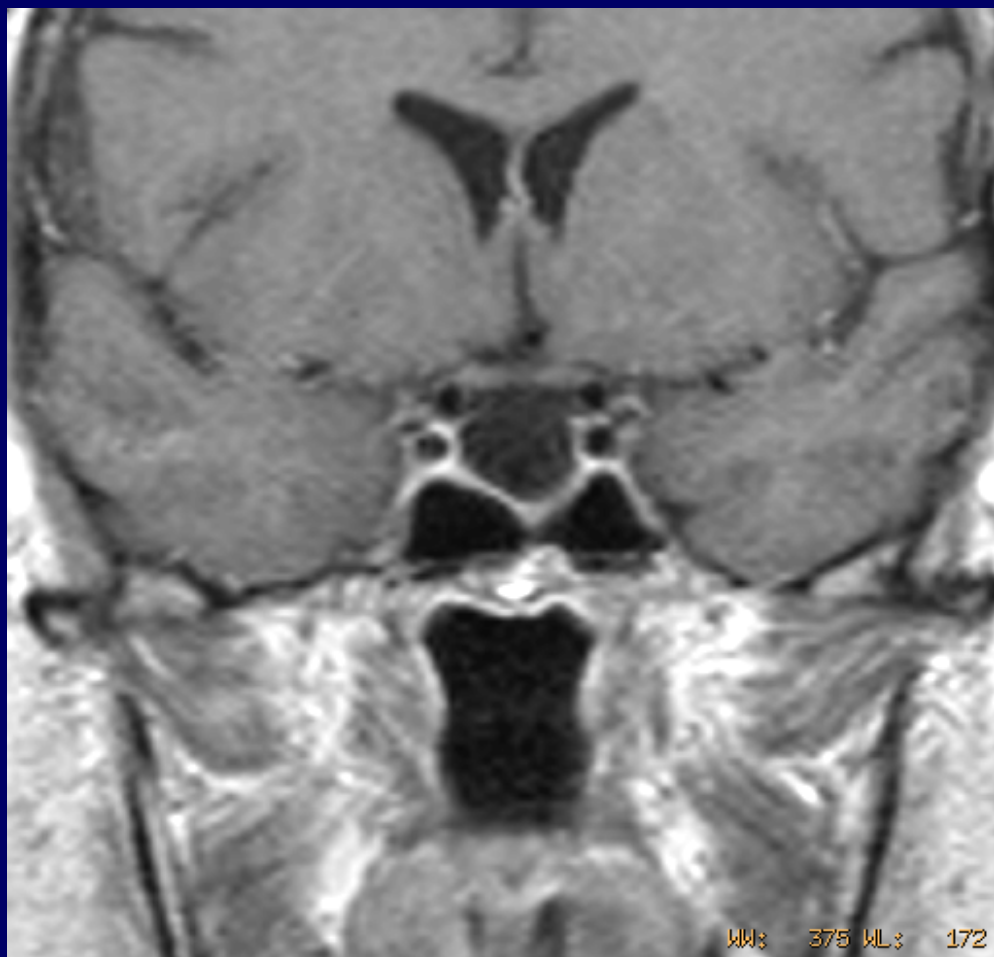absence de tige pituitaire

hypoplasie de l’adéno-hypophyse

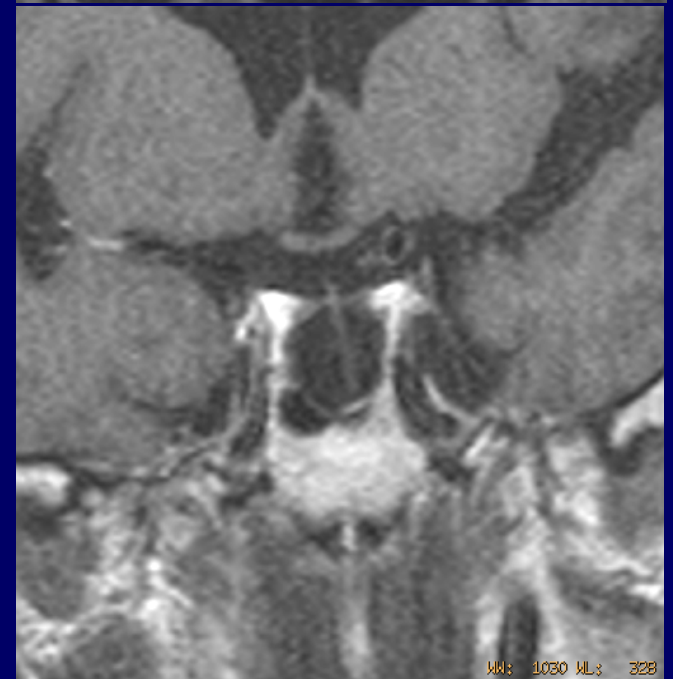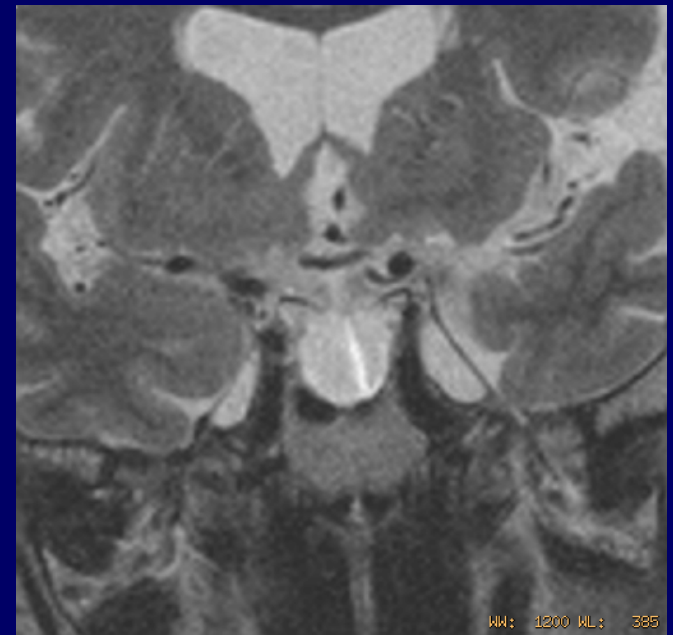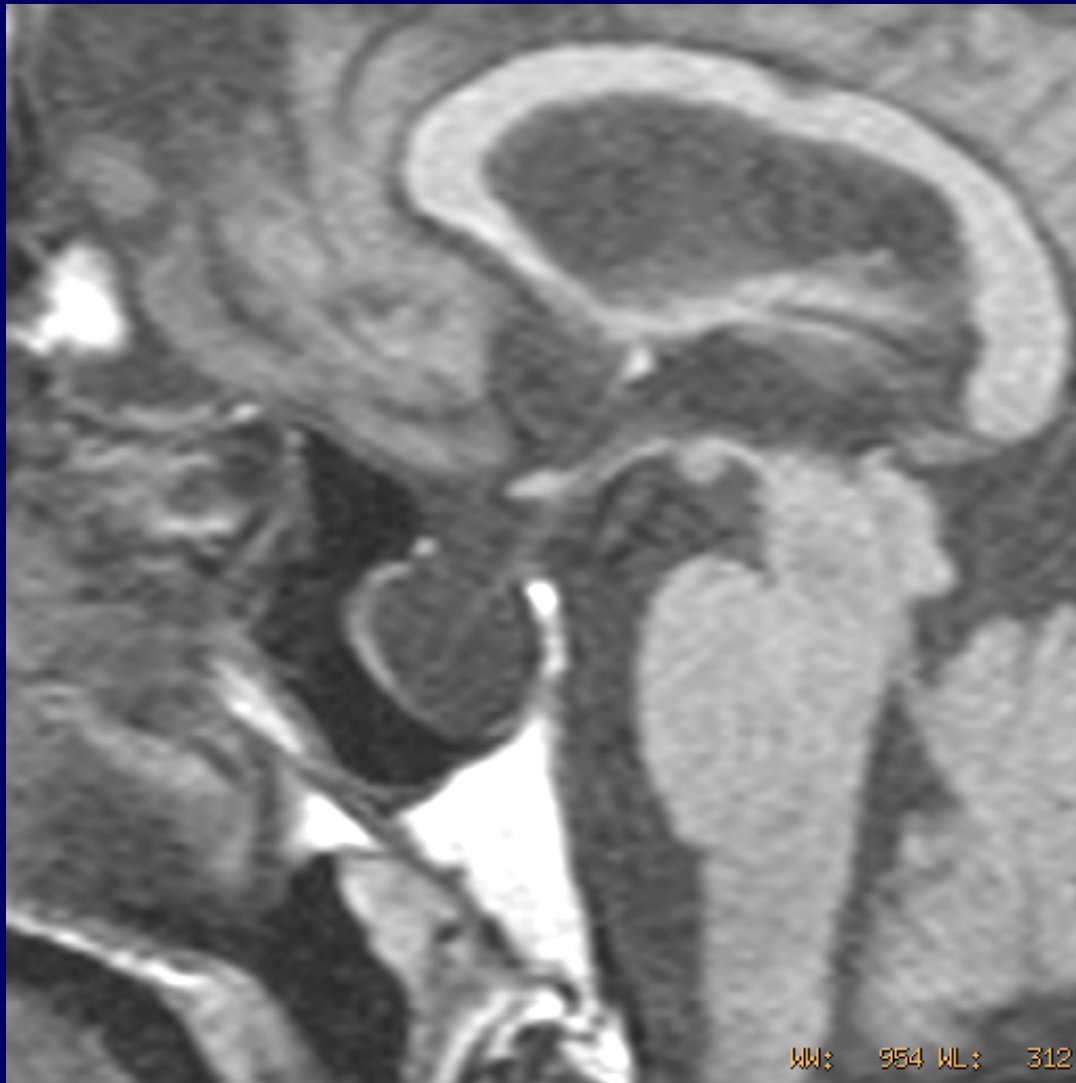Pathologies acquises non parenchymateuses

- selle turcique 'vide' non expansive
- selle turcique 'vide' expansive
- procidence carotidienne

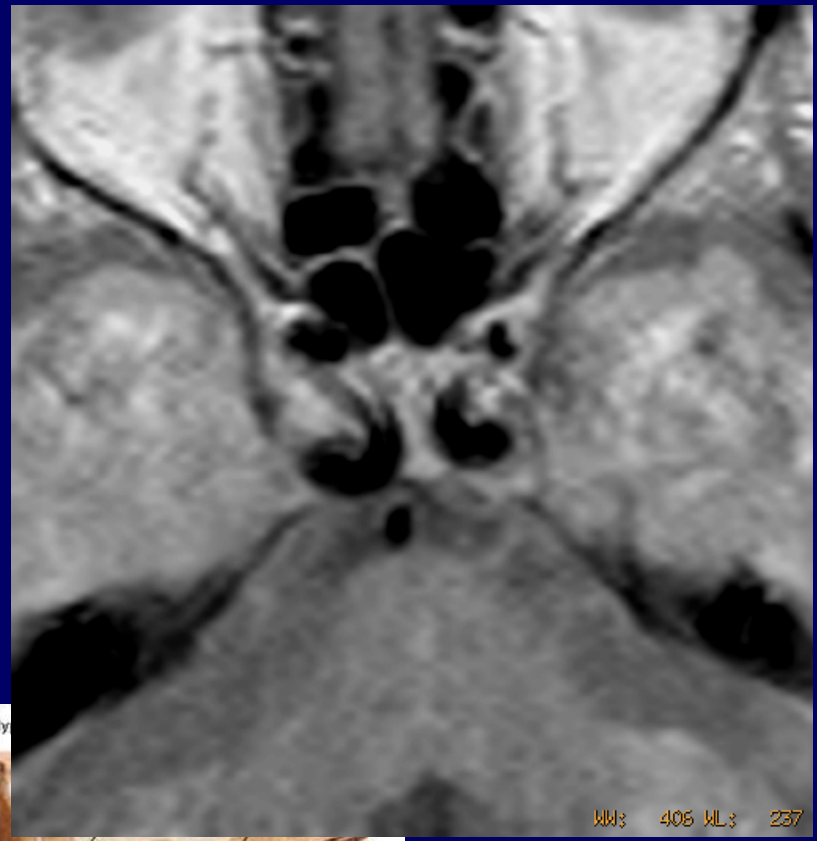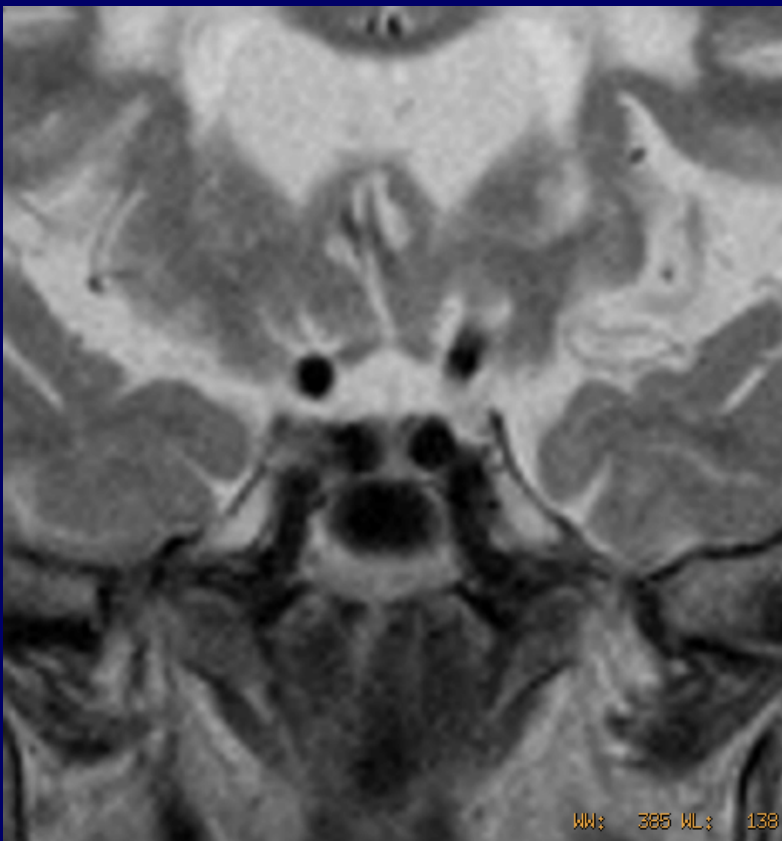
selle 'vide' peu expansive



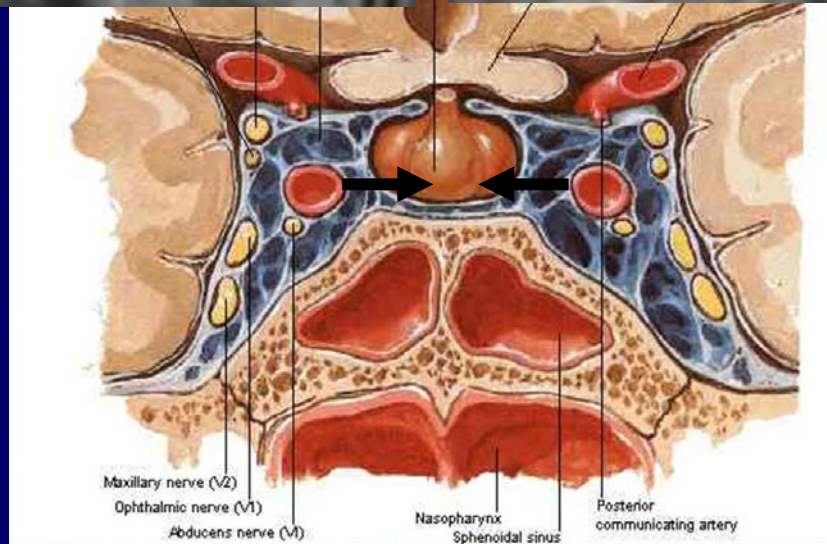
T1 post C+



Selle 'vide' très expansive



Procidence
carotidienne



'Kissing ICAs'

Pathologie tumorale bénigne

Adénome hypophysaire

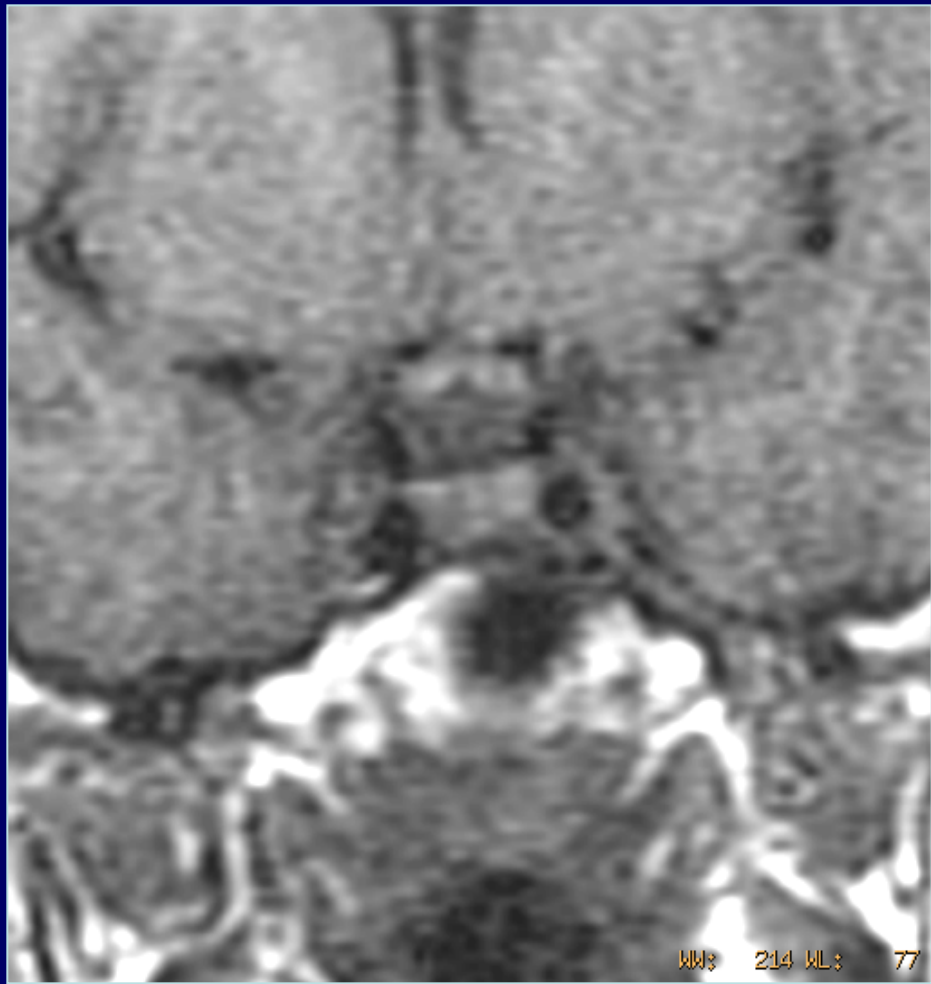
> 90% des lésions tumorales de l'hypophyse

bénigne >>> maligne

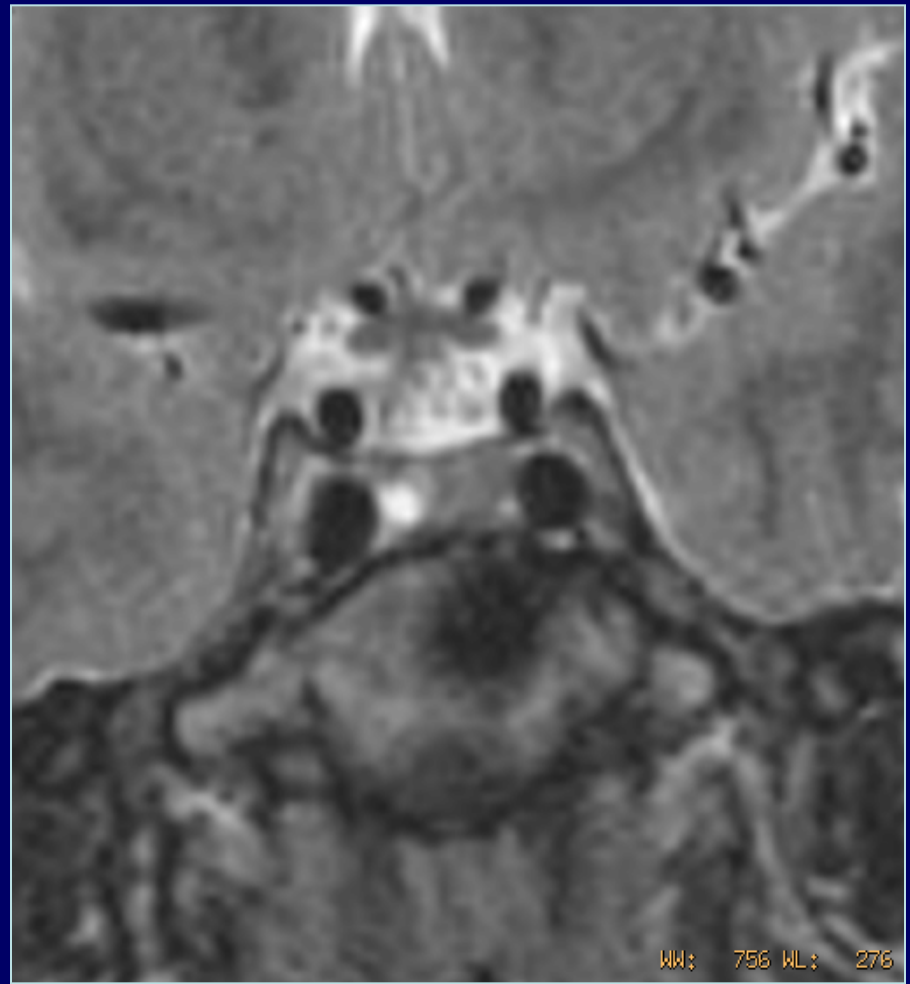« macro-adénome » = « >10 mm »

Sécrétants → Δ MICRO

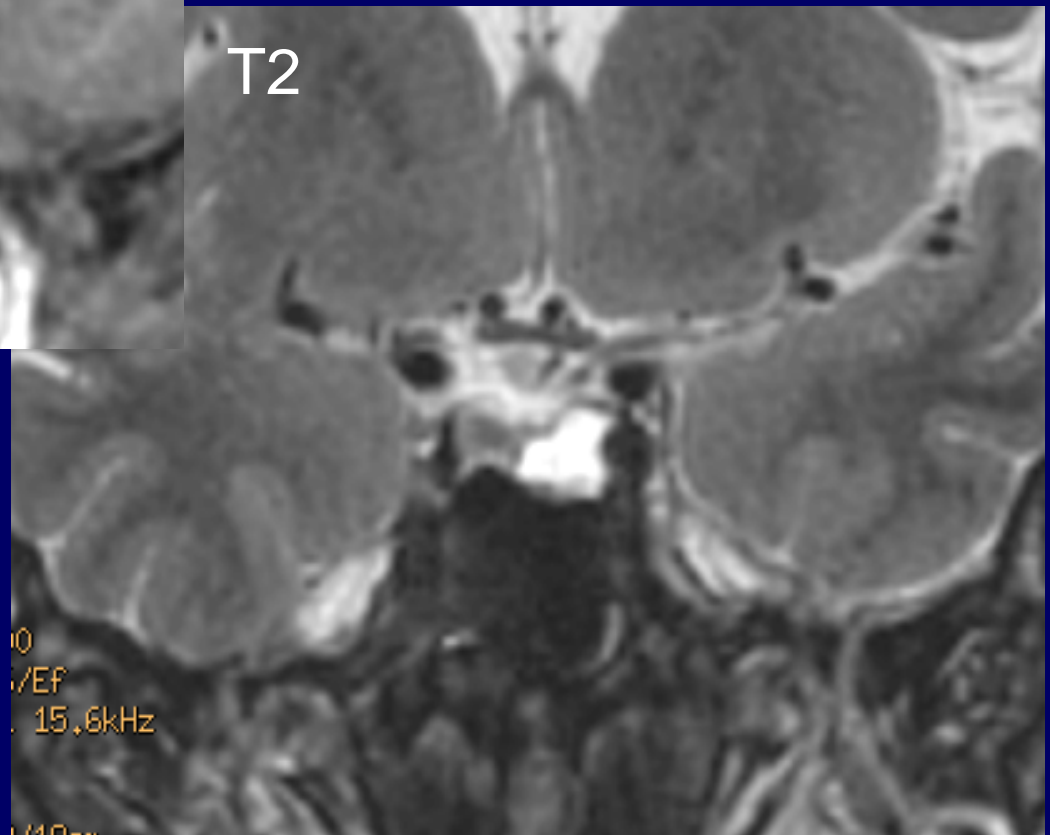
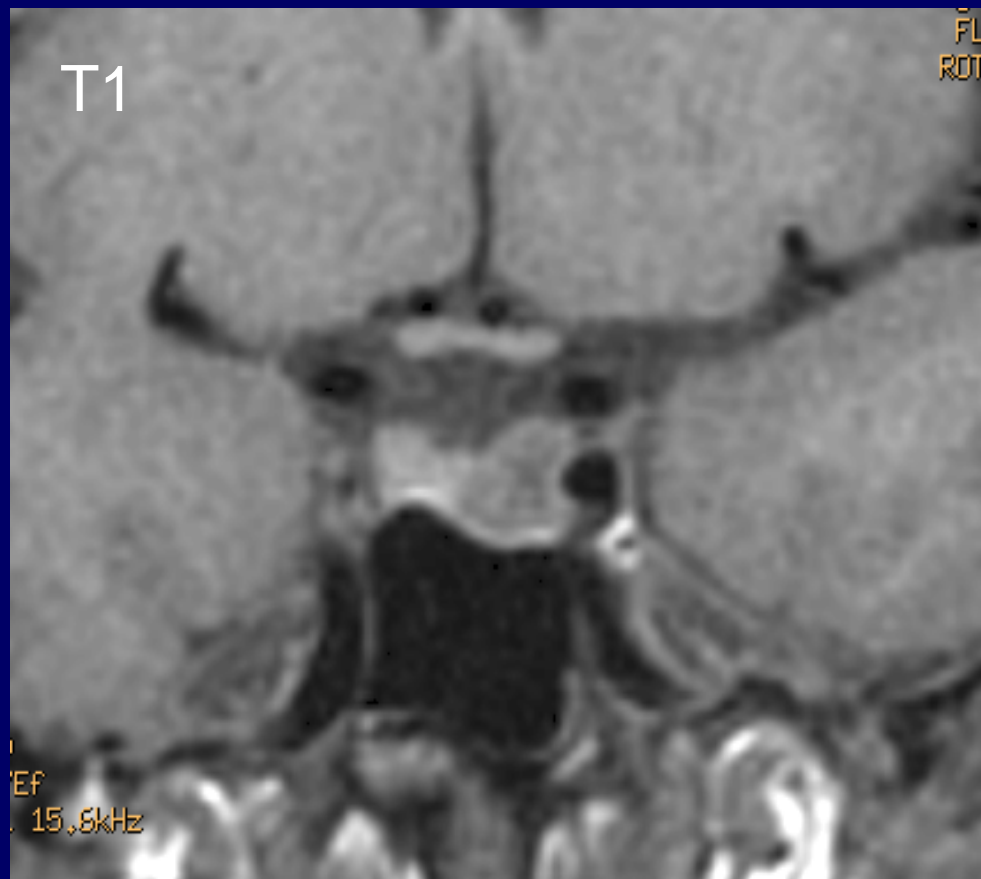Non sécrétants → Δ MACRO

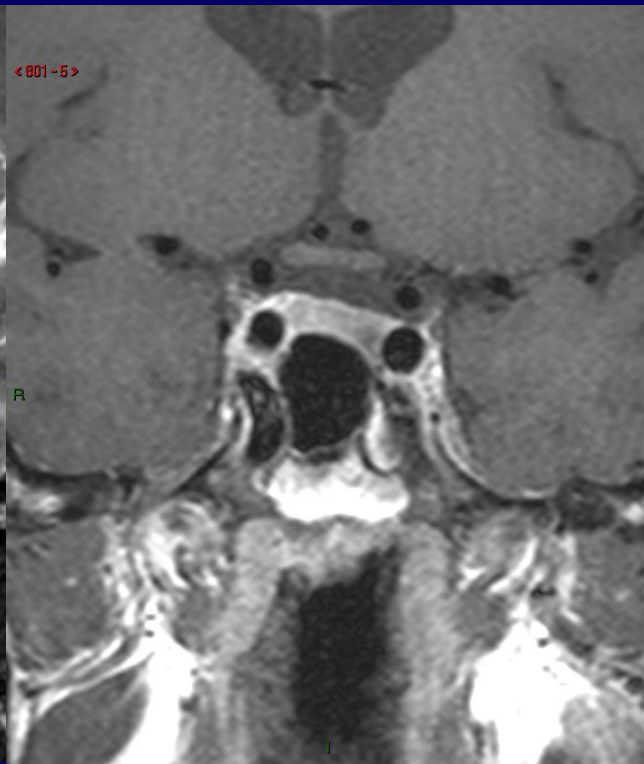
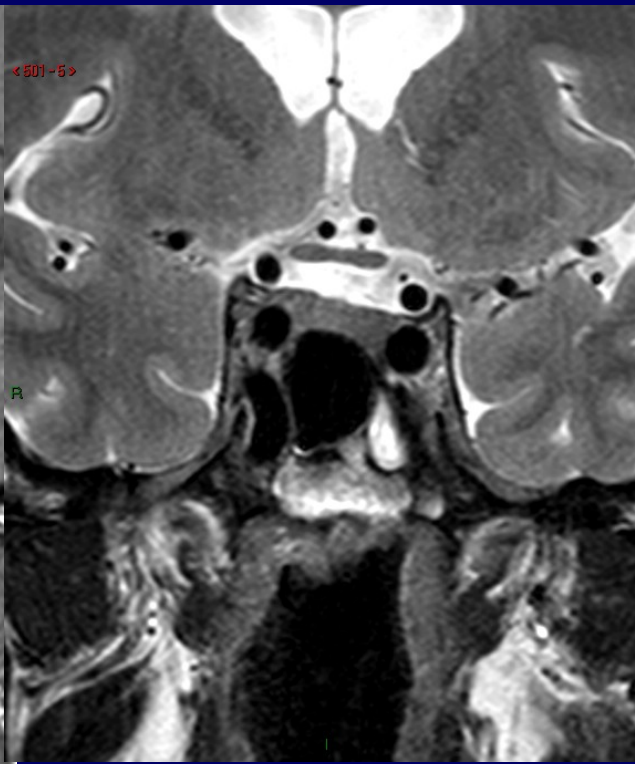
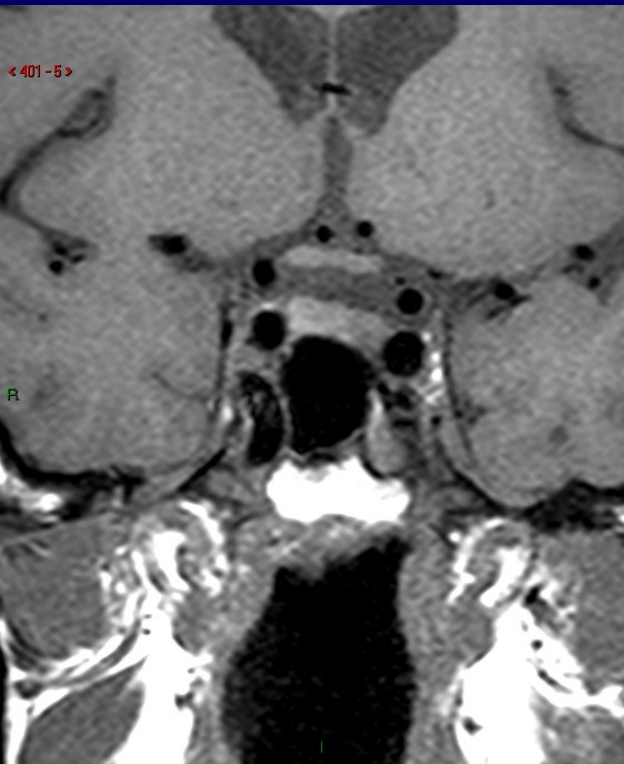
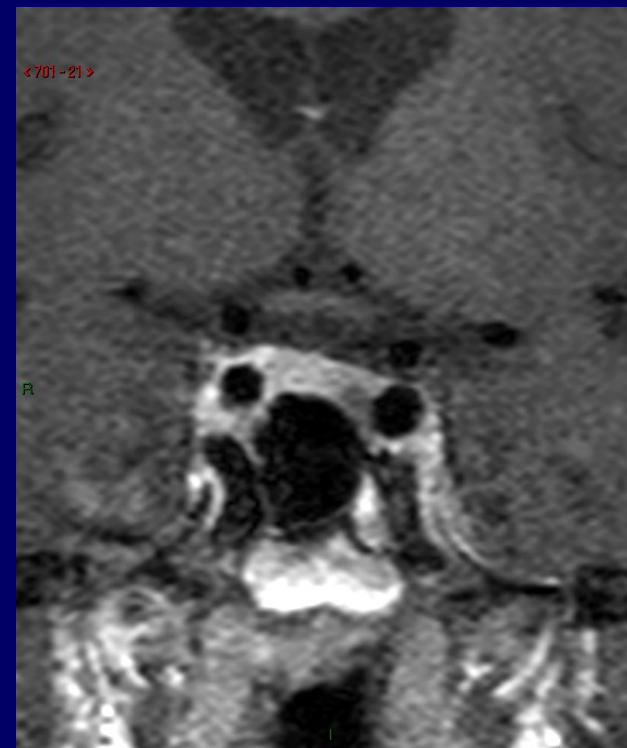
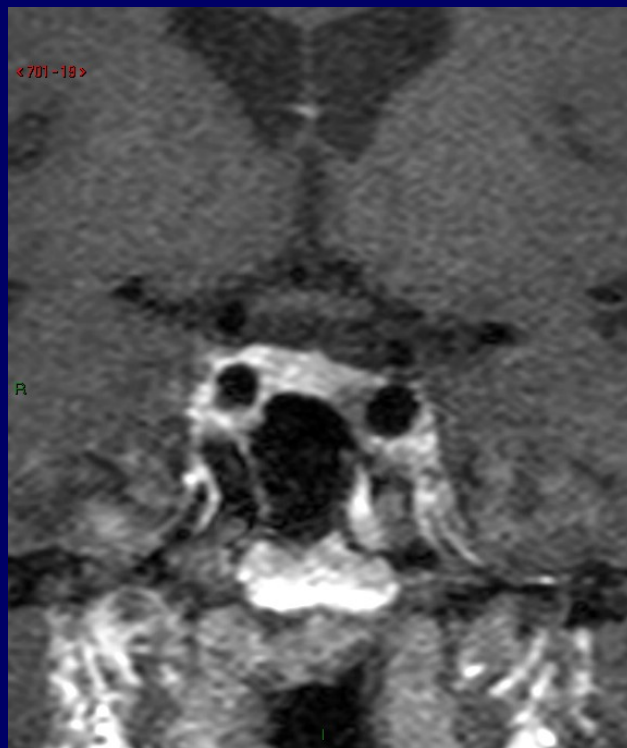
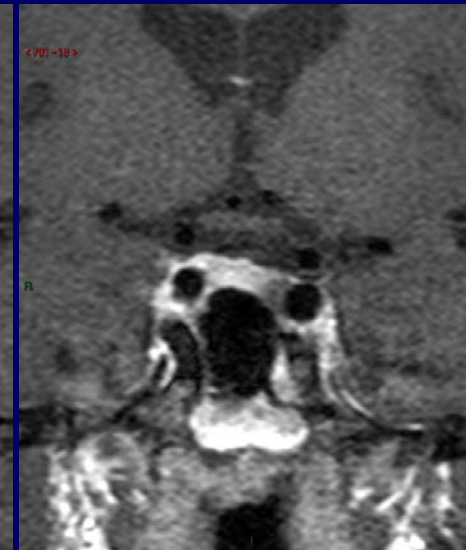
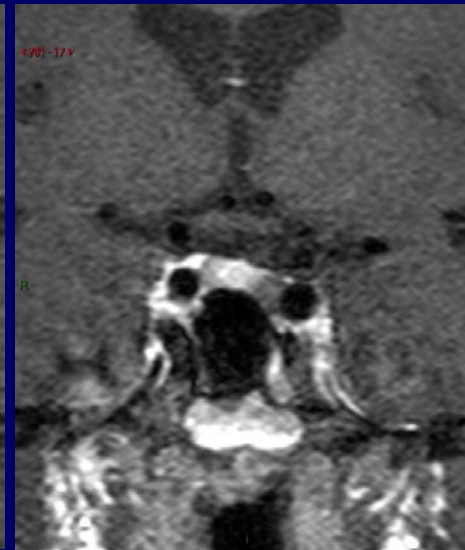
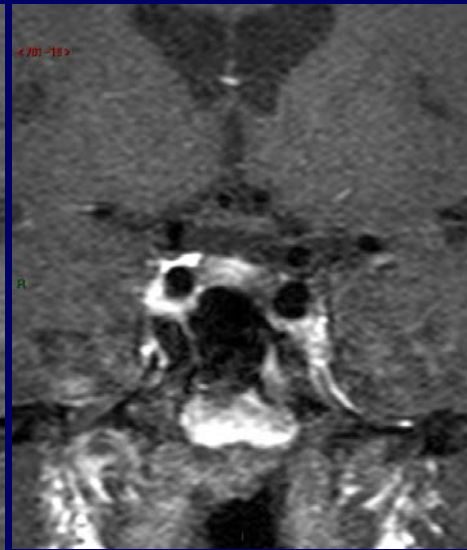
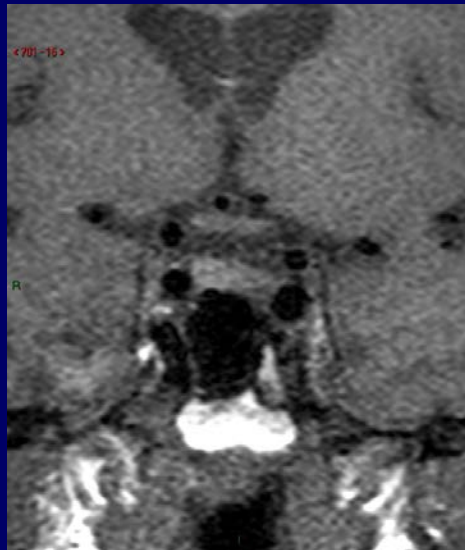
T1 sans C+

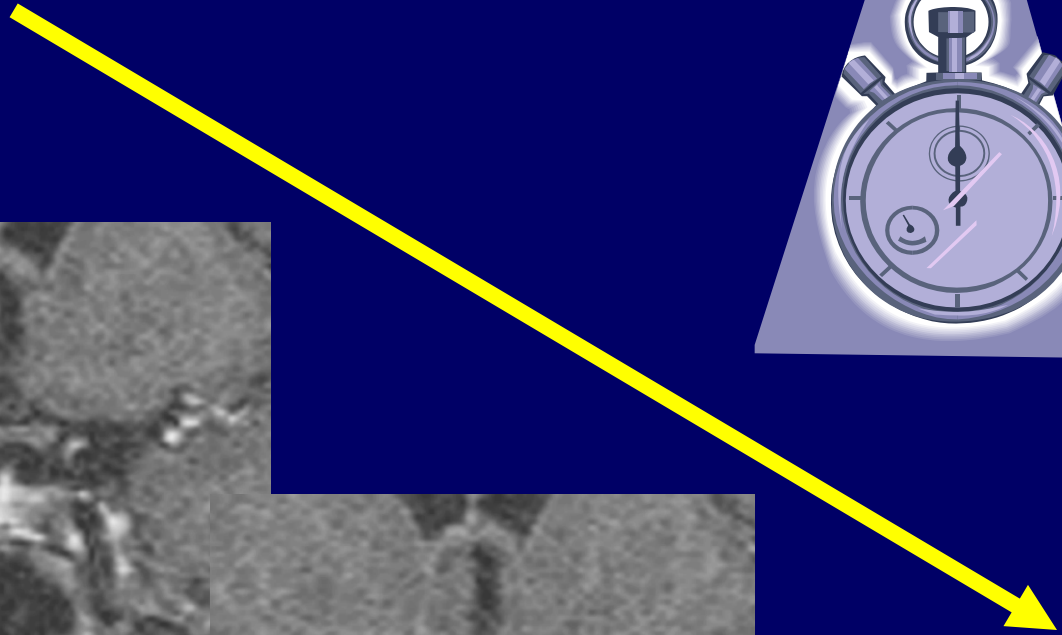

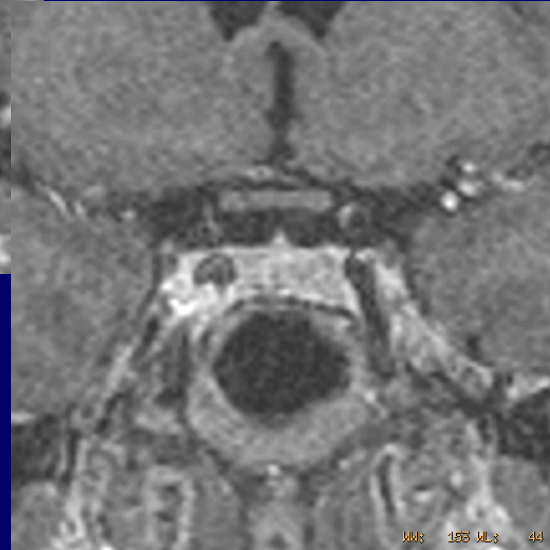
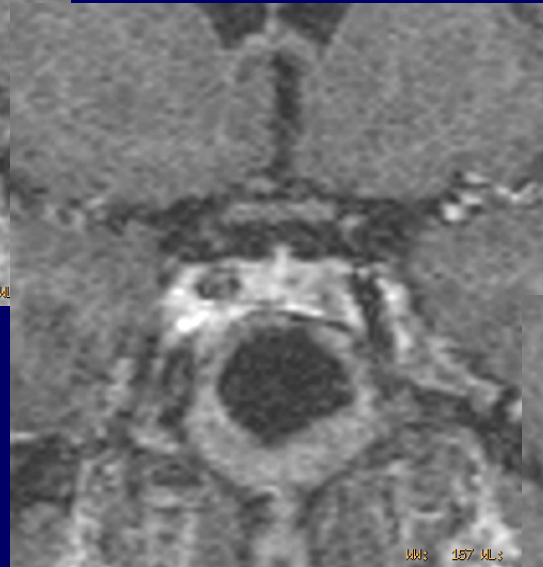
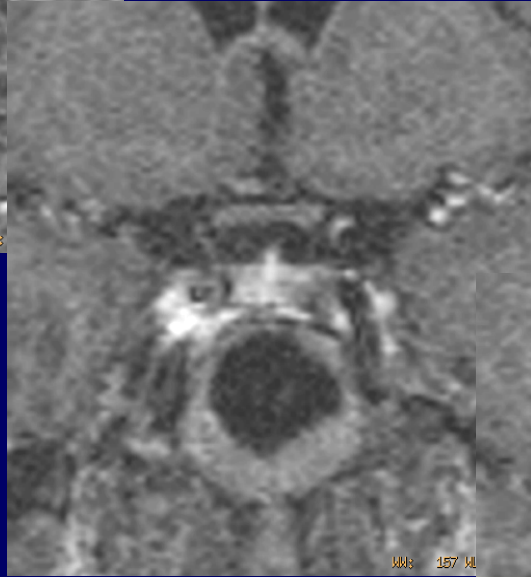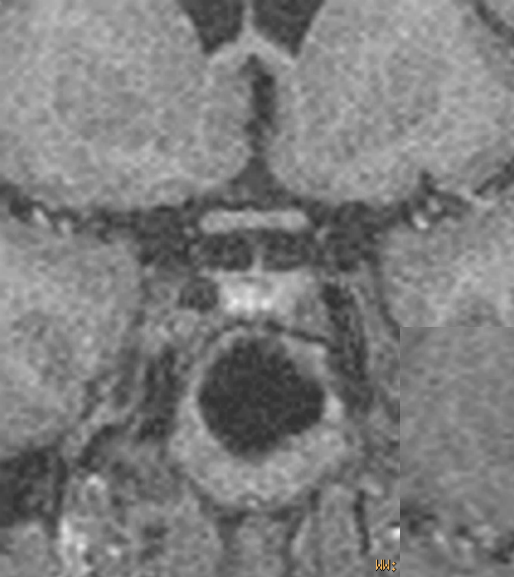


T2

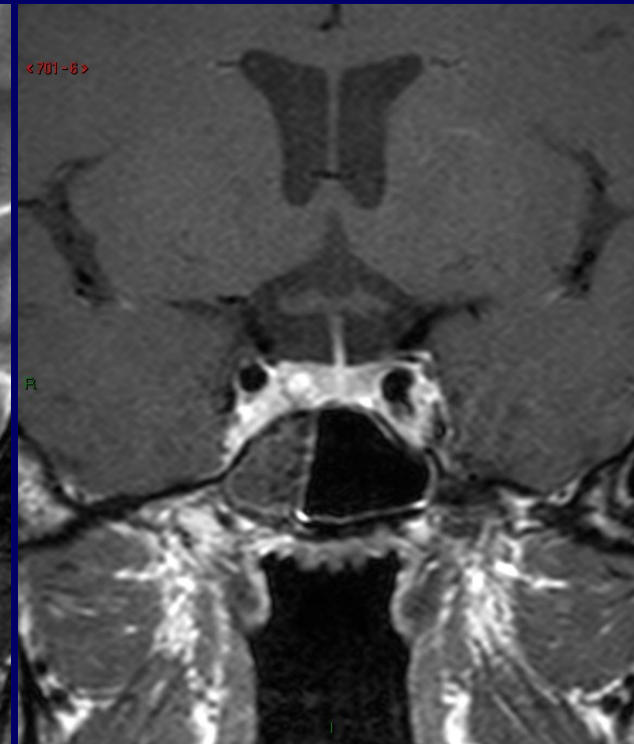
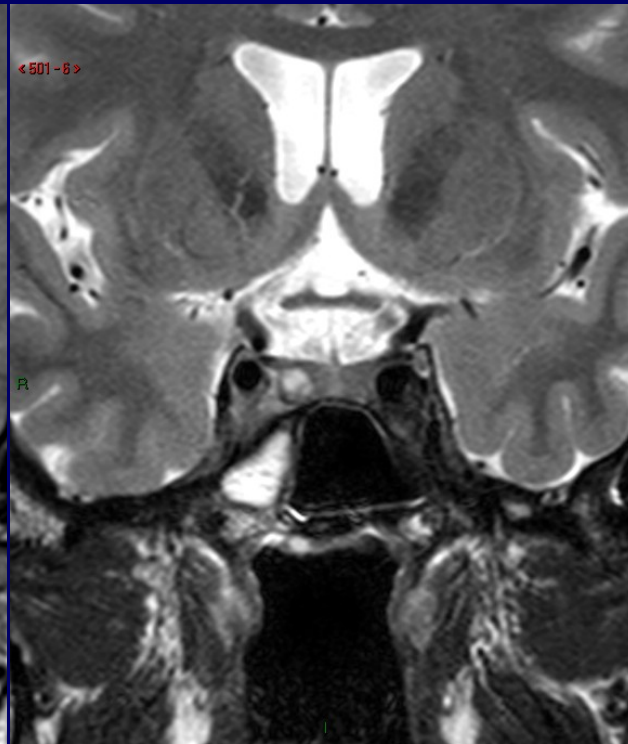
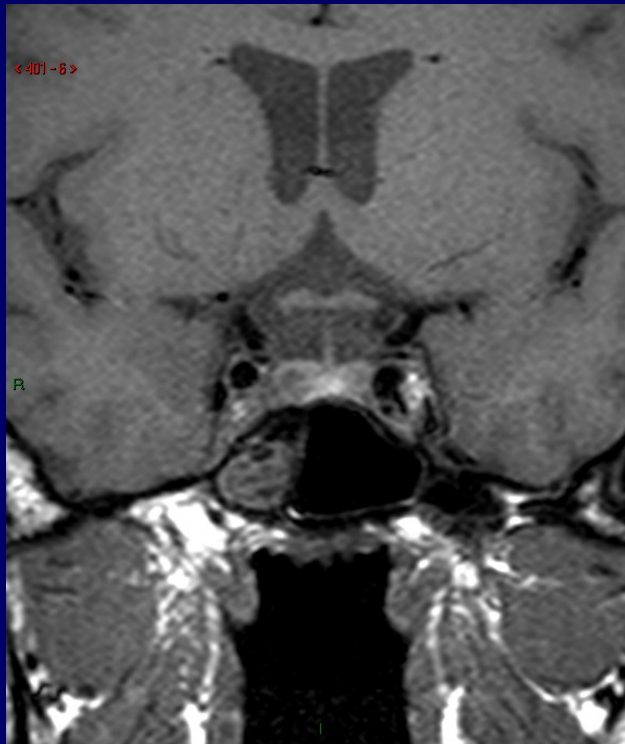




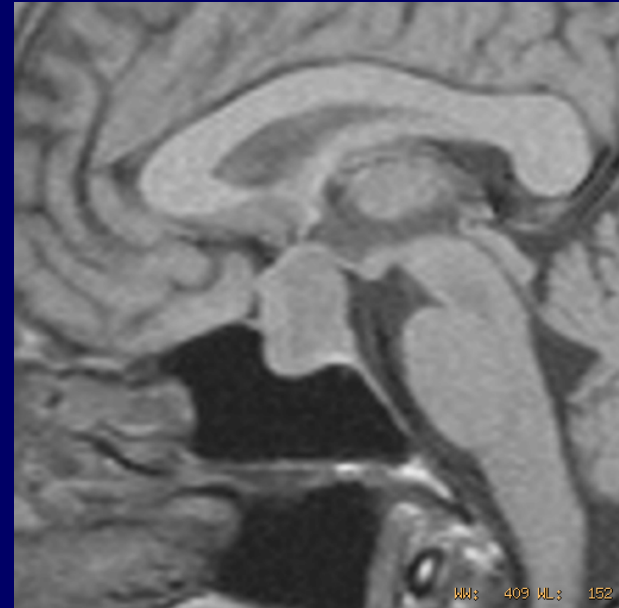
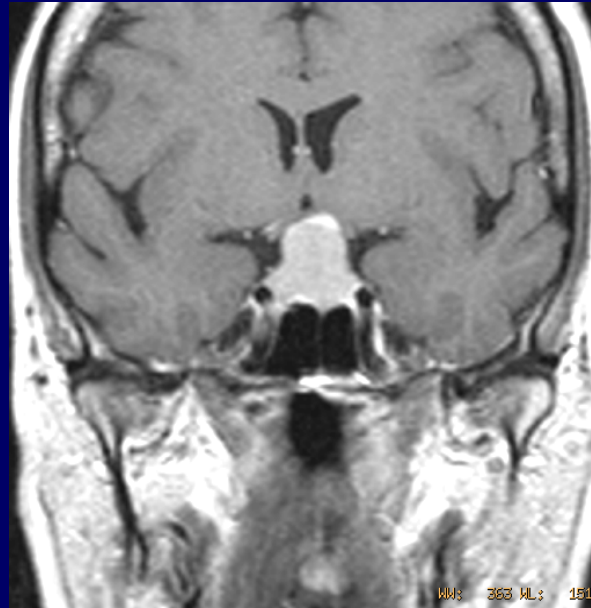
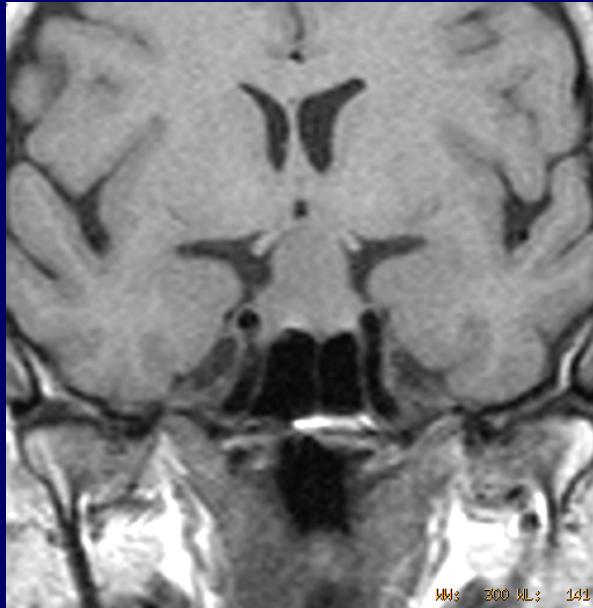




Forme rare de micro-adénome: hyperrehaussant

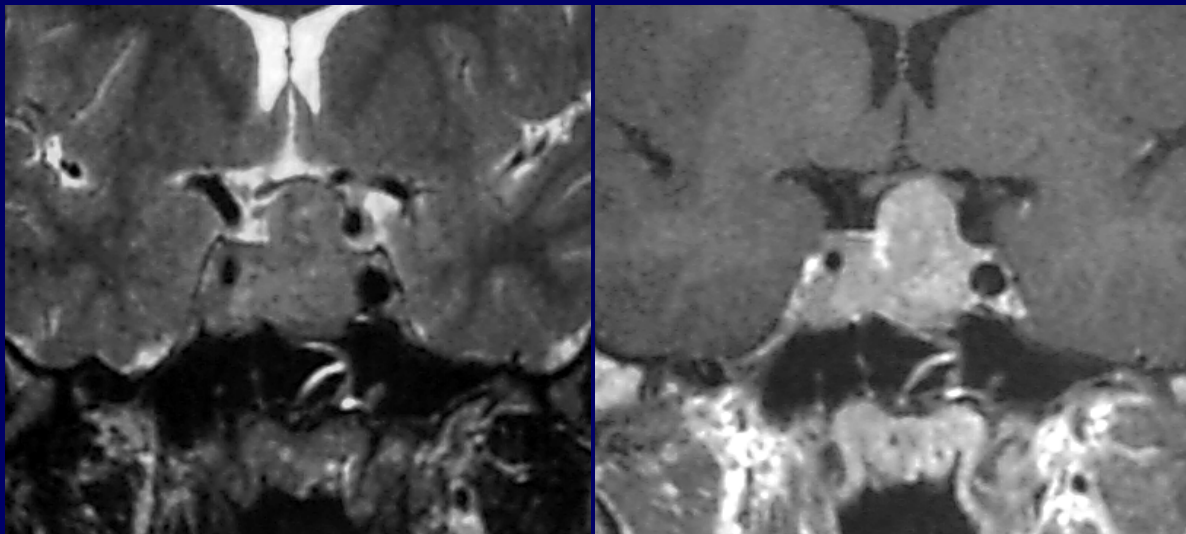
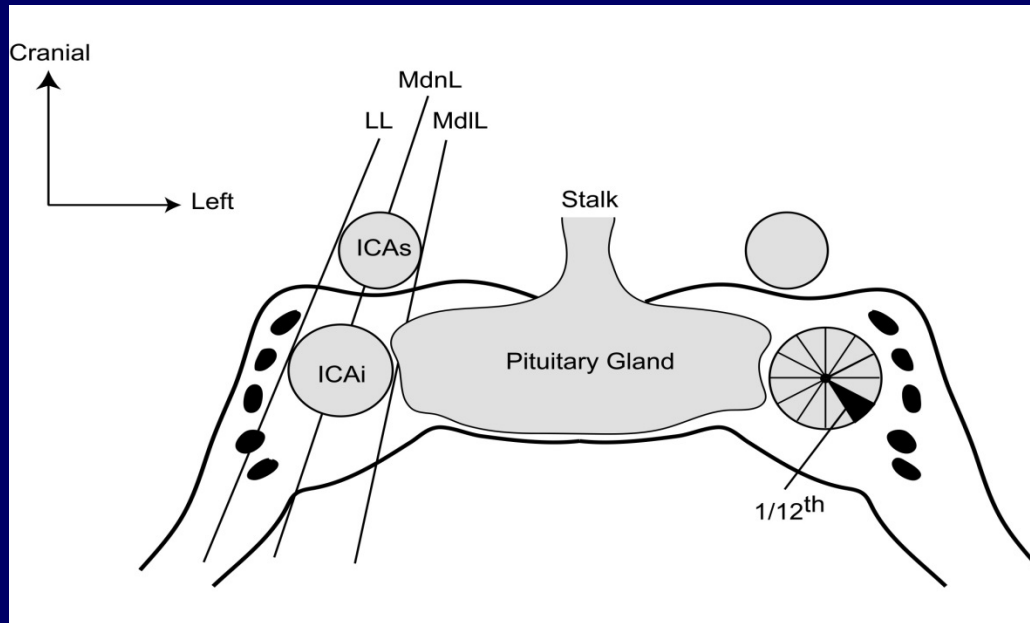


Macro-adénome hypophysaire:



1. Compression optique

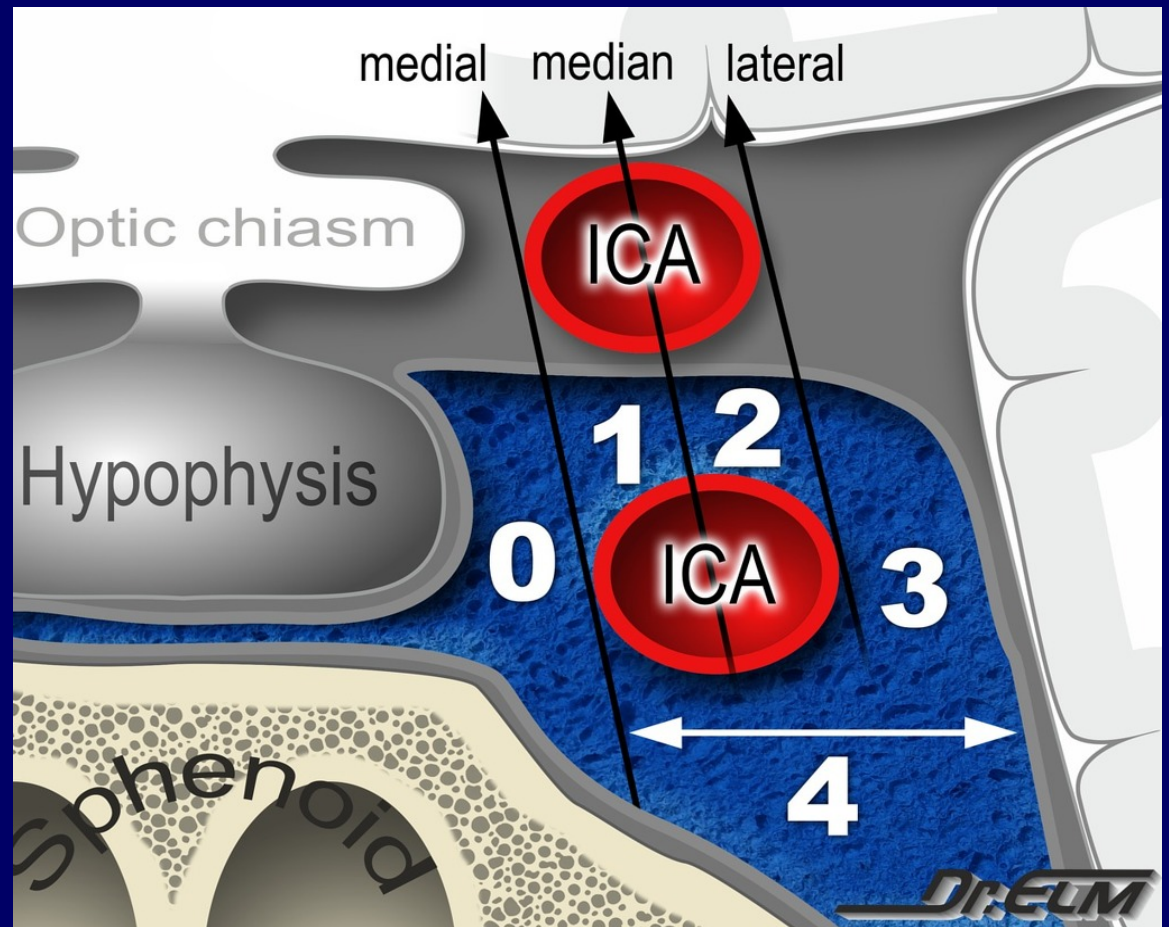
2. Envahissement du sinus caverneux



Knosp

Neurosurgery 1993

0-1: pas d'invasion
2: invasion sauf 1
3-4: tous envahis

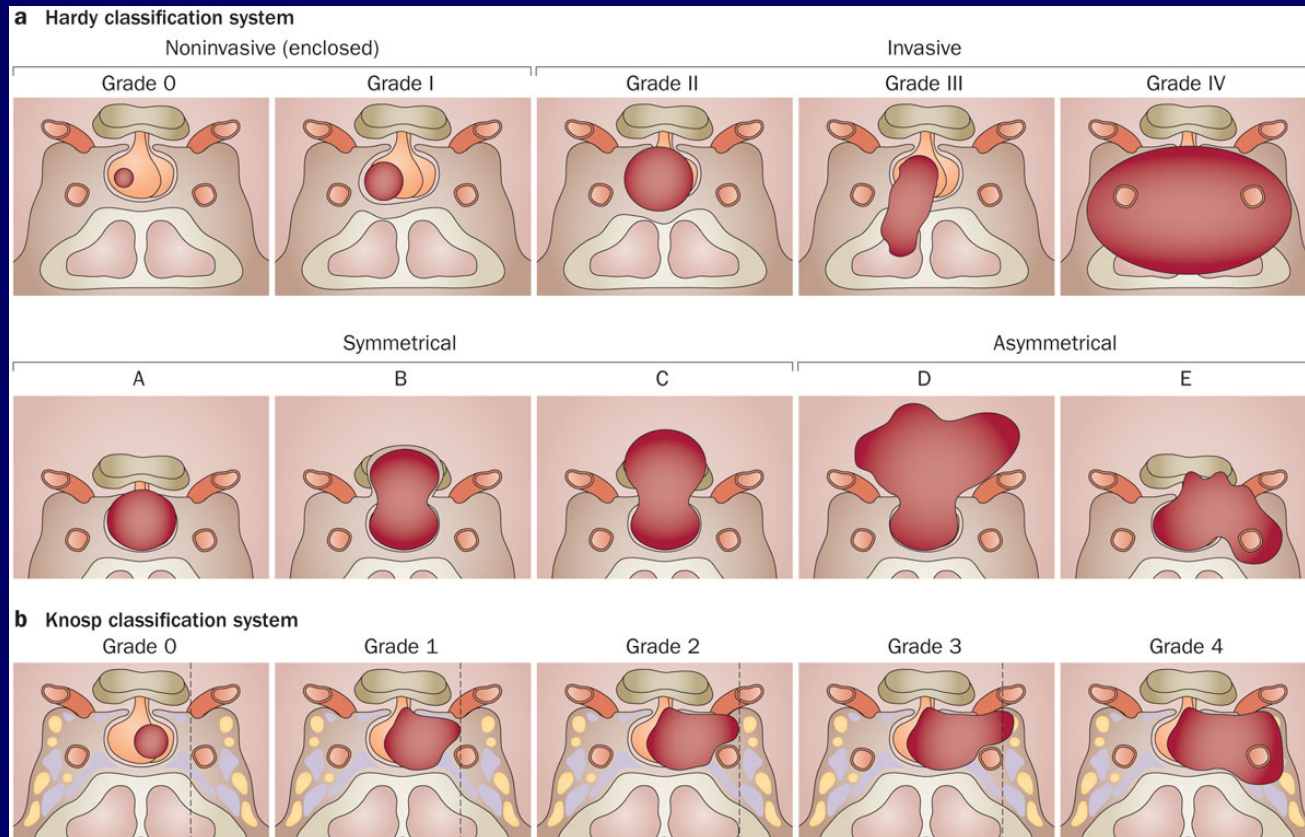


// entre grade et **l'agressivité tumorale**

*%KI67

*Résistance au traitement agoniste

Figure 3 Classification systems used to characterize pituitary adenomas



Di Ieva, A. *et al.* (2014) Aggressive pituitary adenomas—diagnosis and emerging treatments
Nat. Rev. Endocrinol. doi:10.1038/nrendo.2014.64

[Ann Endocrinol \(Paris\)](#). 2000

Sep;61(3):269-74.

[MRI diagnosis of cavernous sinus invasion by pituitary adenomas].

[Article in French]

[Cottier JP](#)¹, [Destrieux C](#), [Vinikoff-Sonier C](#),
[Jan M](#), [Herbreteau D](#).

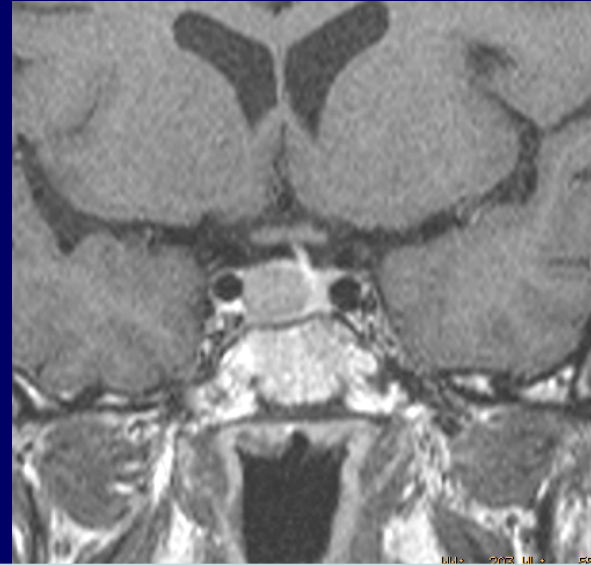
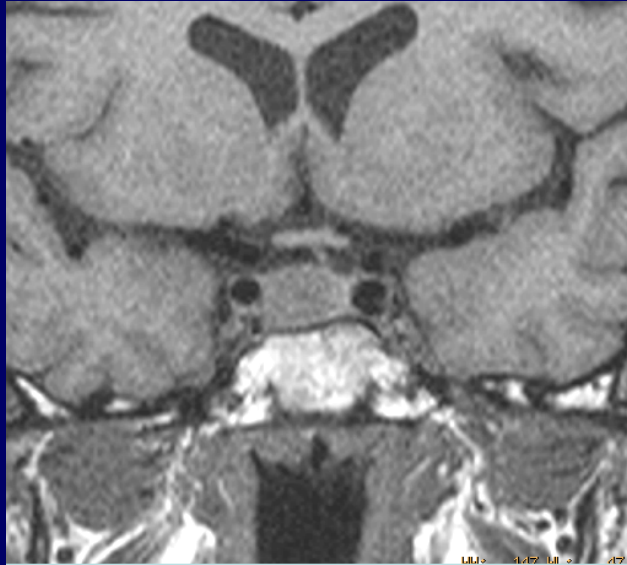
Incarcération Carotide Interne intra-caverneuse

>66% → envahi

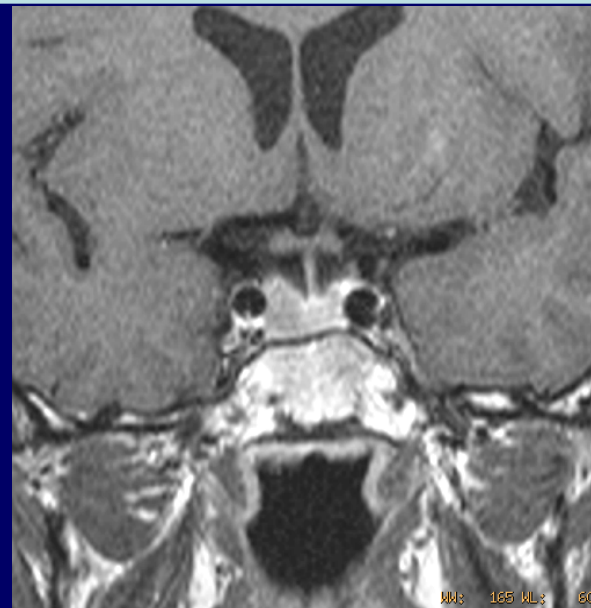
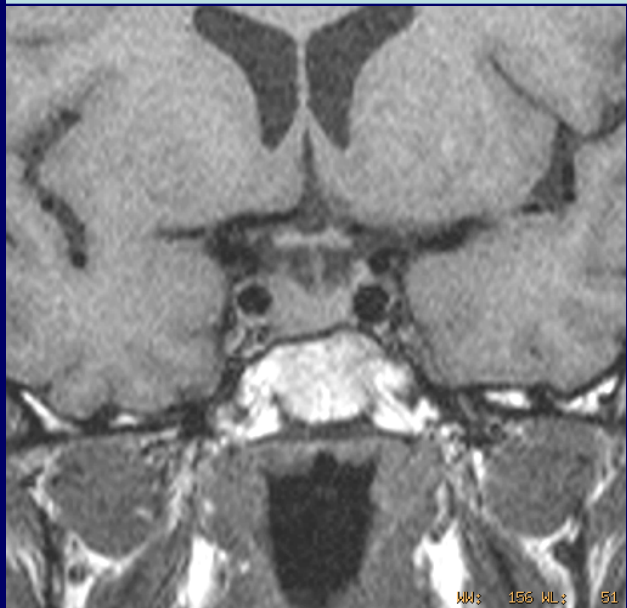<25% → non envahi

25→66% → tracer les lignes de Knosp et signes accessoires

F/U micro-adénome traité médicalement

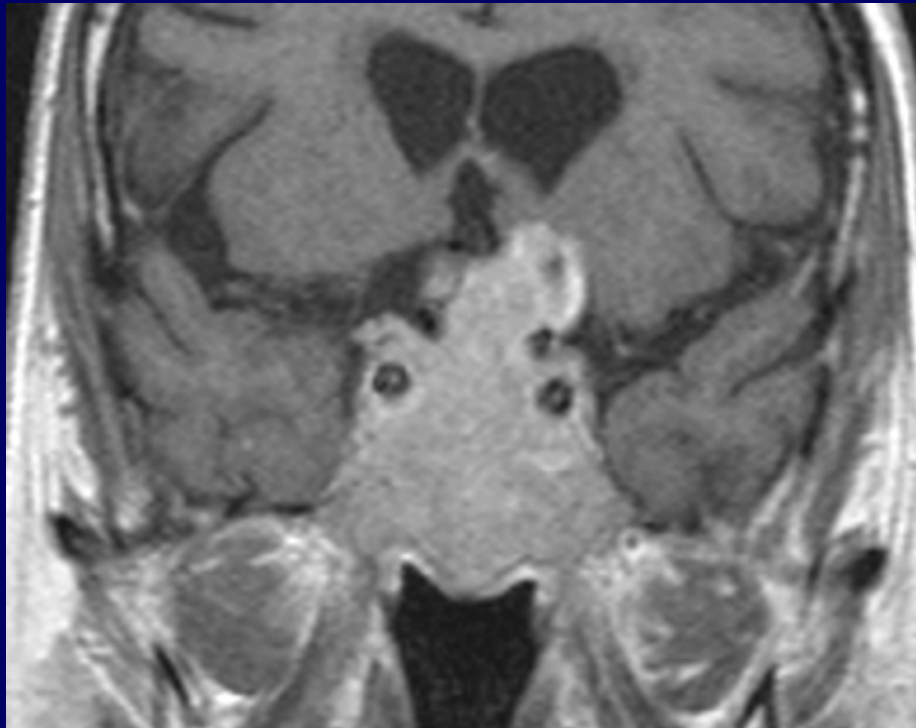

Avant R/

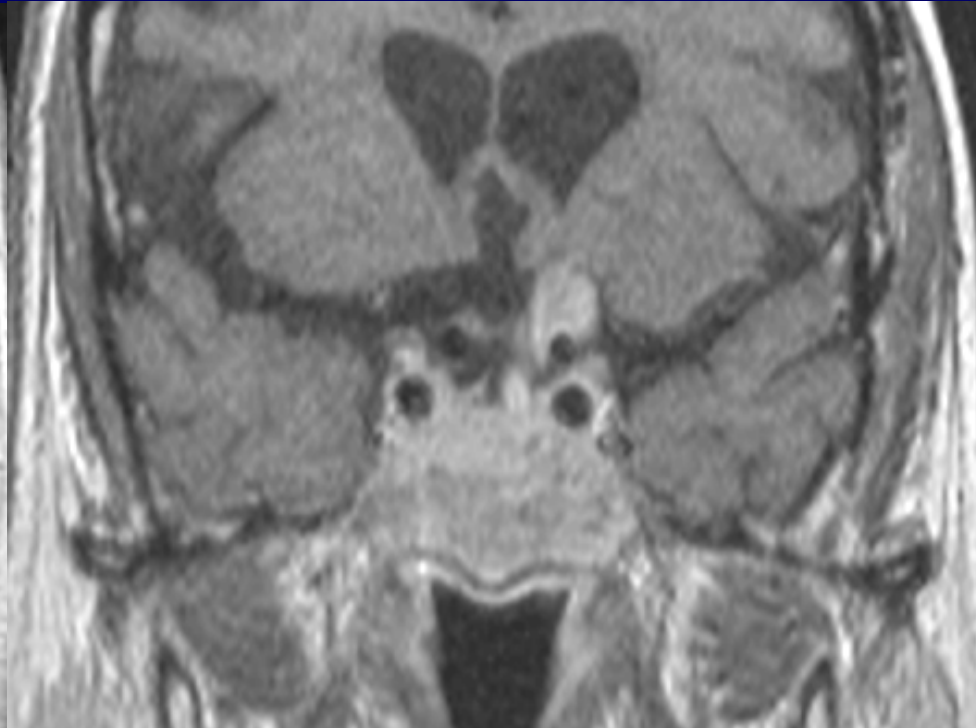

6 mois

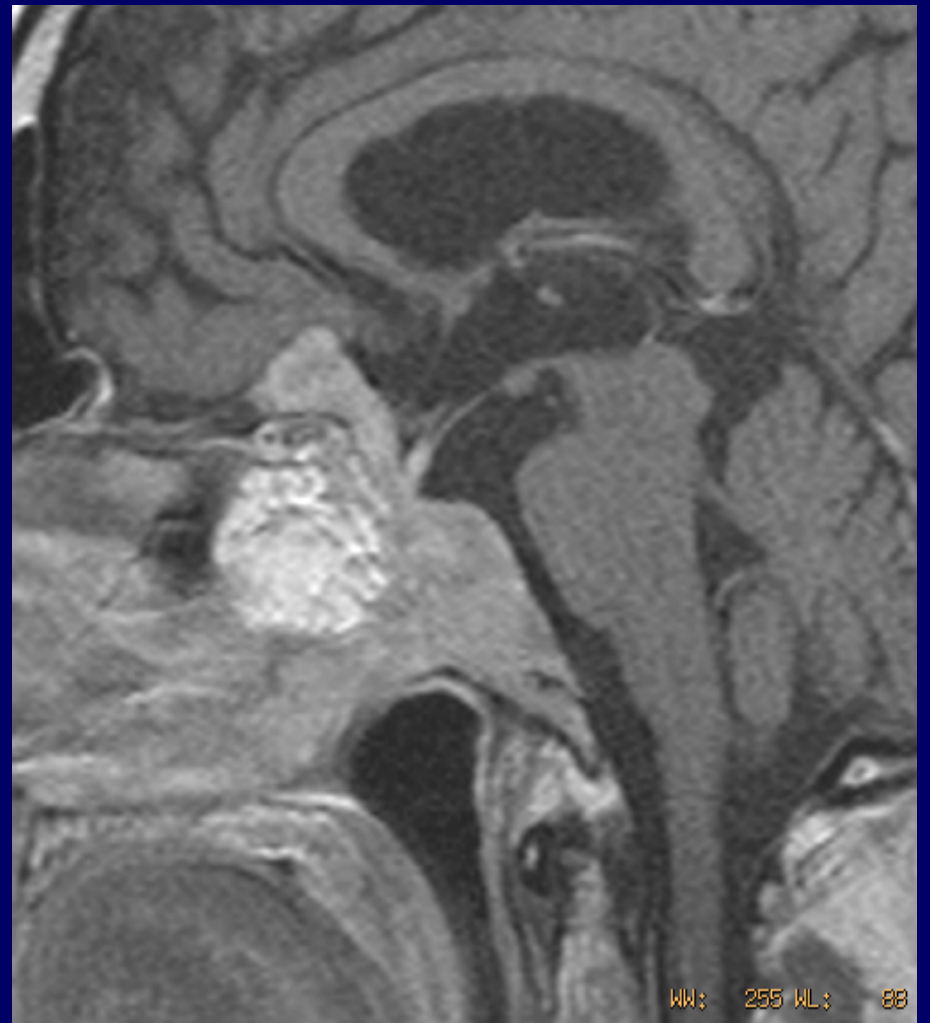
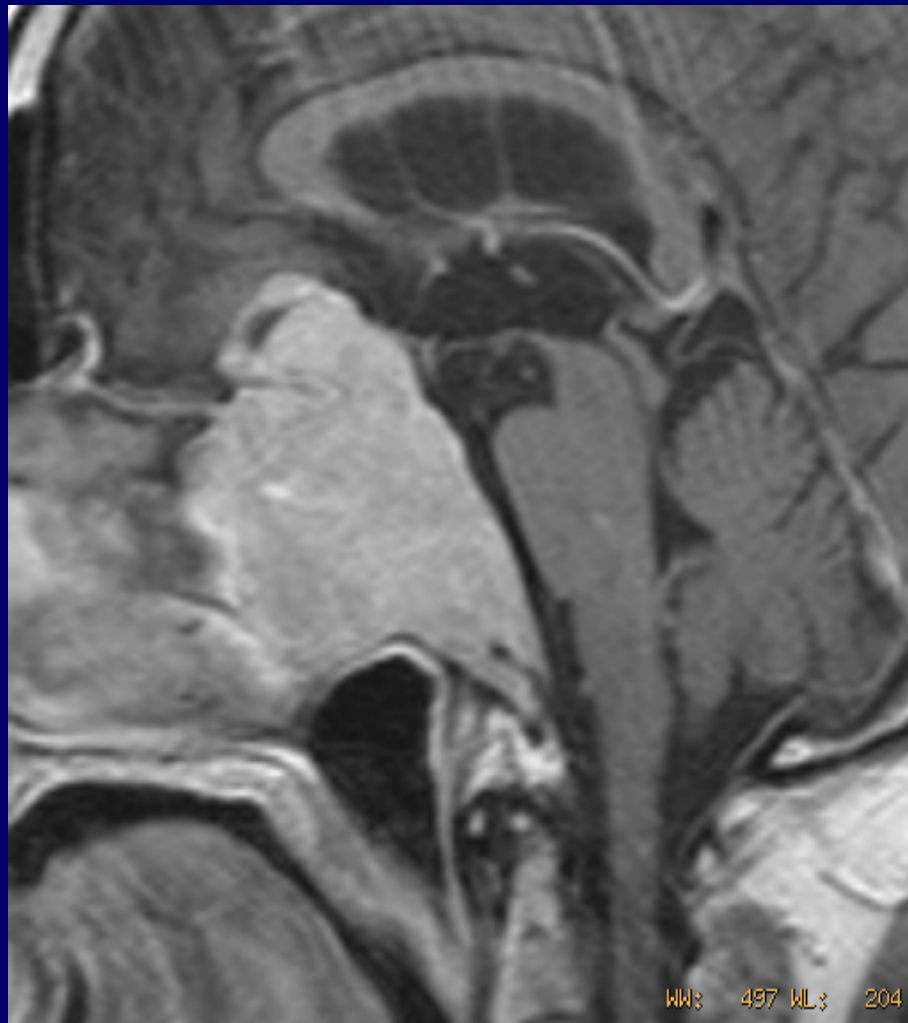
F/U macro-adénome traité chirurgicalement



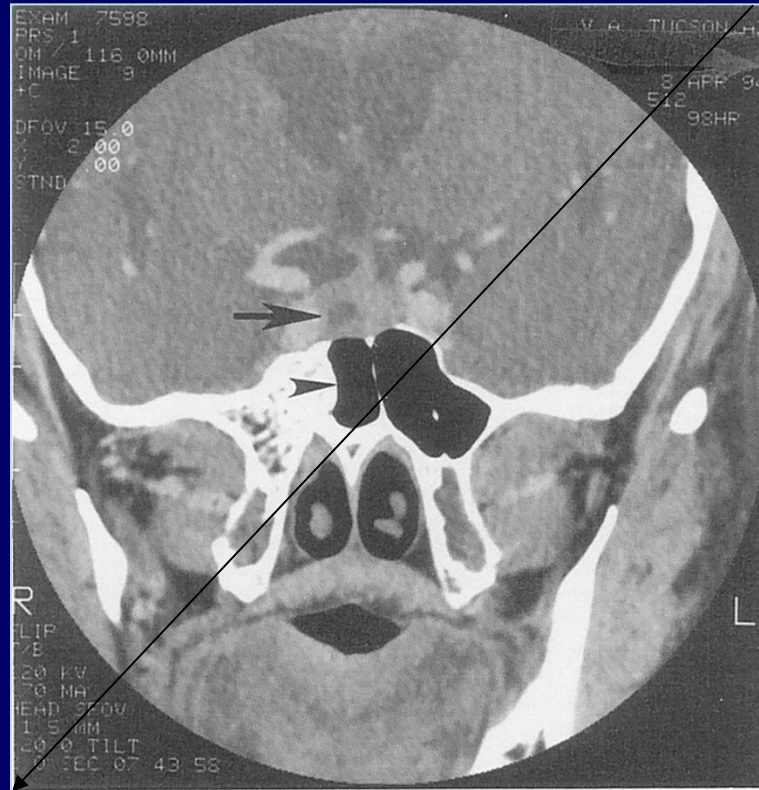
pré-chir.



post-chir.



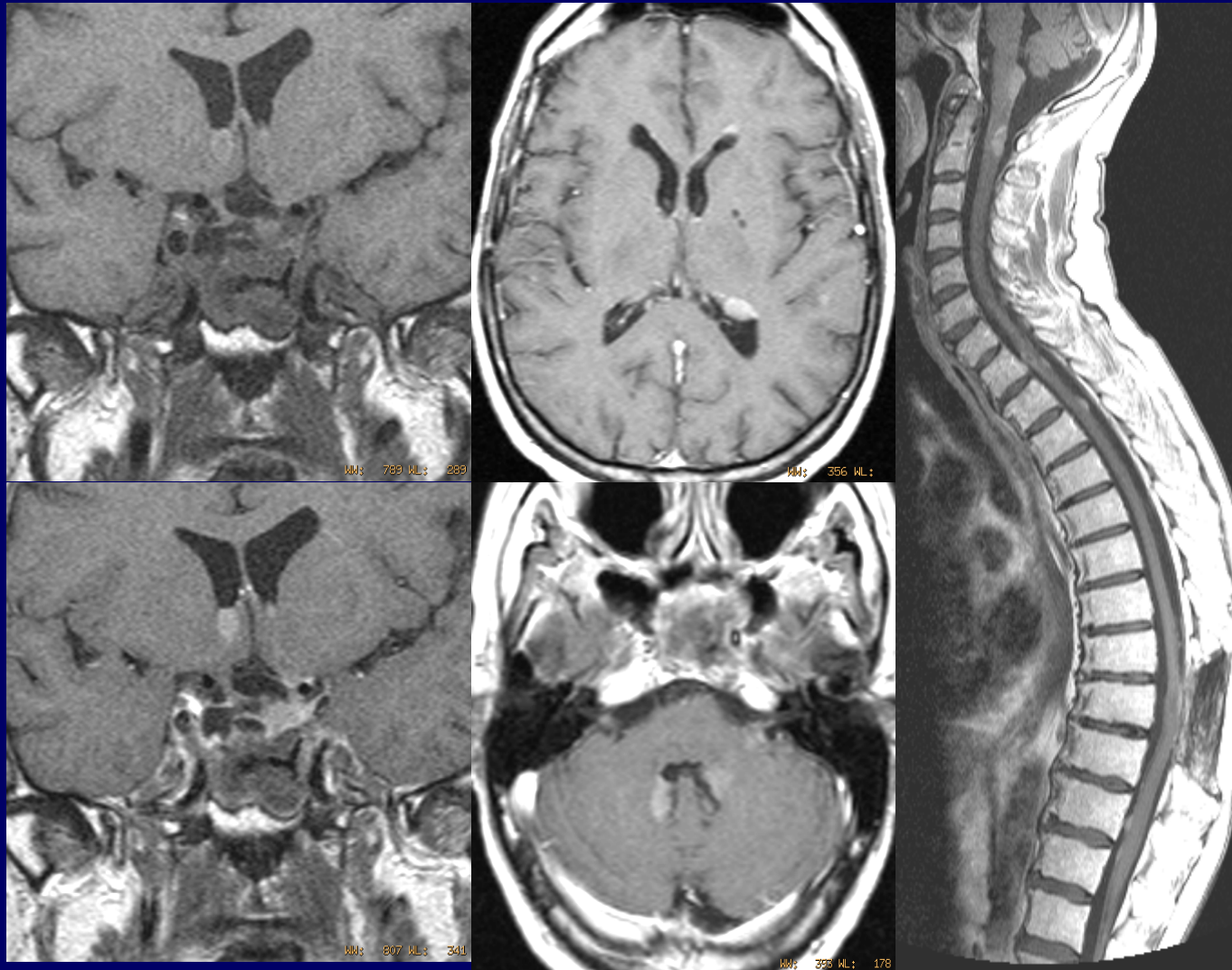
Indications du CT dans l'adénome hypophysaire



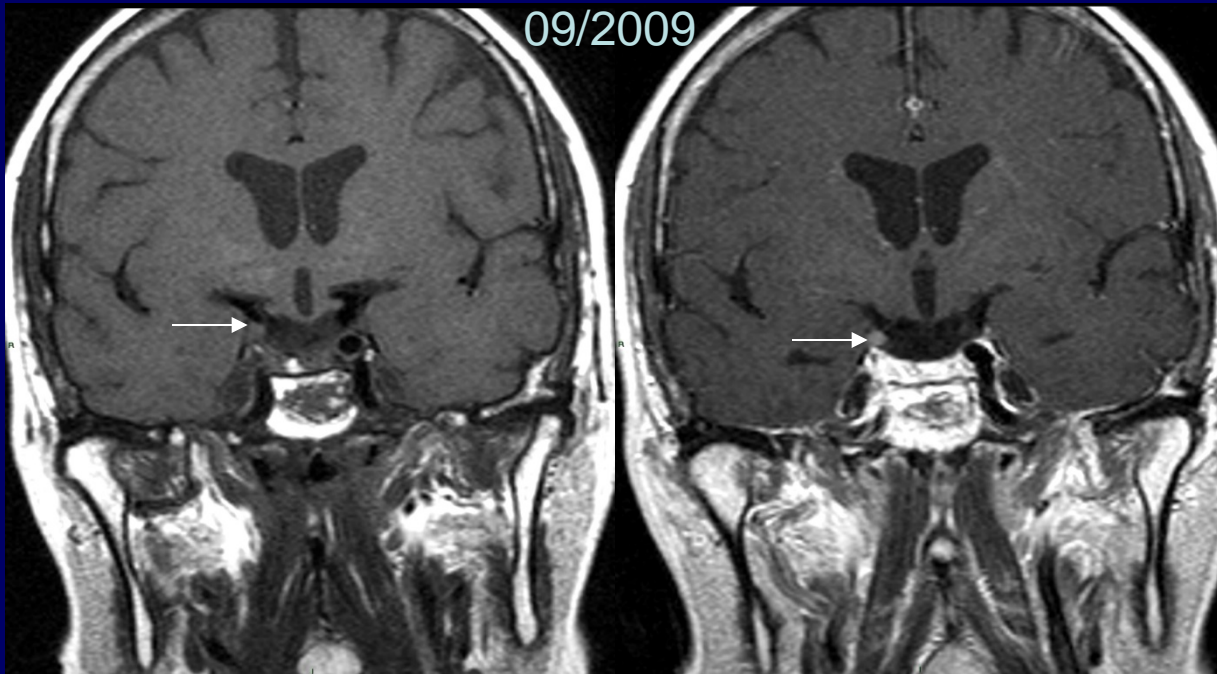
→ contre-indications de l'IRM

adénocarcinome hypophysaire

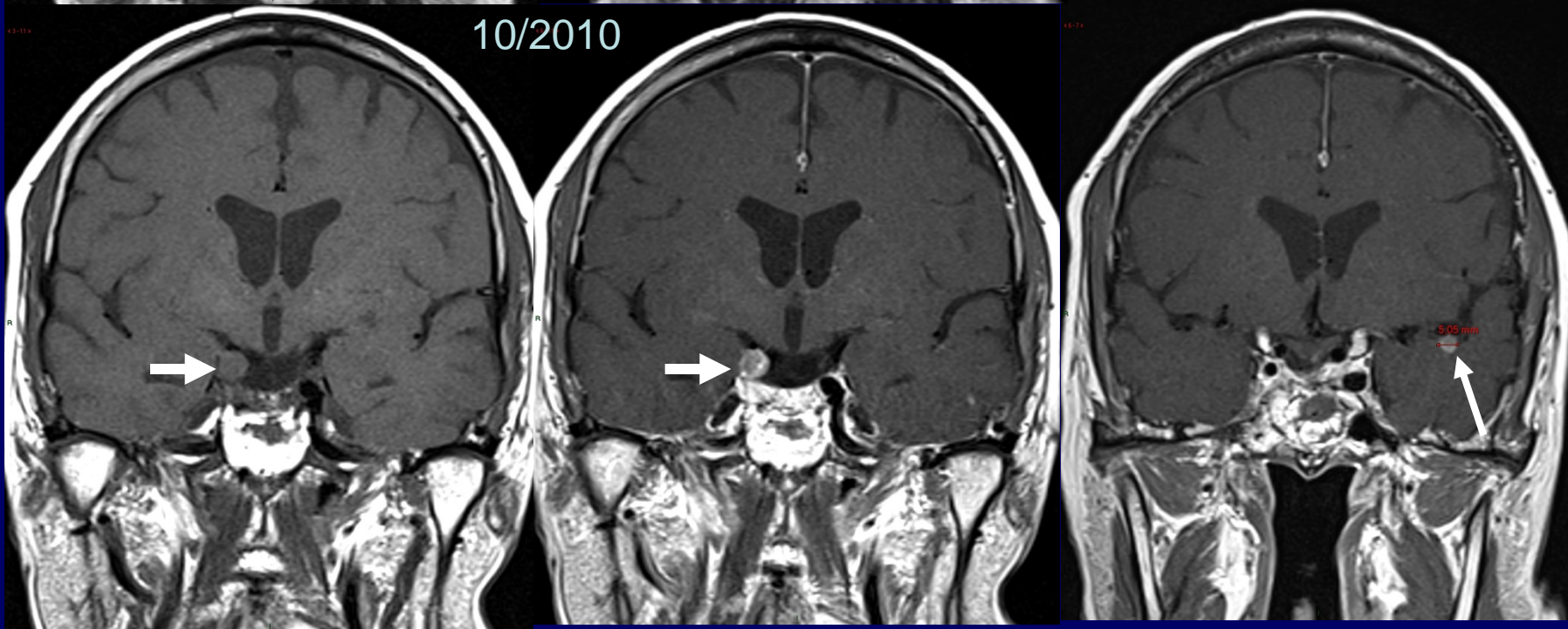
1997

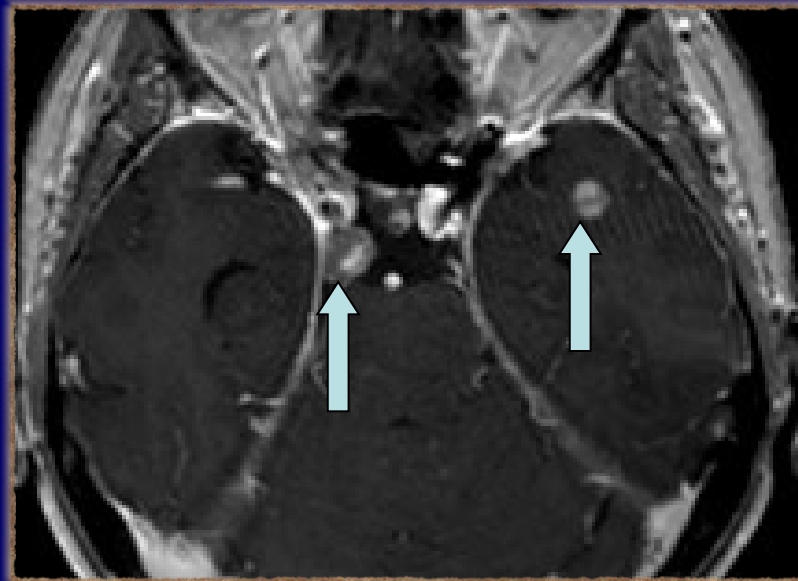
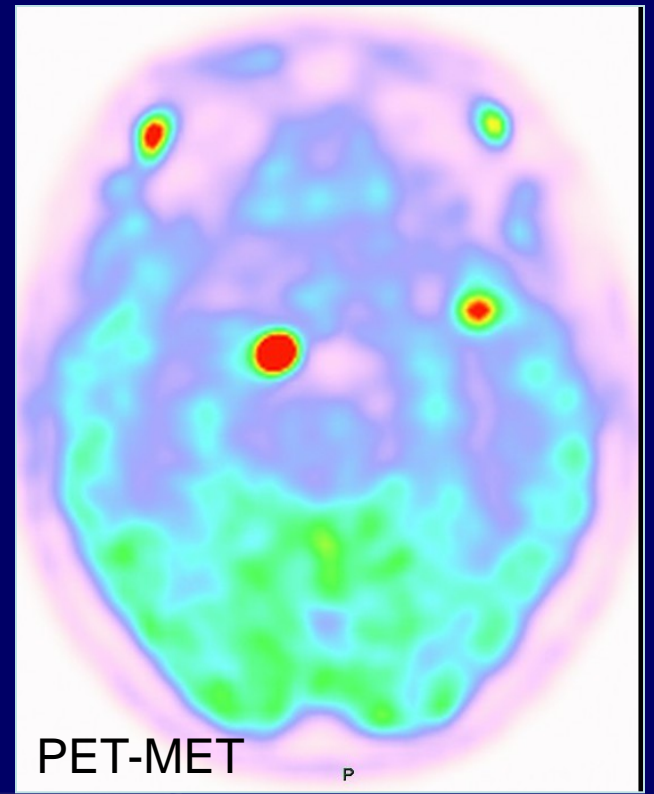
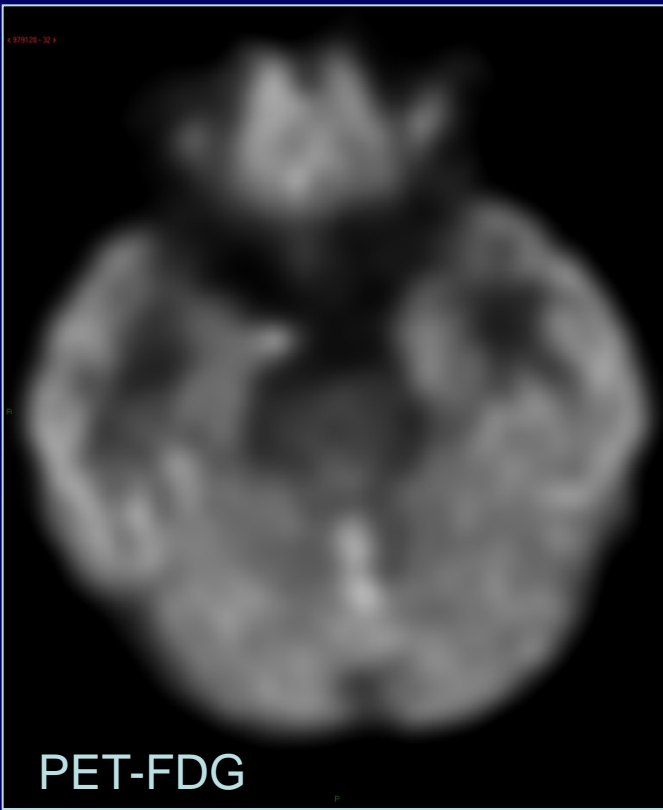


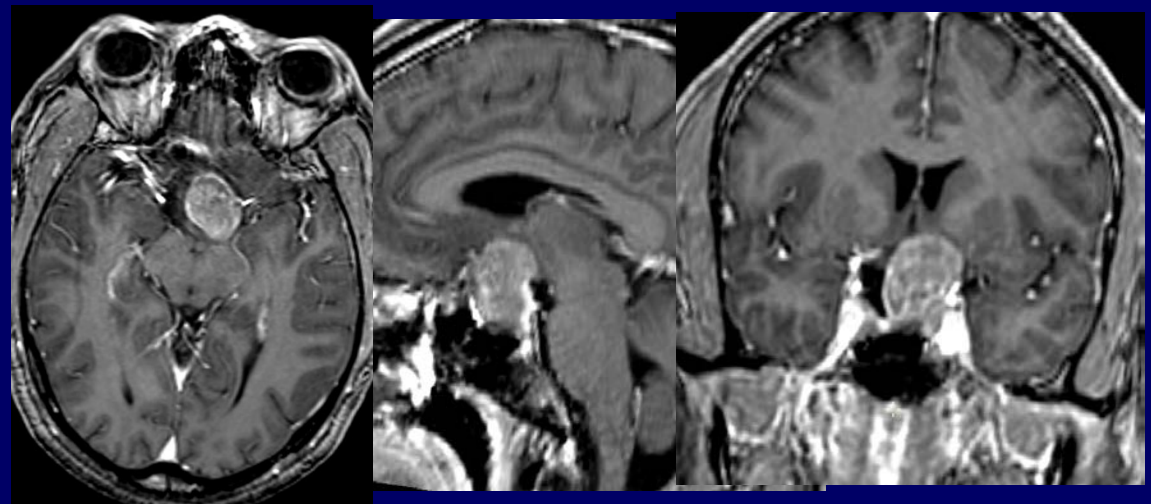
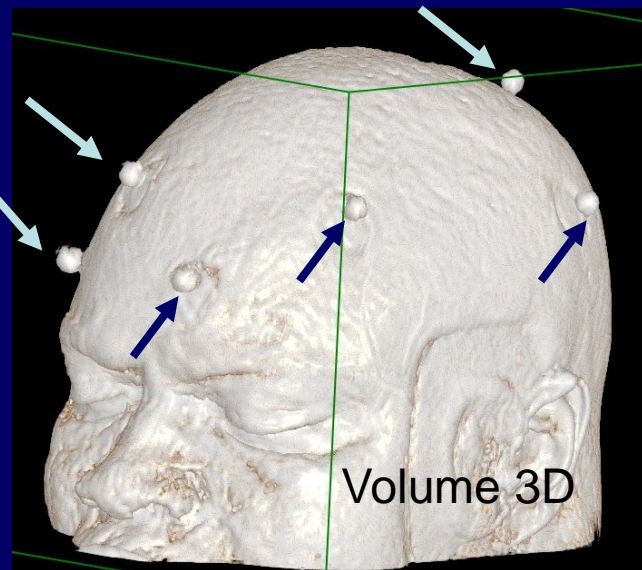
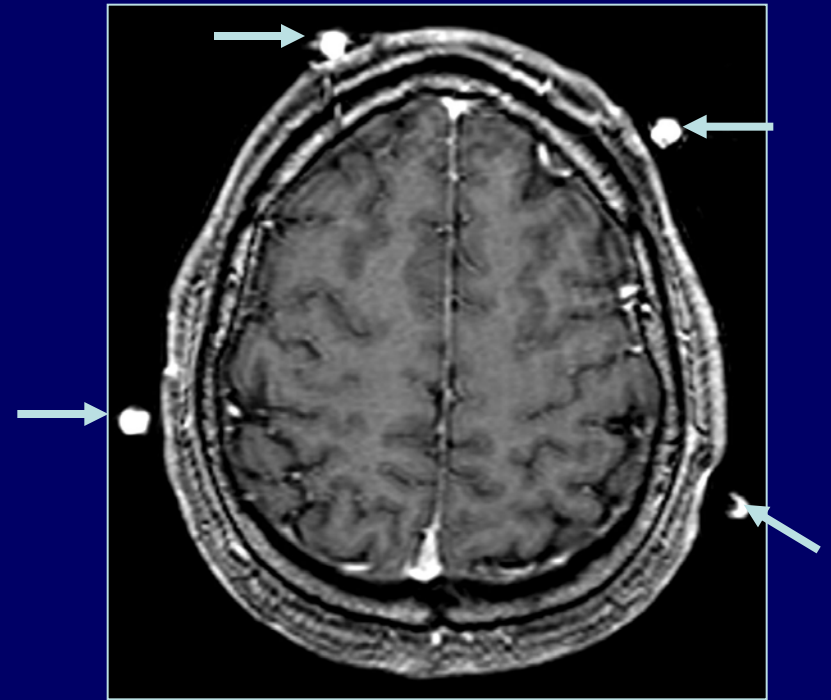
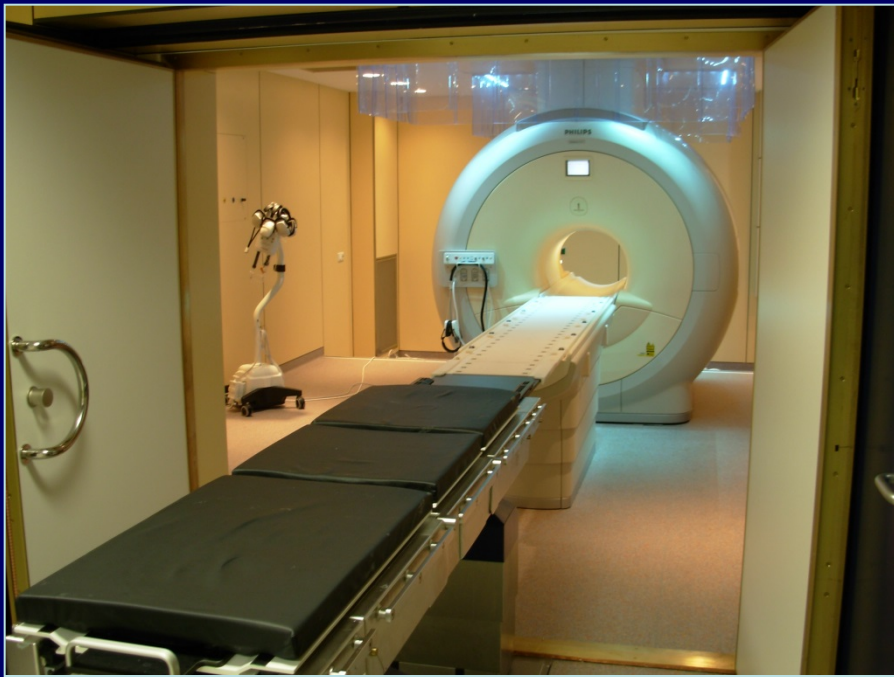09/2009



10/2010

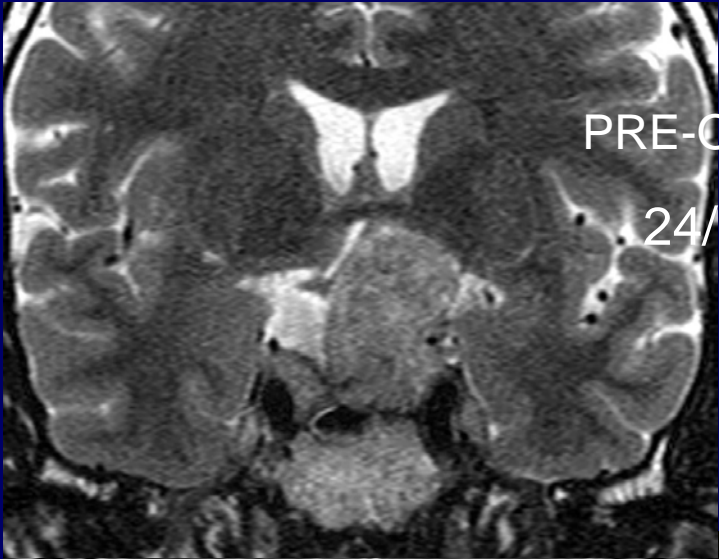






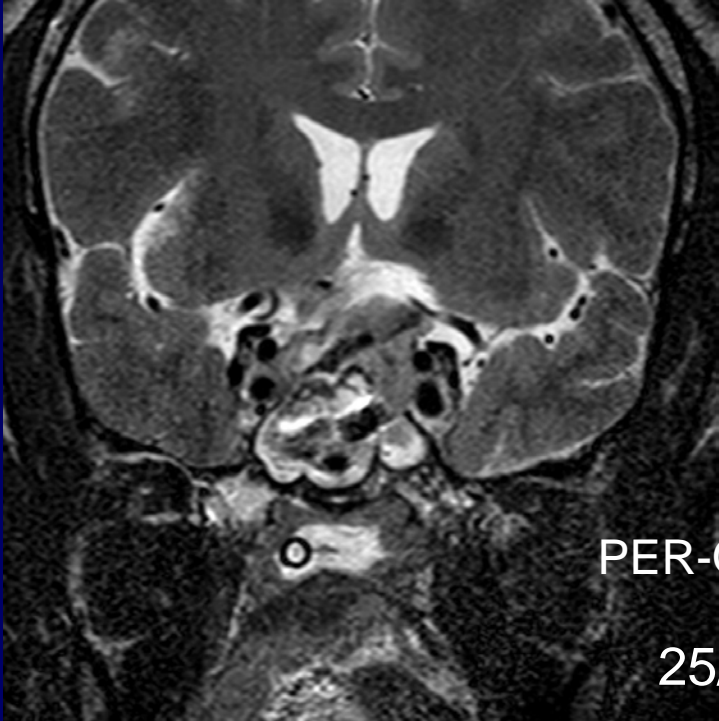
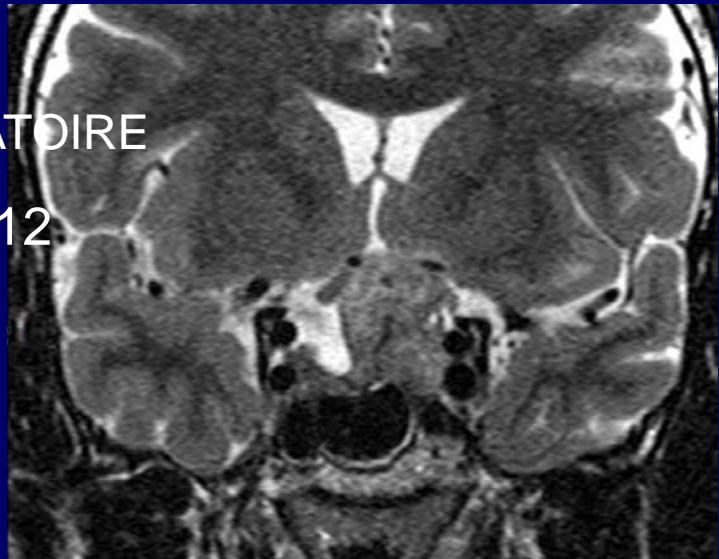MPRs

24/04/2012



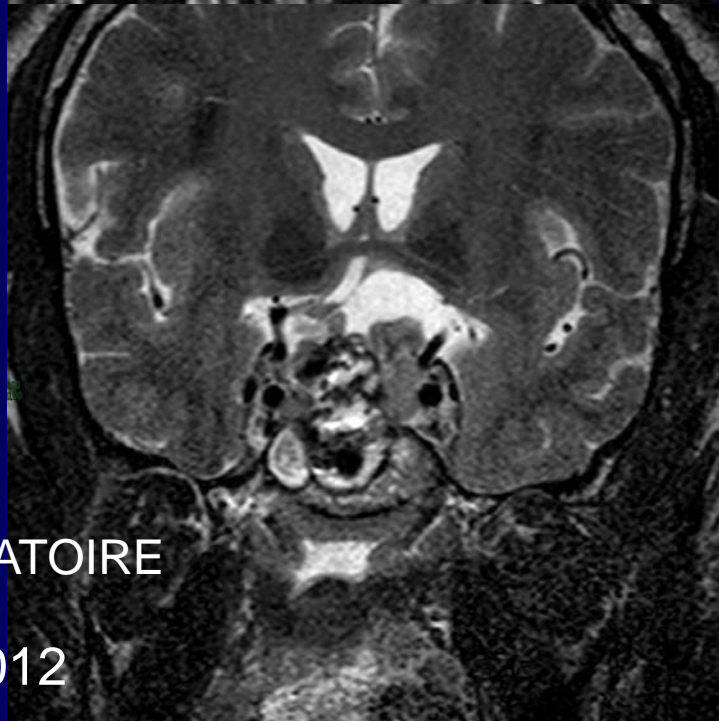
PRE-OPERATOIRE

24/04/2012

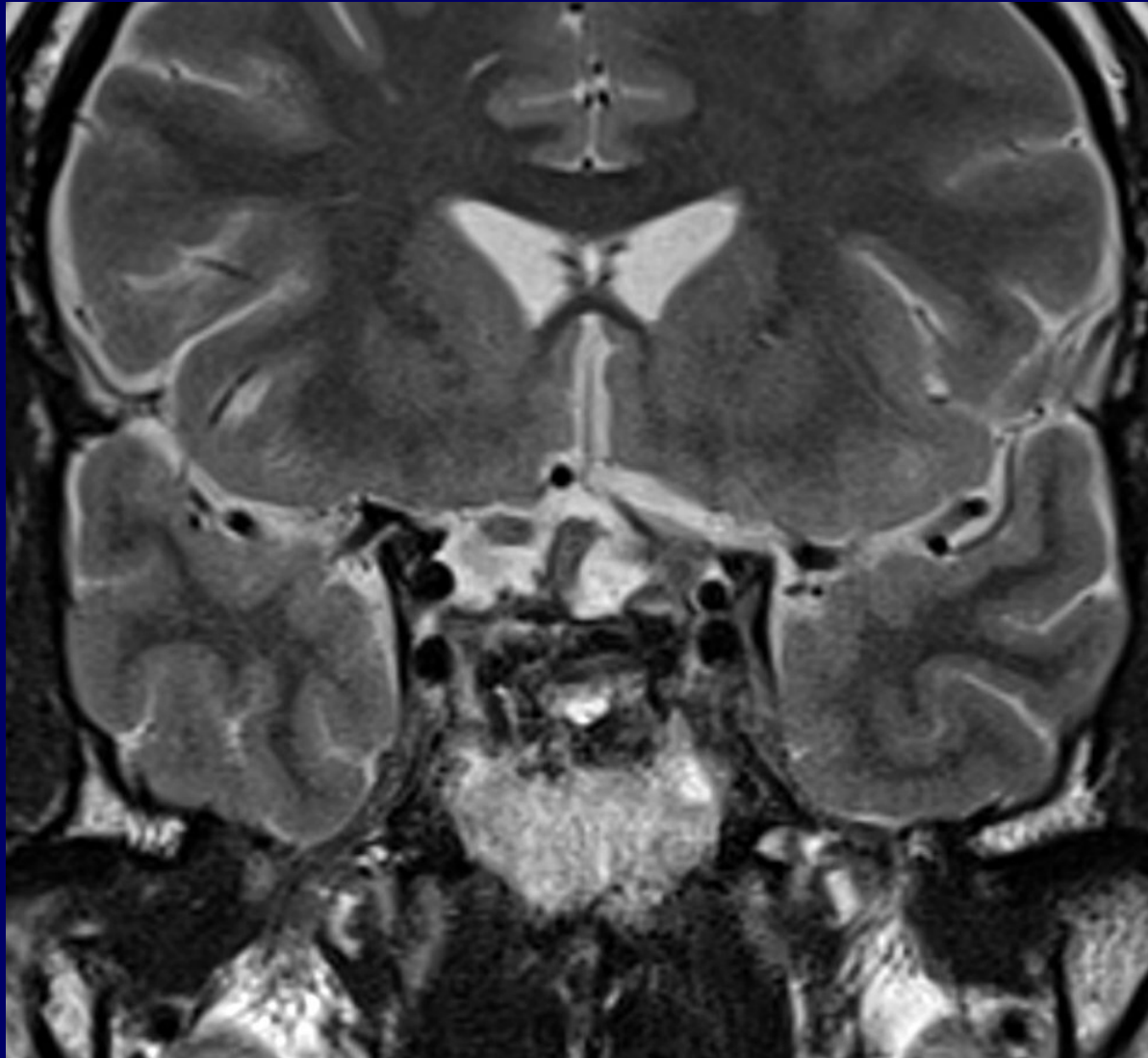


PER-OPERATOIRE

25/04/2012

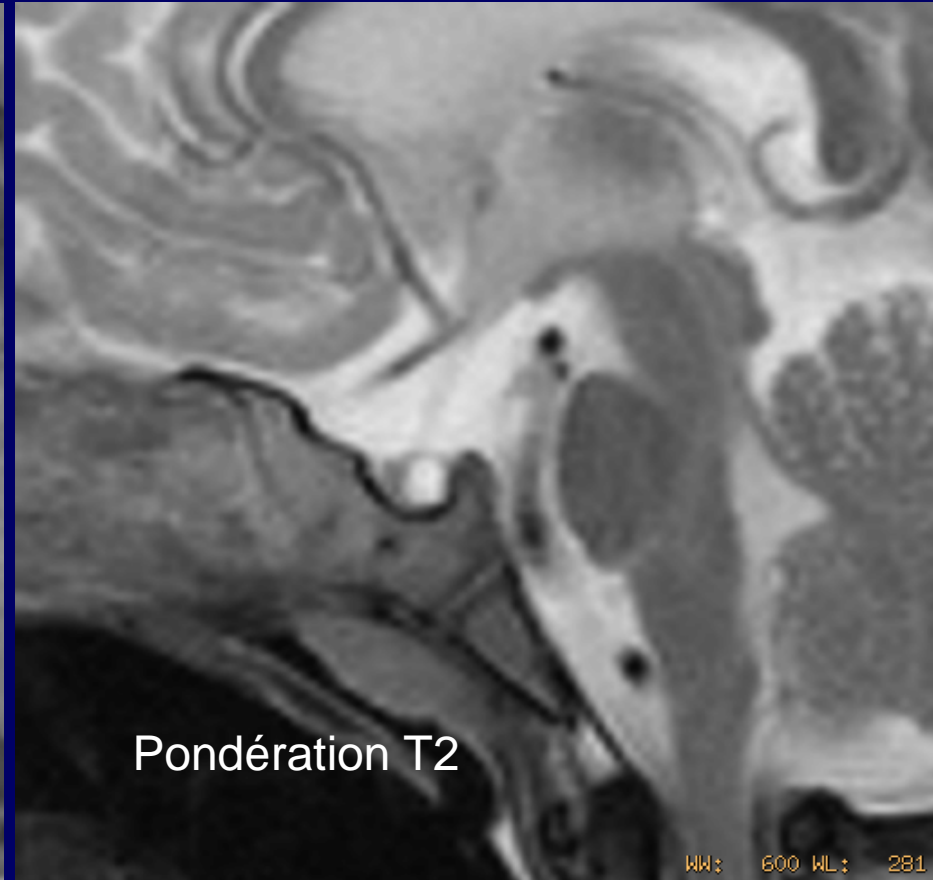
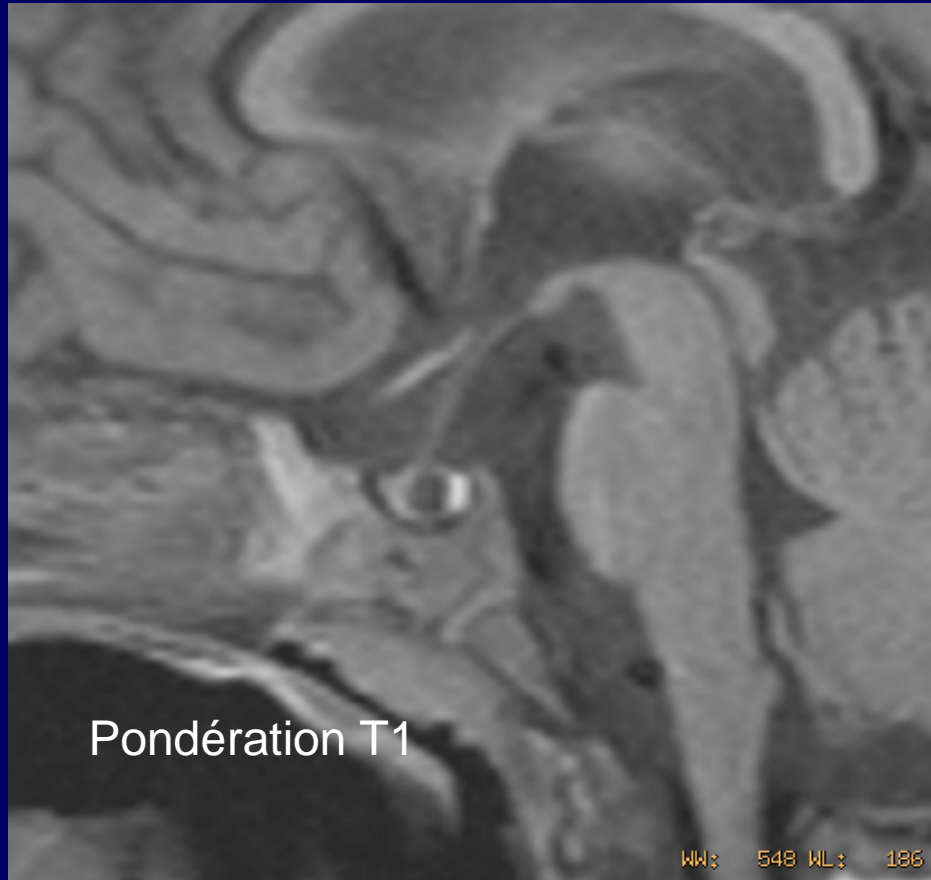

POST-OPERATOIRE

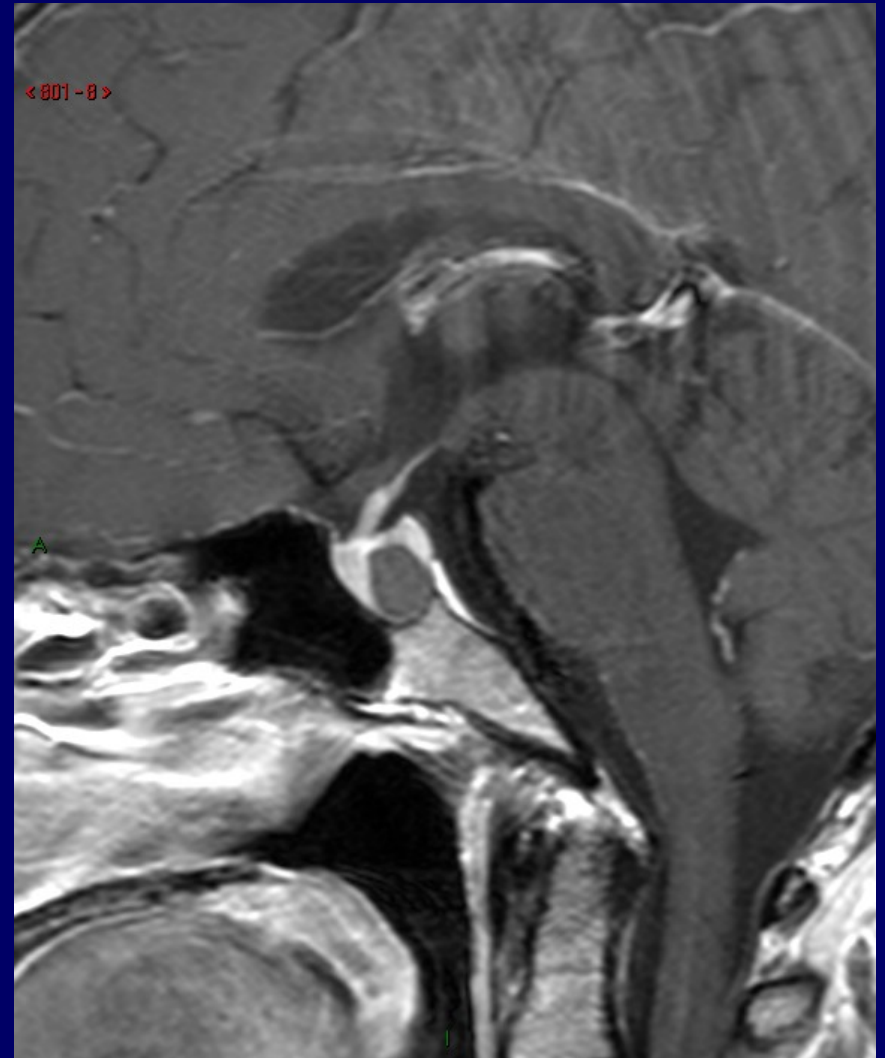
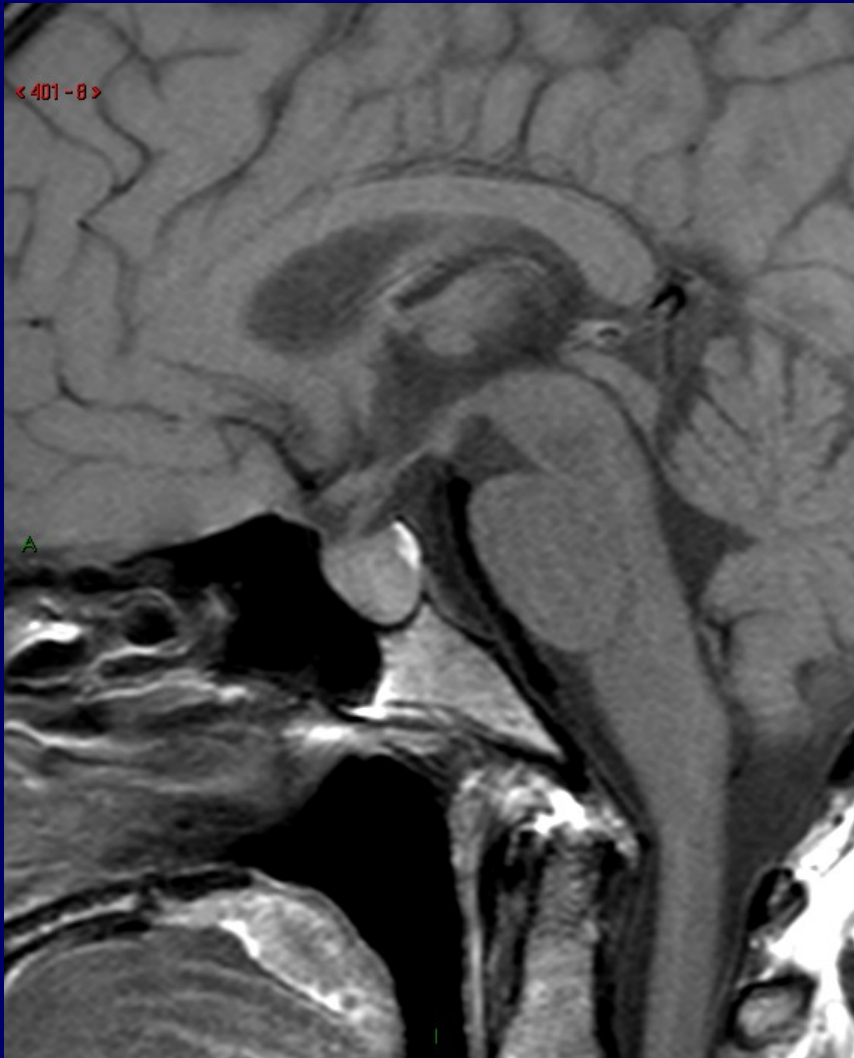


30/04/2012

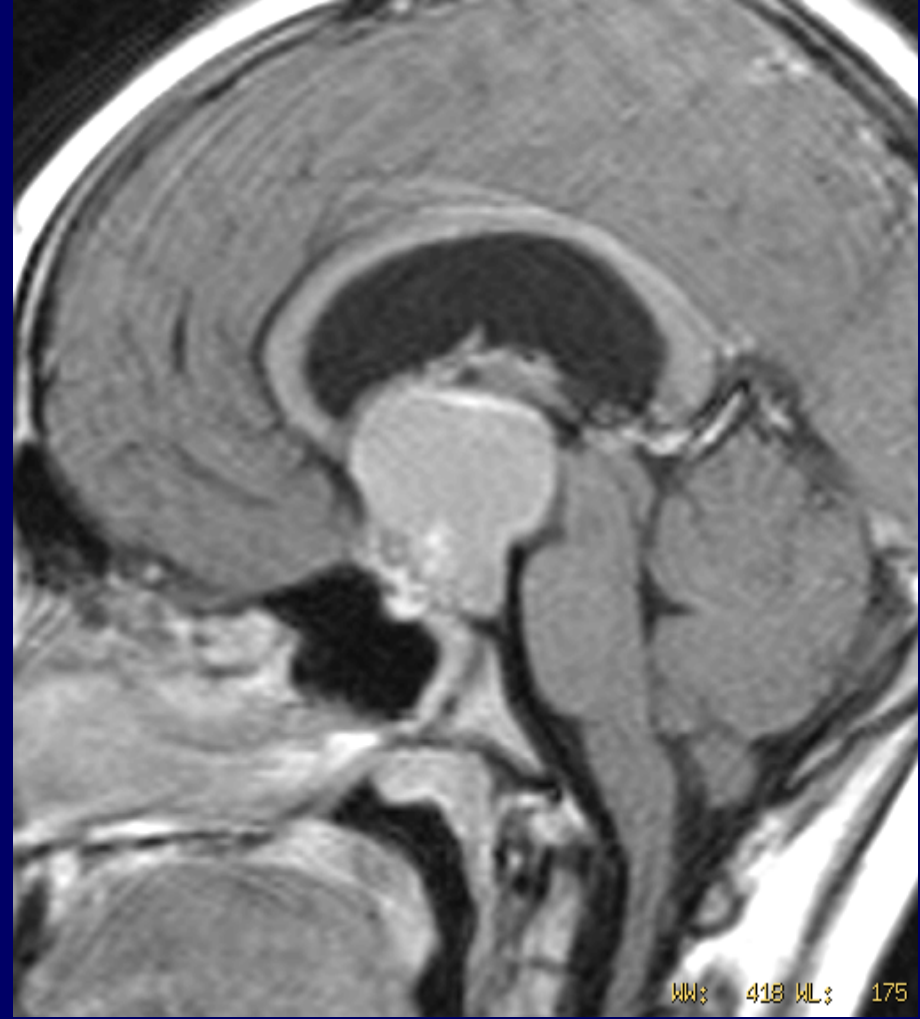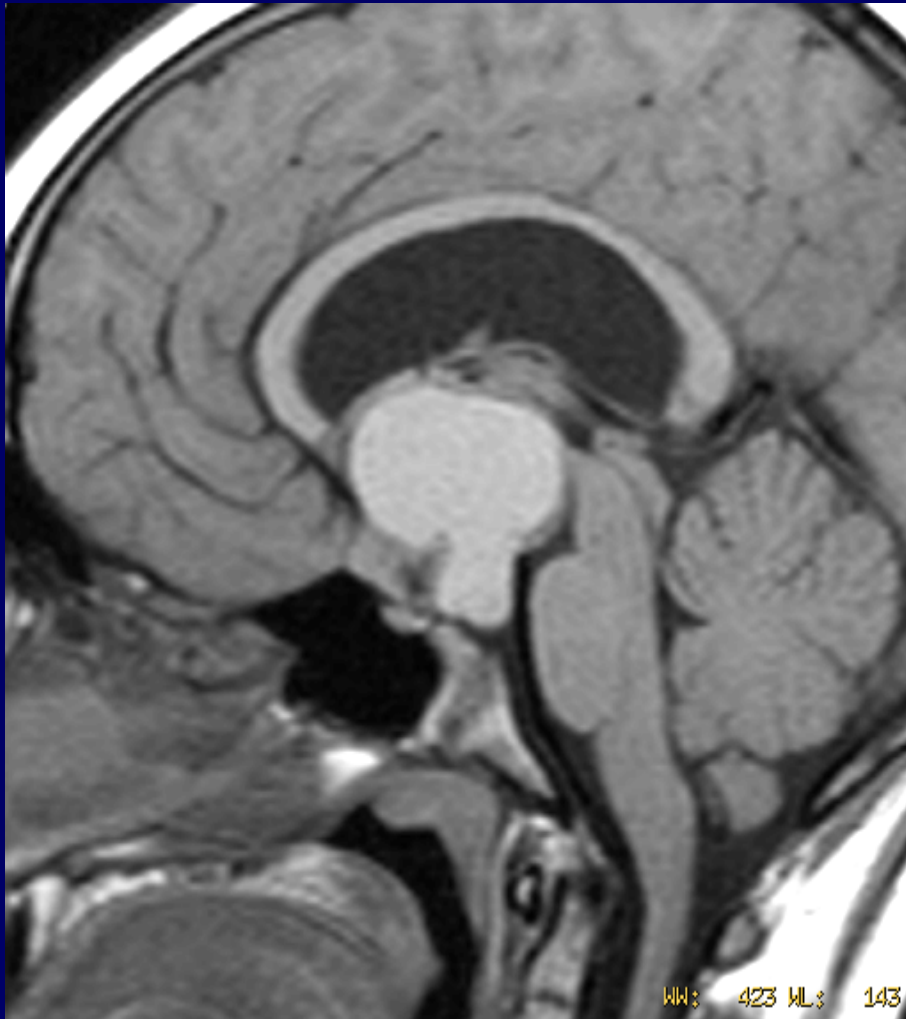
Kyste de la *Pars Intermedia*



Kyste de la poche de Rathke

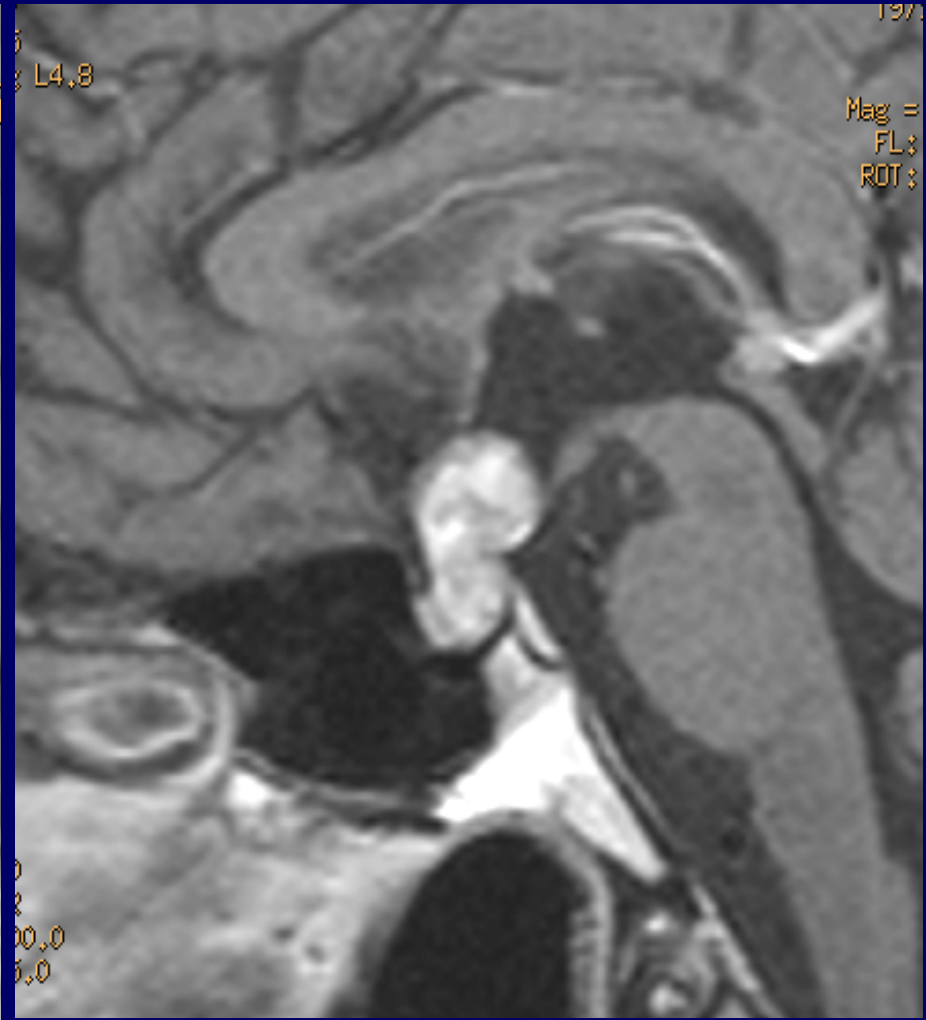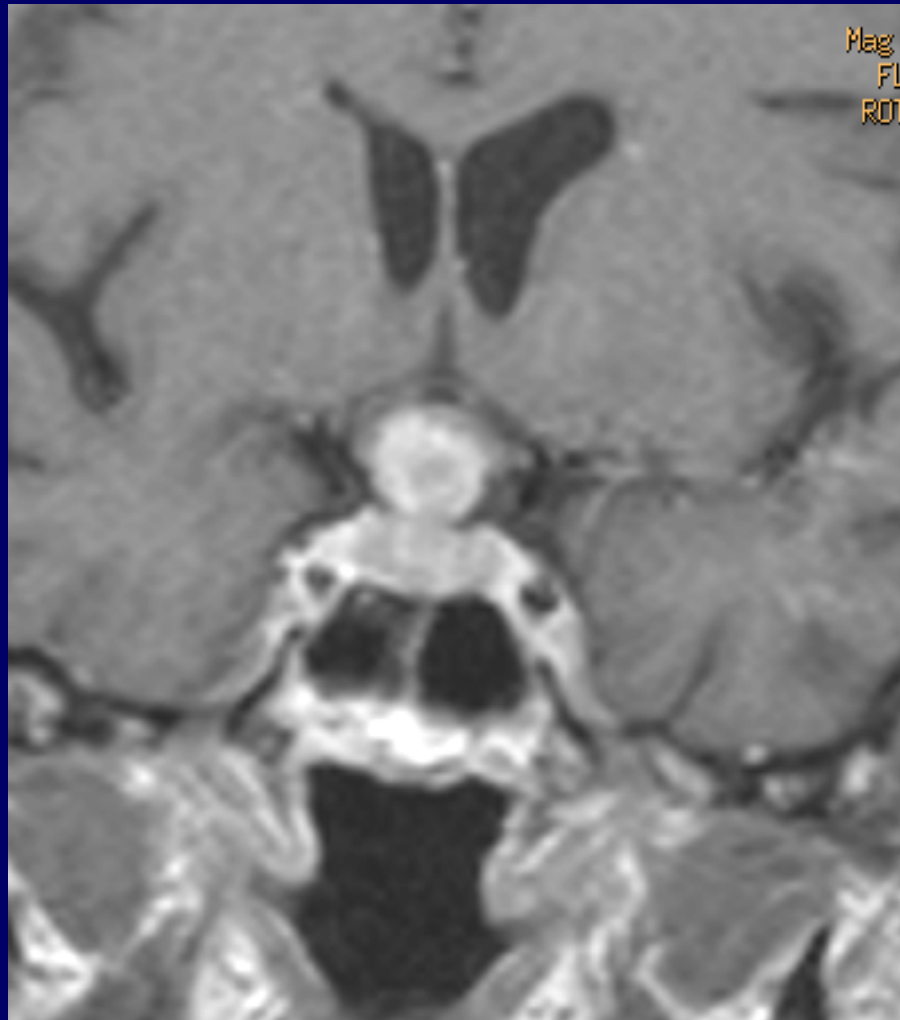


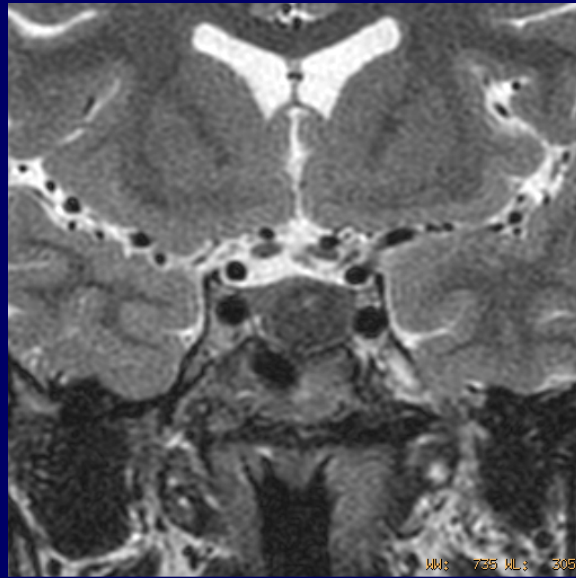
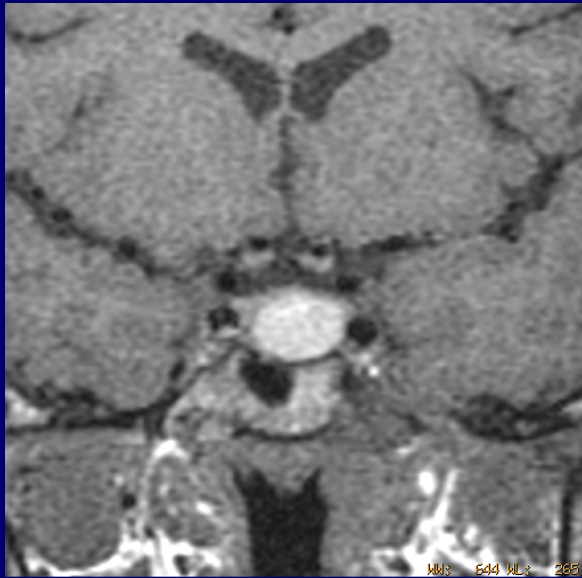
Crâniopharyngiome



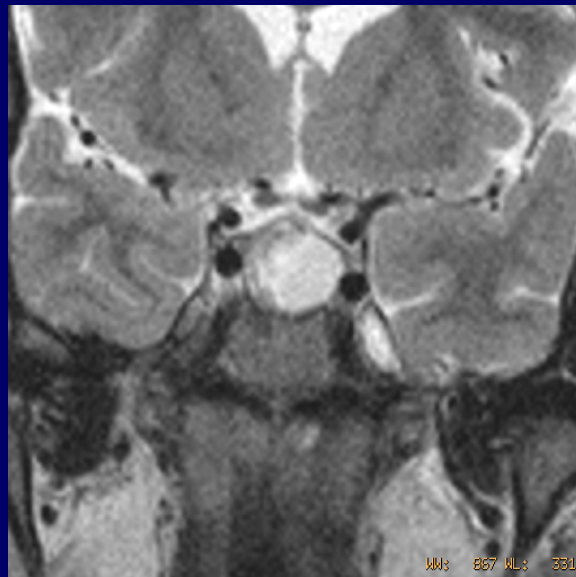
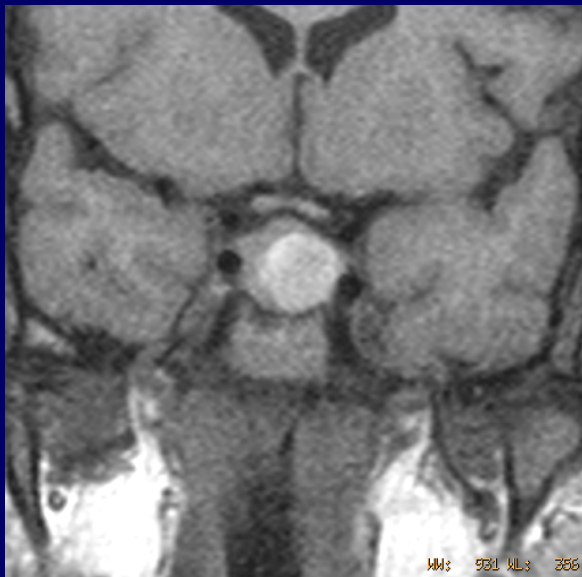
[T] = Ca^{++} en CT scanner

Métastase hypophysaire





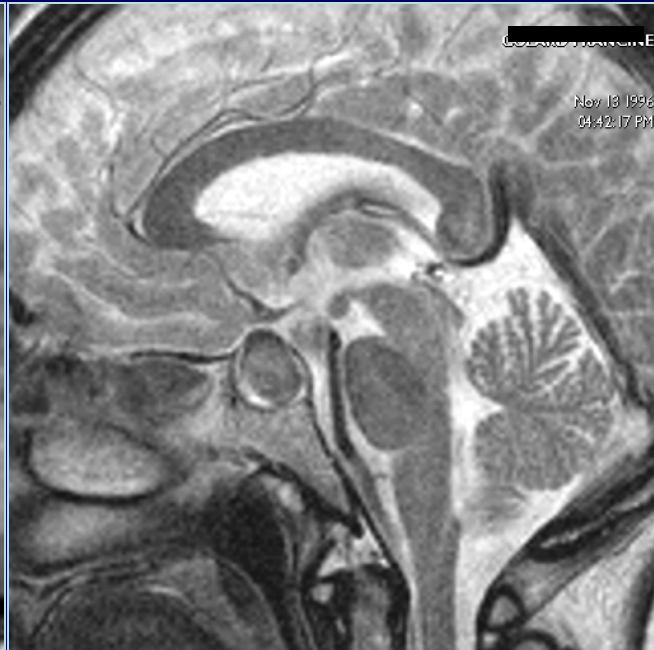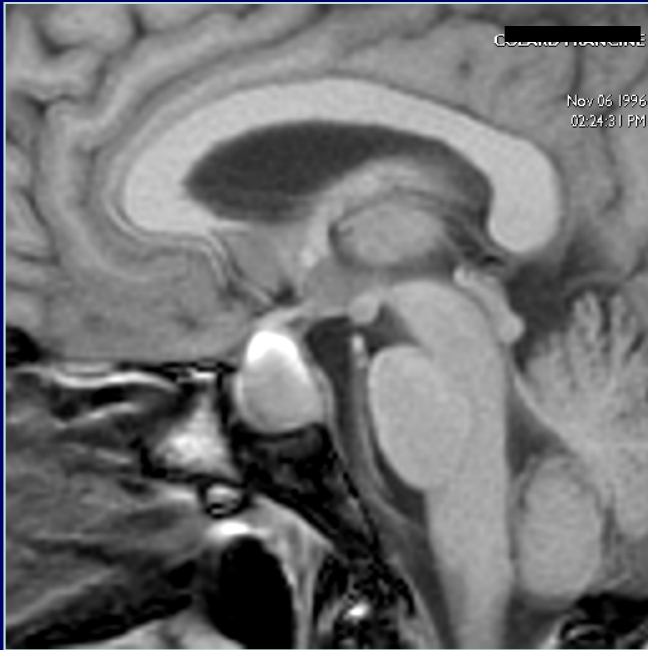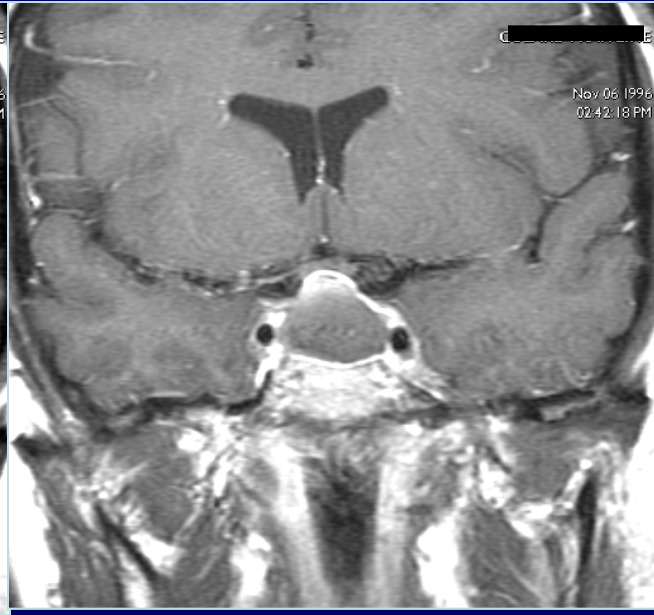
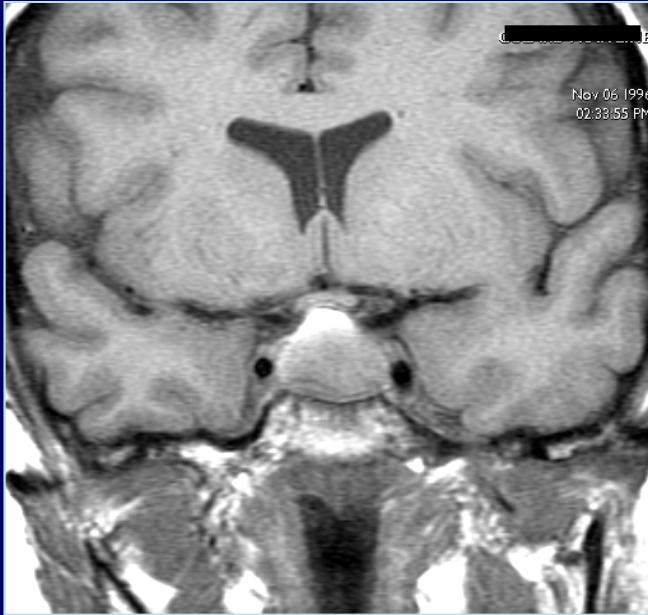
qques jours



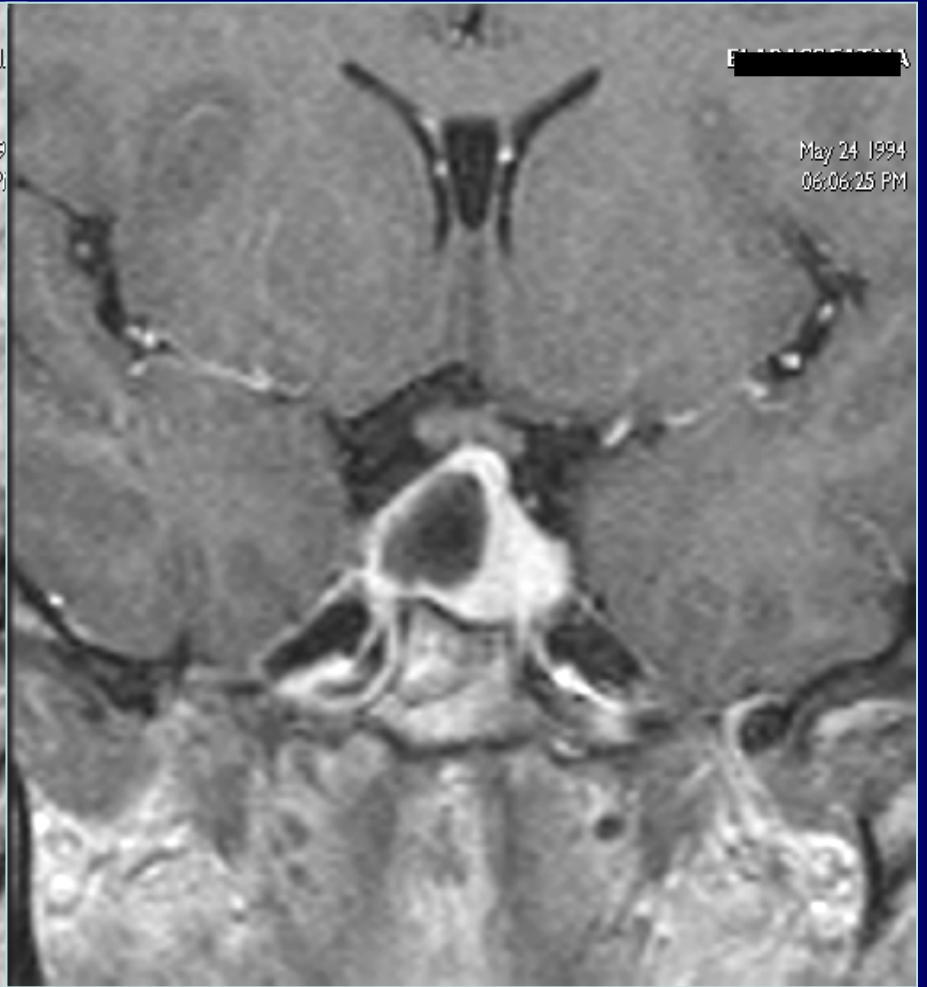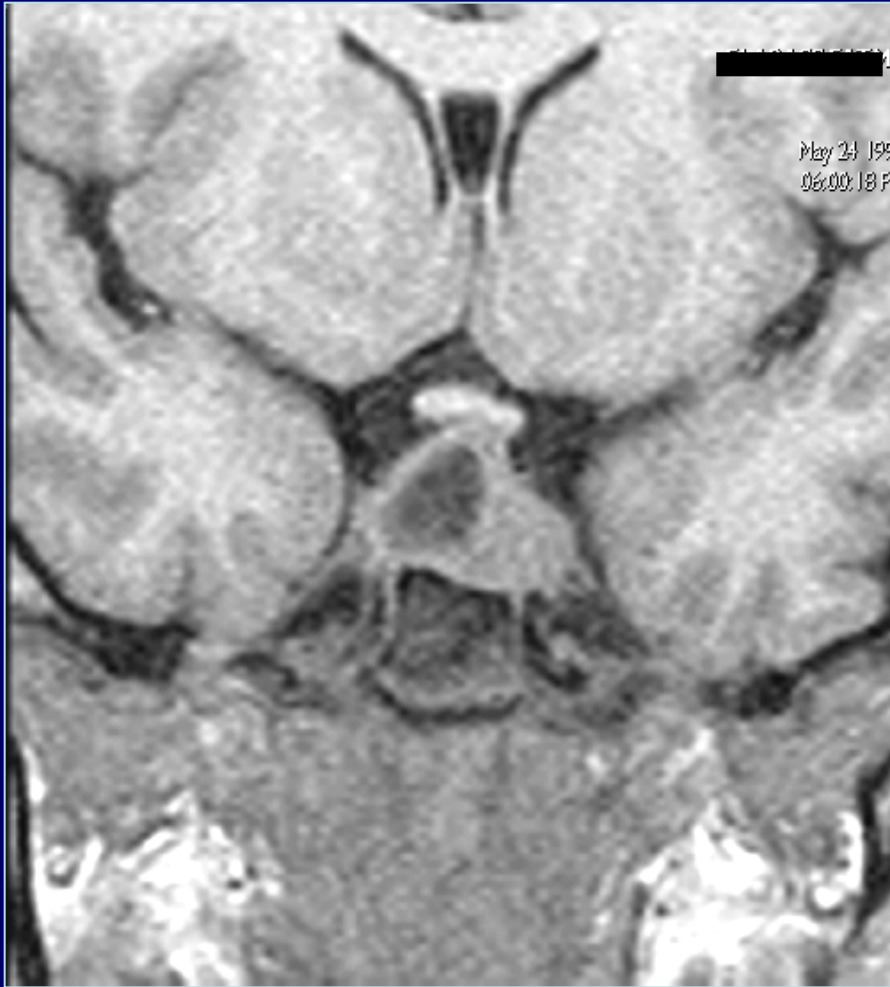> une semaine

Hématome pituitaire

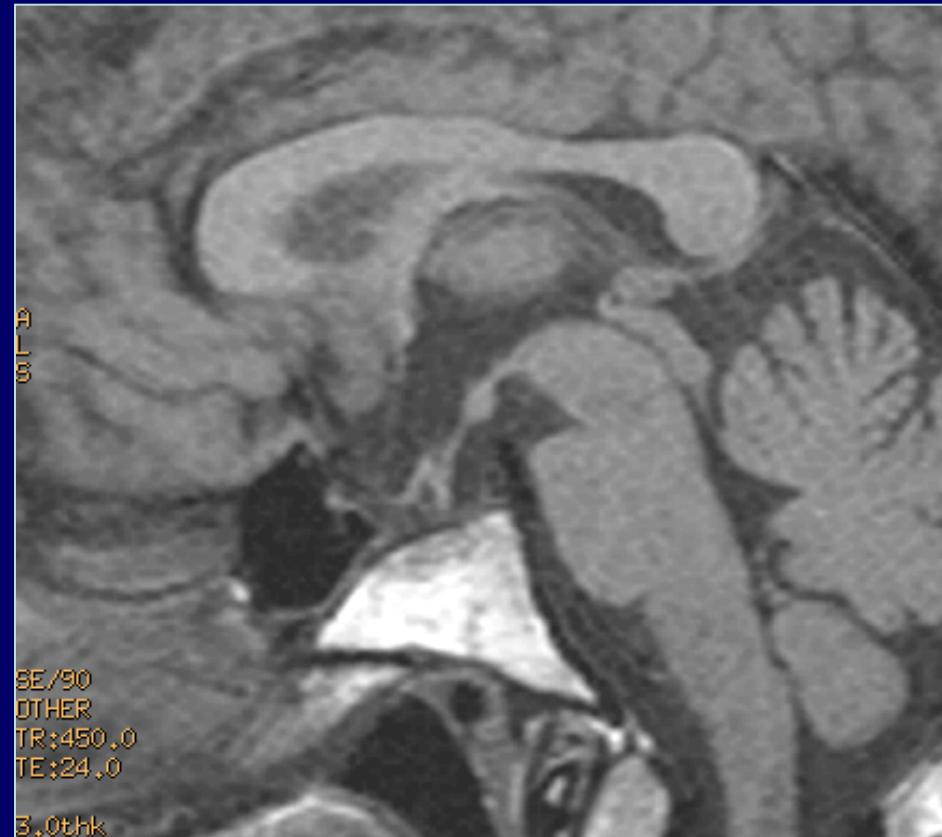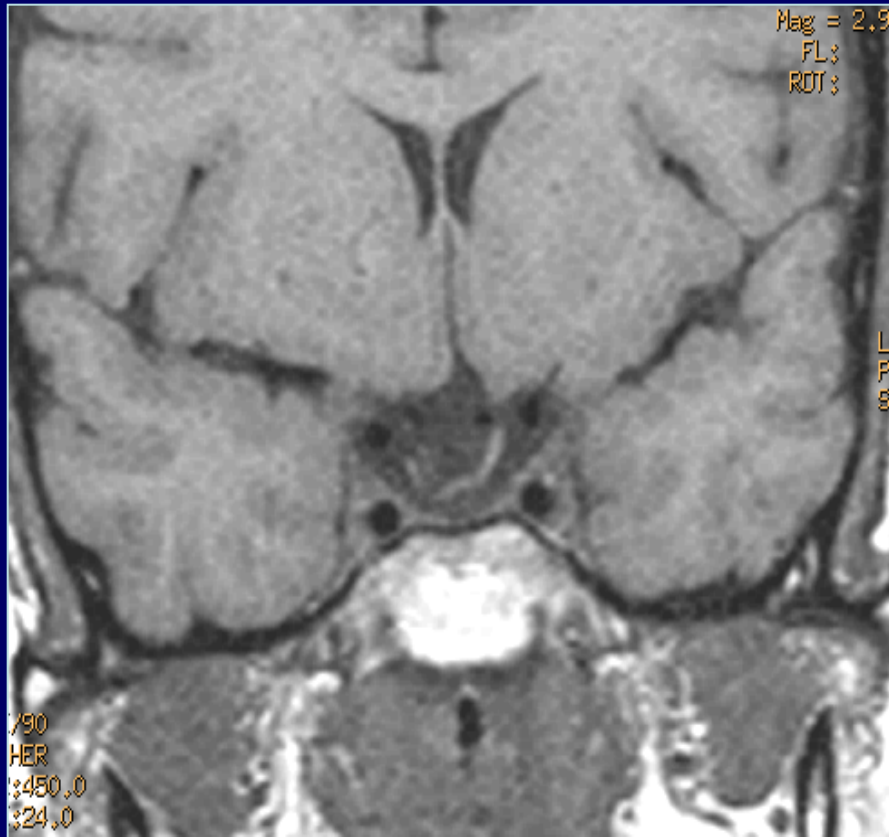Apoplexie pituitaire



Phase aiguë



Hyperplasie de la grossesse



Attraction chiasmatisque

Diabète insipide

D.D. Potomanie

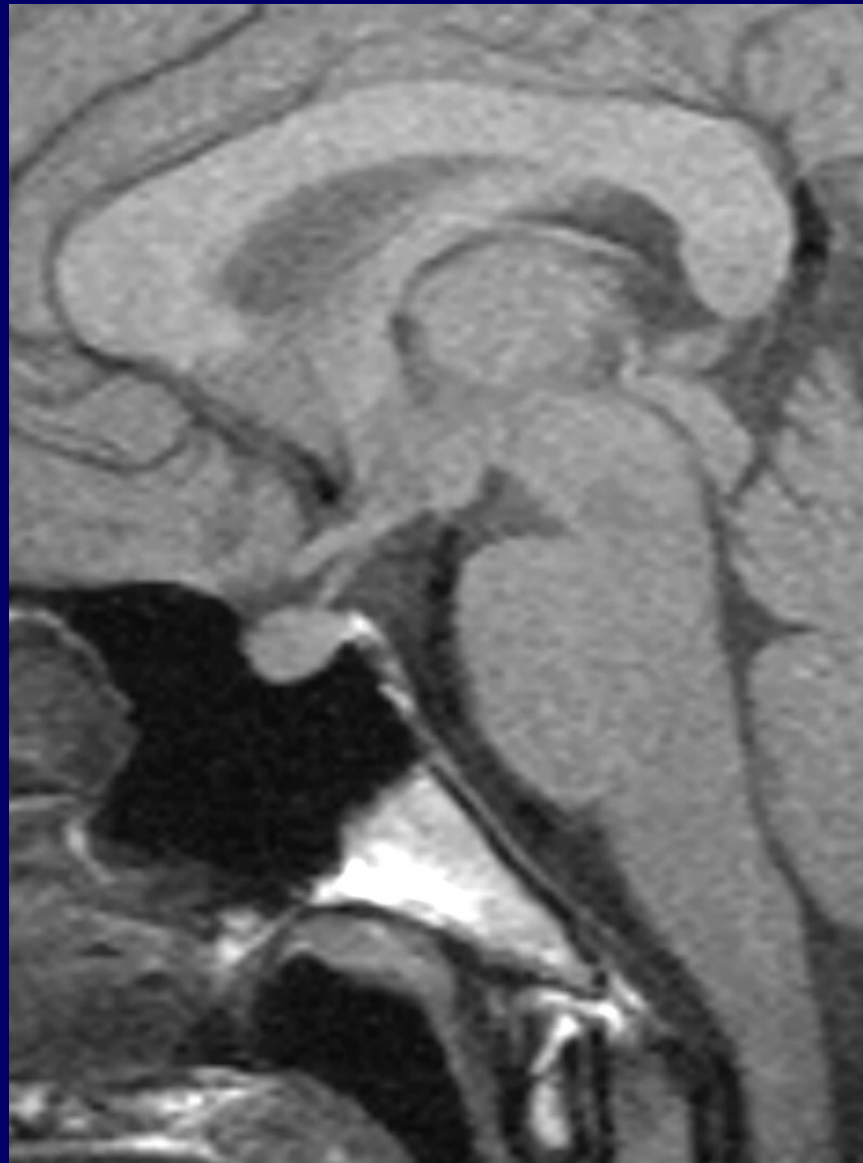
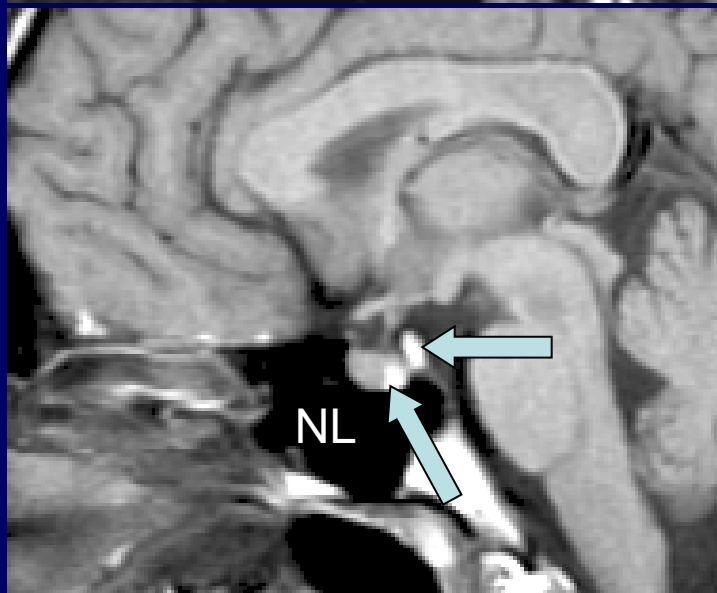
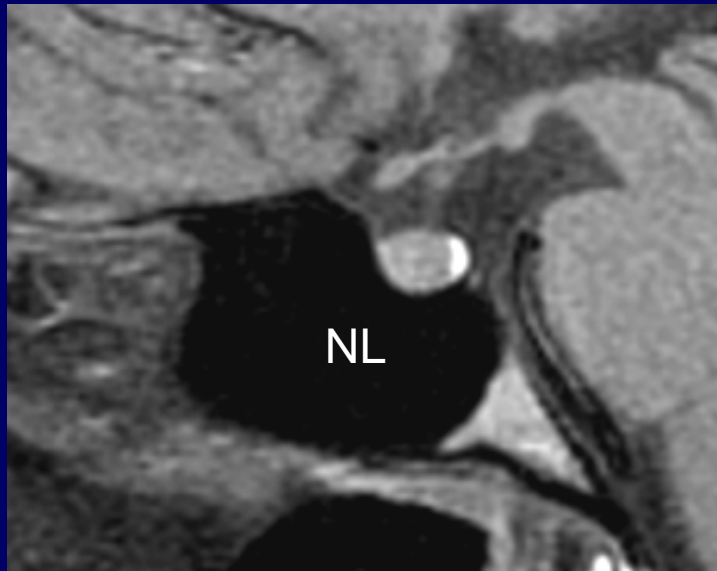Diurèse excédentaire diluée + hémococoncentration secondaire

2 situations:

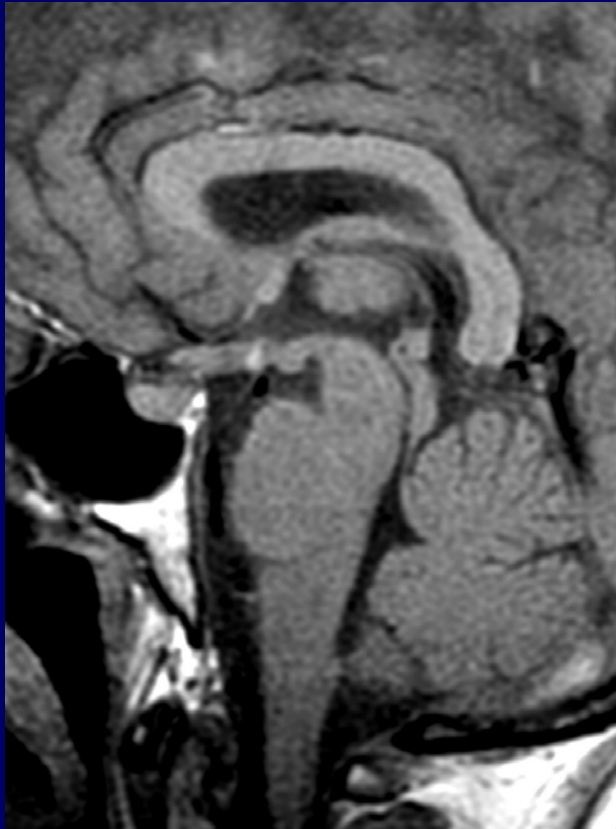
- * **central** : déficit de sécrétion en ADH
- * **périphérique**: résistance à l'ADH

DIC: 1/3 « *idiopathiques* »
2/3 secondaires

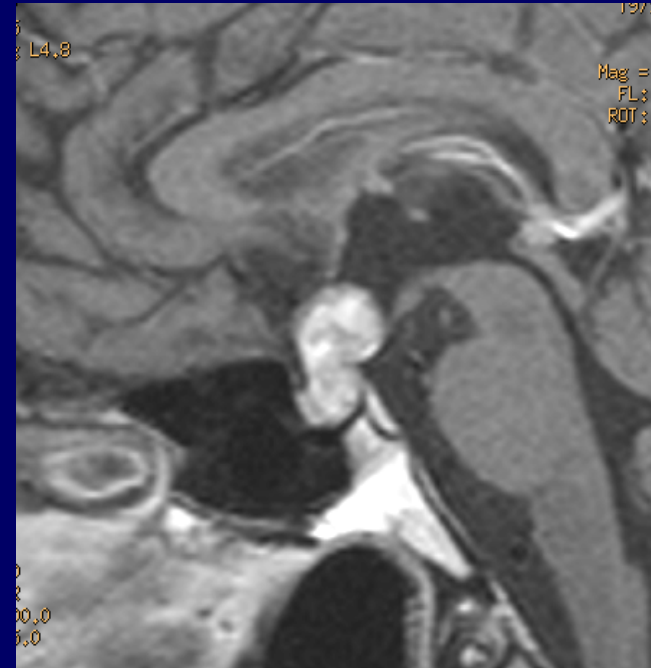
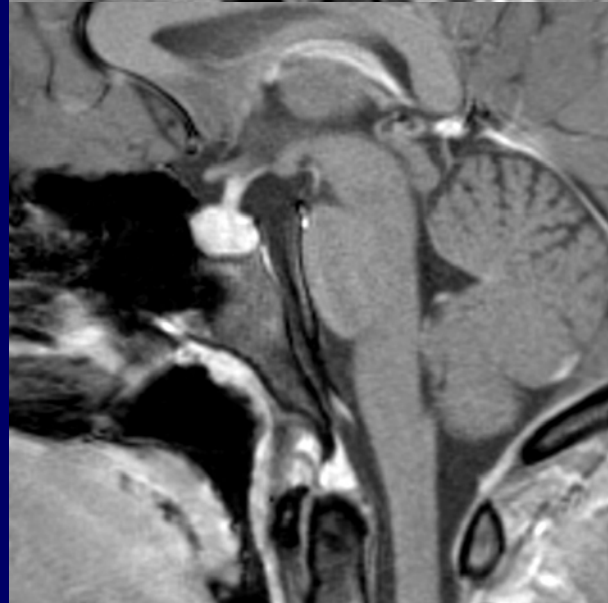
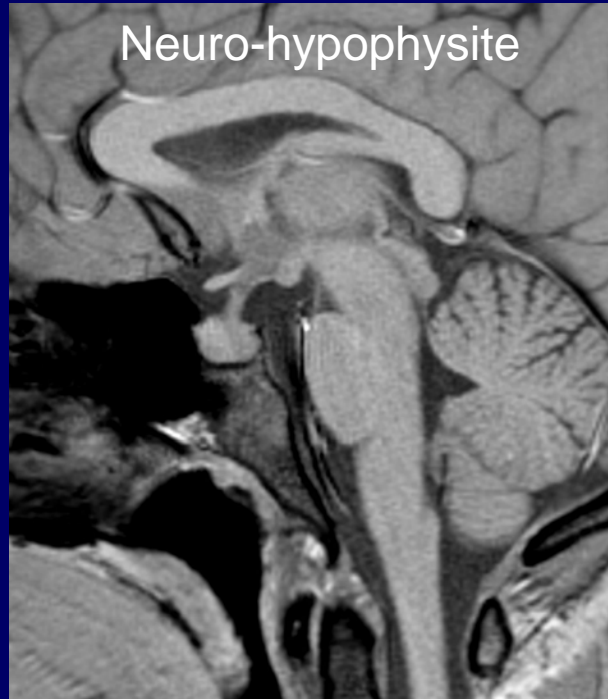
Idiopathique: * tout est normal sauf la neuro-hypophyse
qui perd son **hypersignal T1 spontané**
* cette perte de signal s'observe dans **10 à 15%** des examens
chez sujets normaux



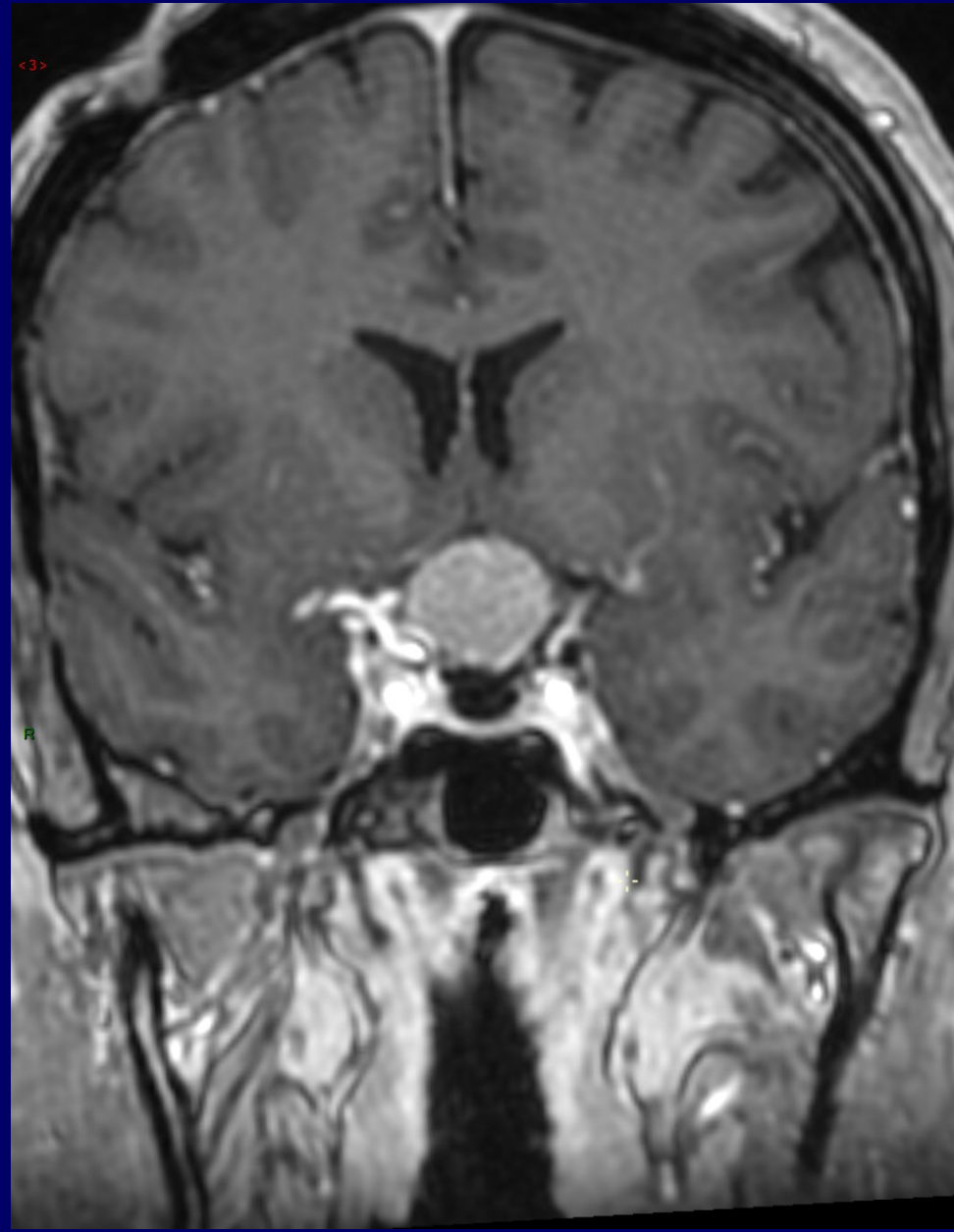
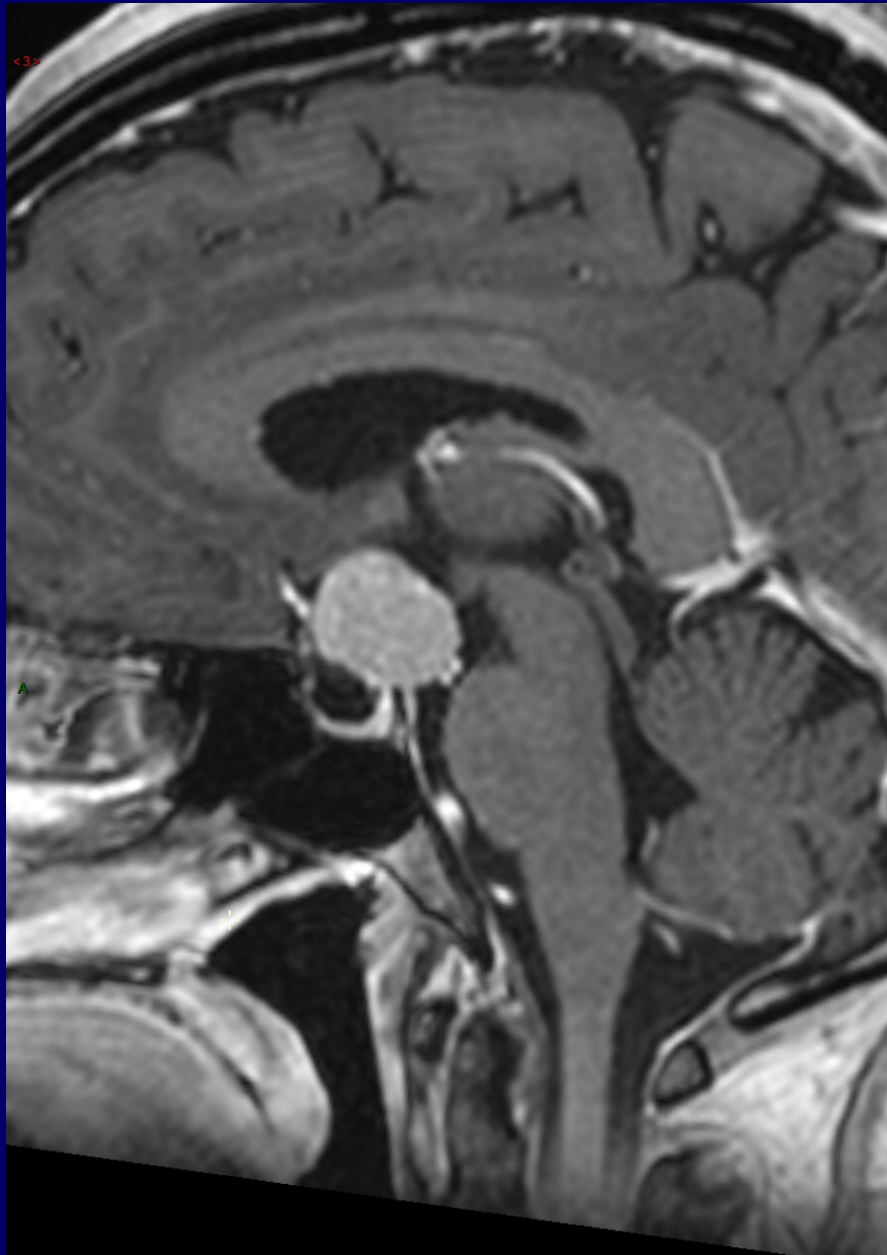
DIC primaire



Ventriculostomie du V3

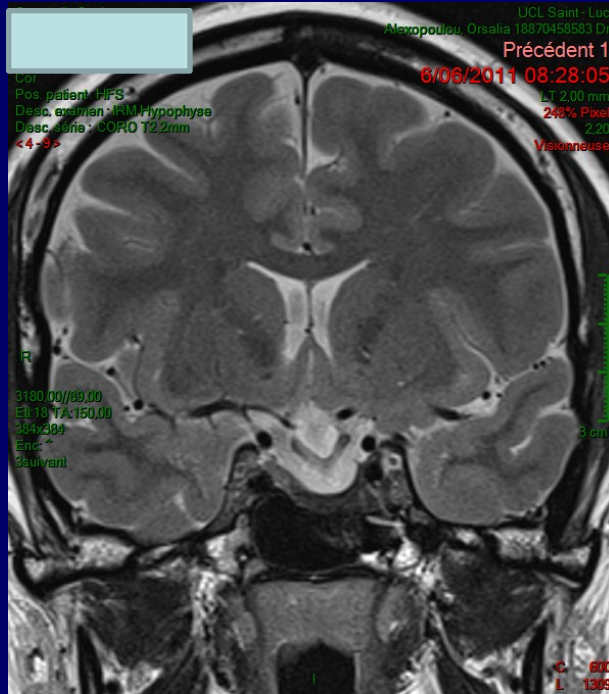


Métastase pituitaire

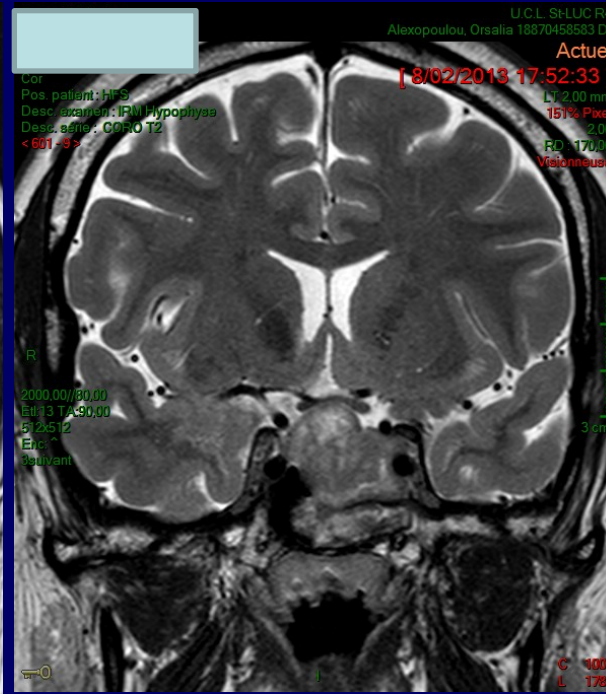


'Choristome': tumeur à cellules granulaires

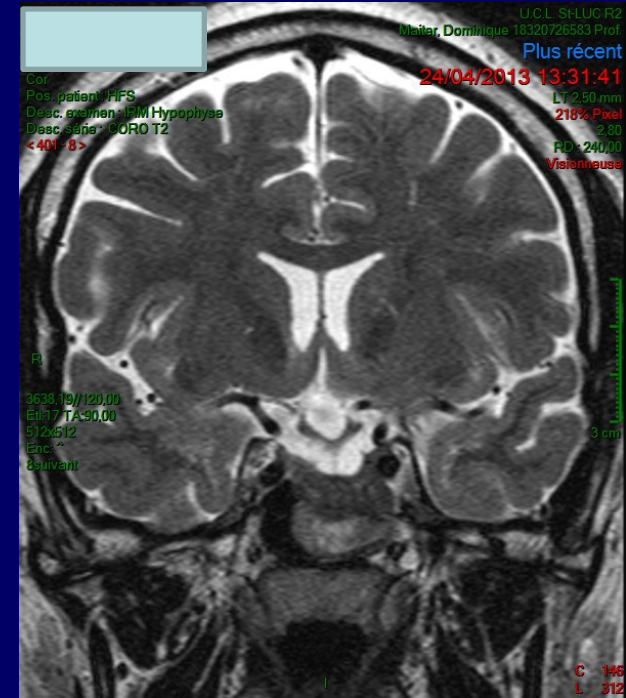
QUIZZ : CAS 1



06.2011



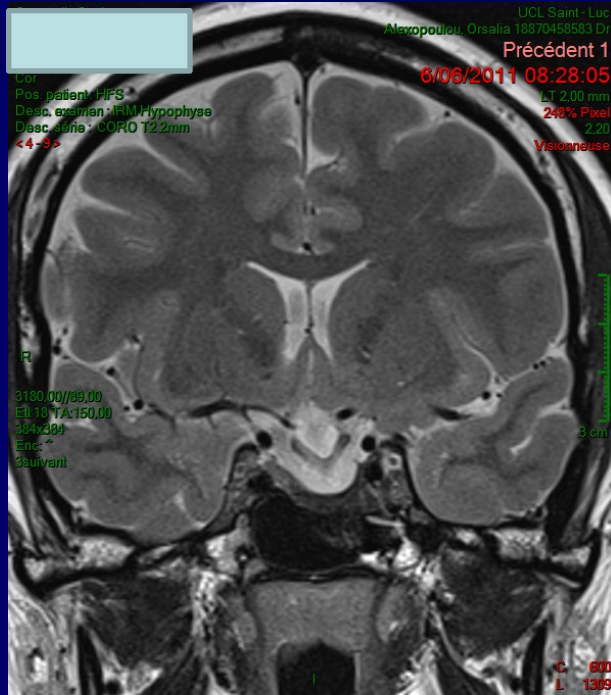
02.2013



04.2013

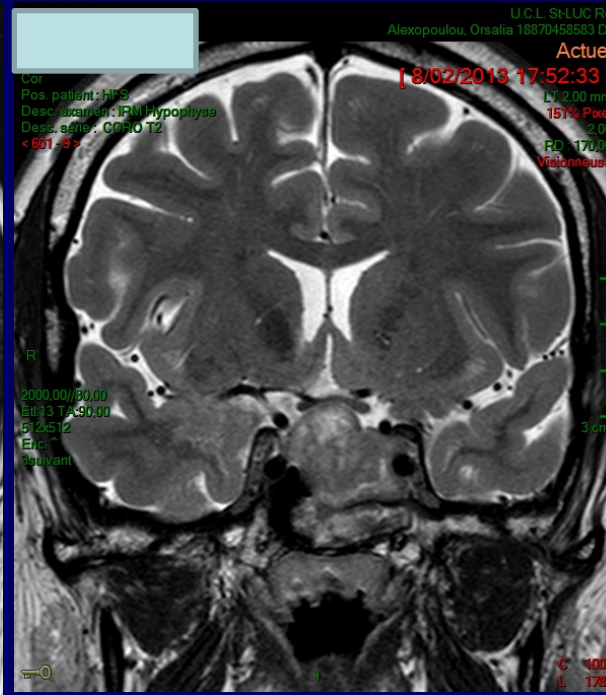
Que s'est-il passé ?

QUIZZ : CAS 1



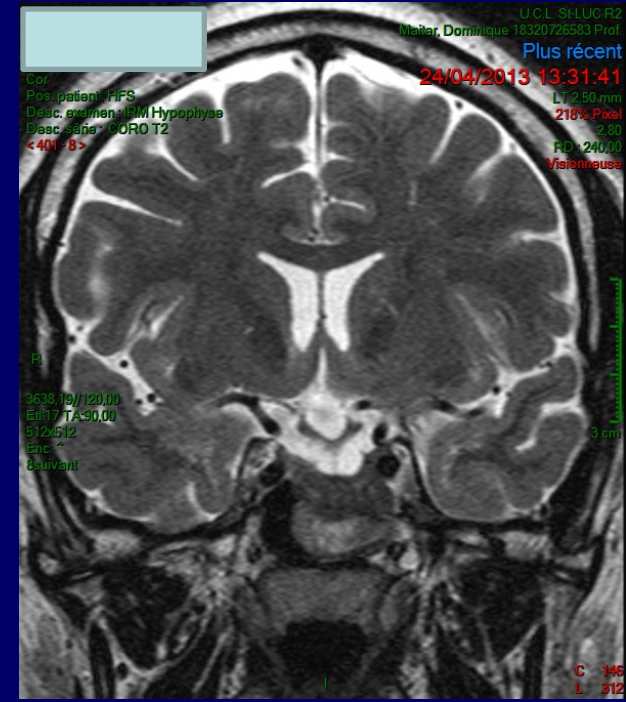
06.2011

Que s'est-il passé ?



02.2013

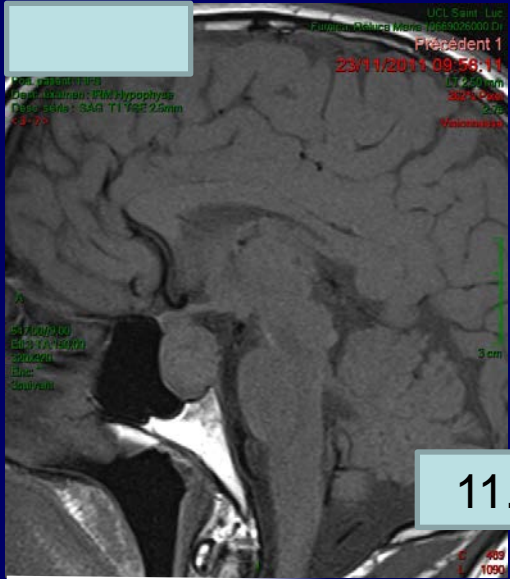
Grossesse



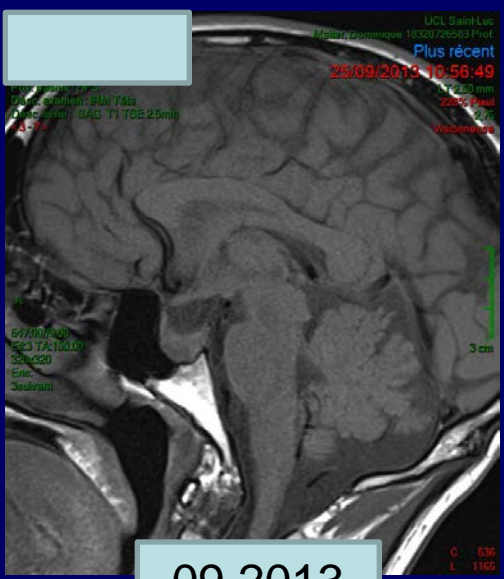
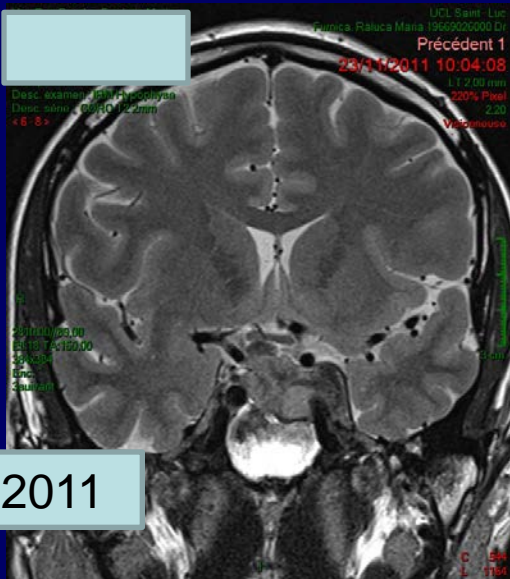
04.2013

Accouchement

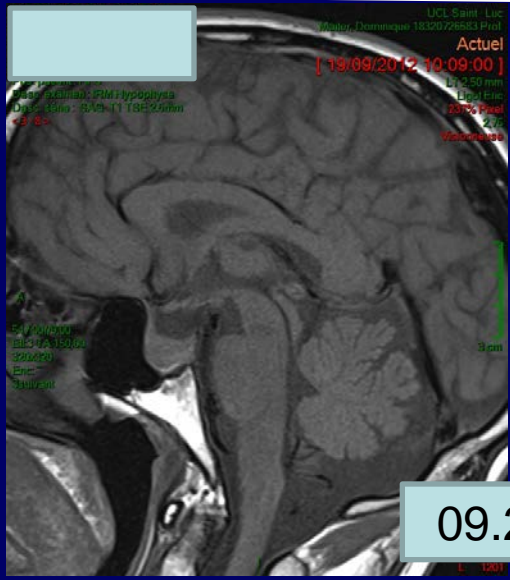
QUIZZ : CAS 2



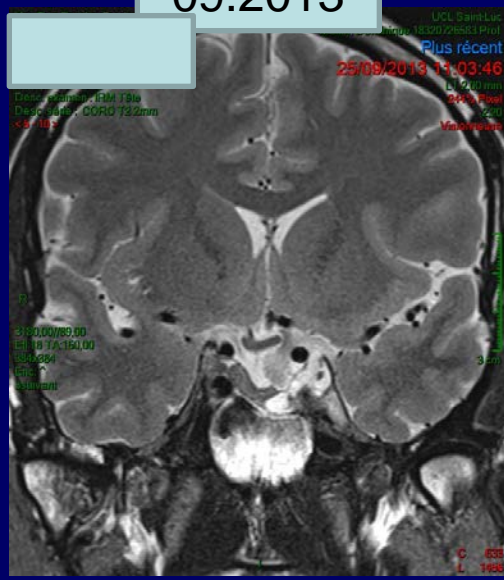
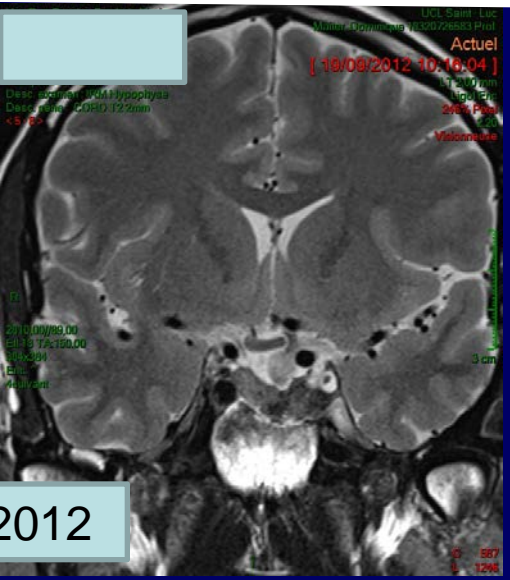11.2011



09.2013

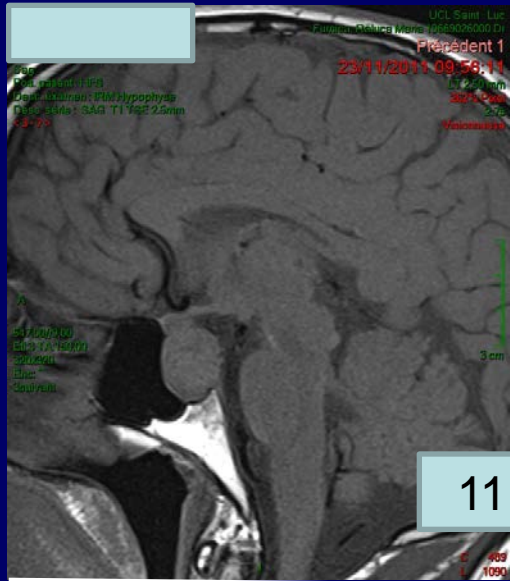


09.2012

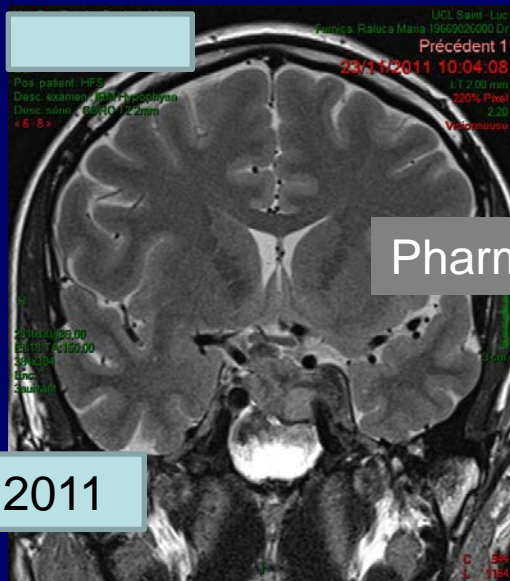


Que s'est-il passé ?

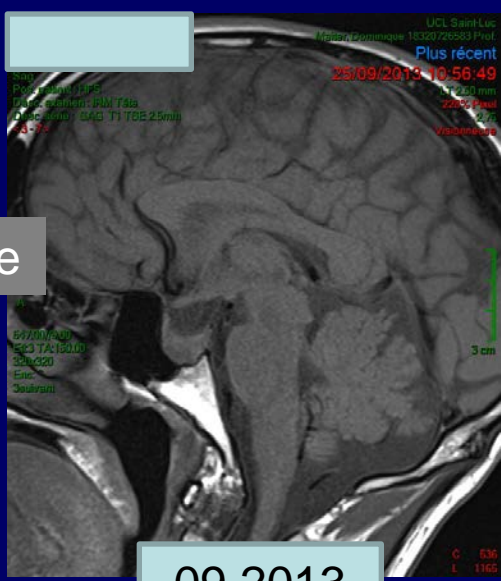
QUIZZ : CAS 2



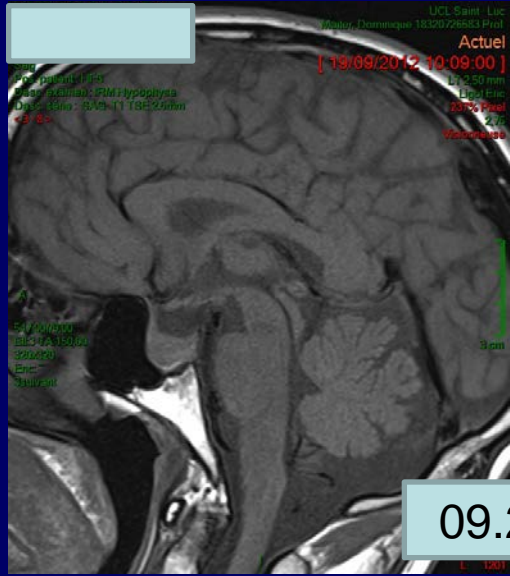
11.2011



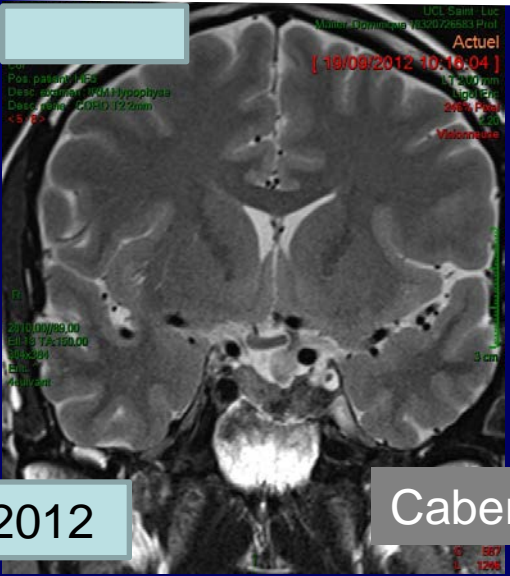
Pharmaco-chirurgie



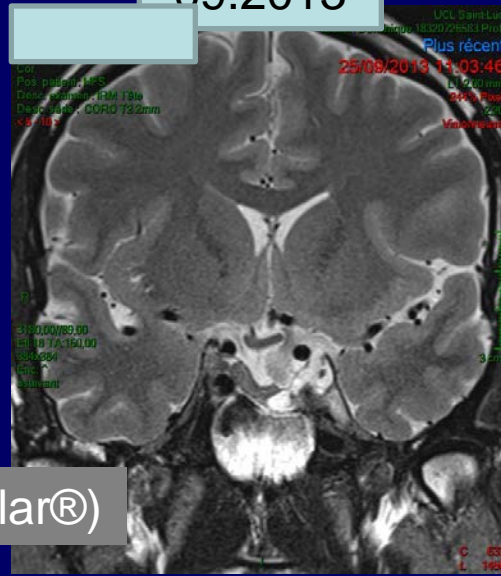
09.2013



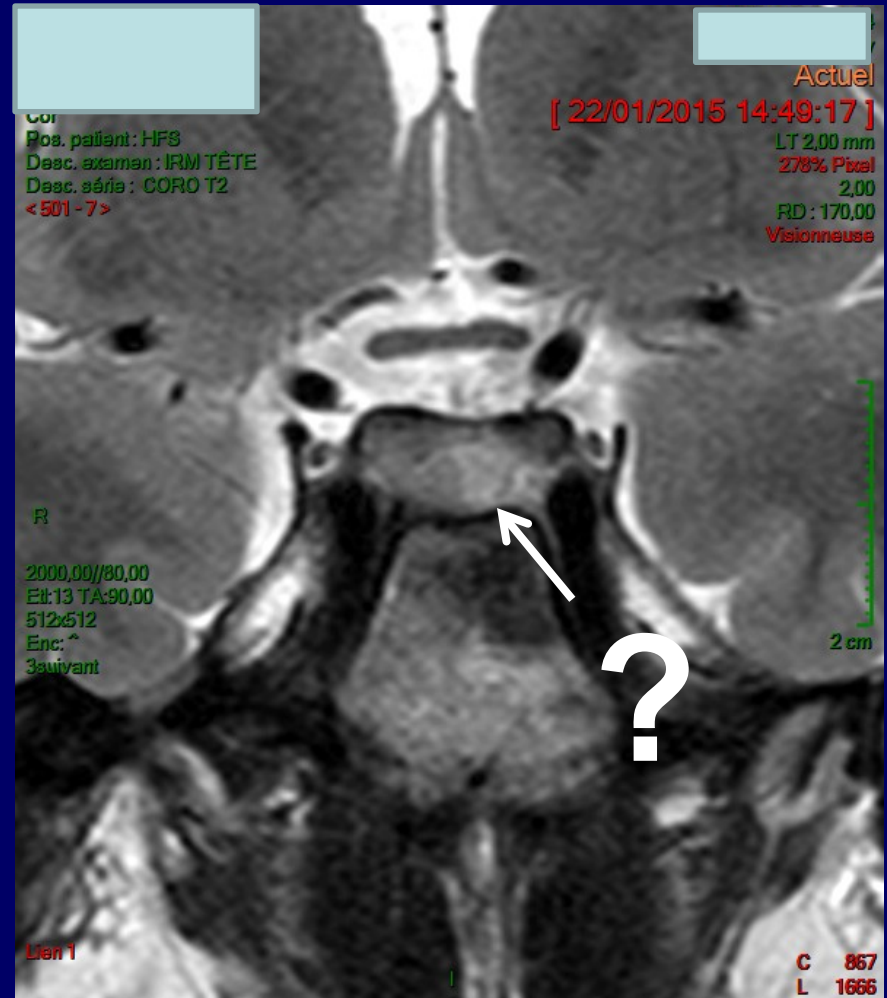
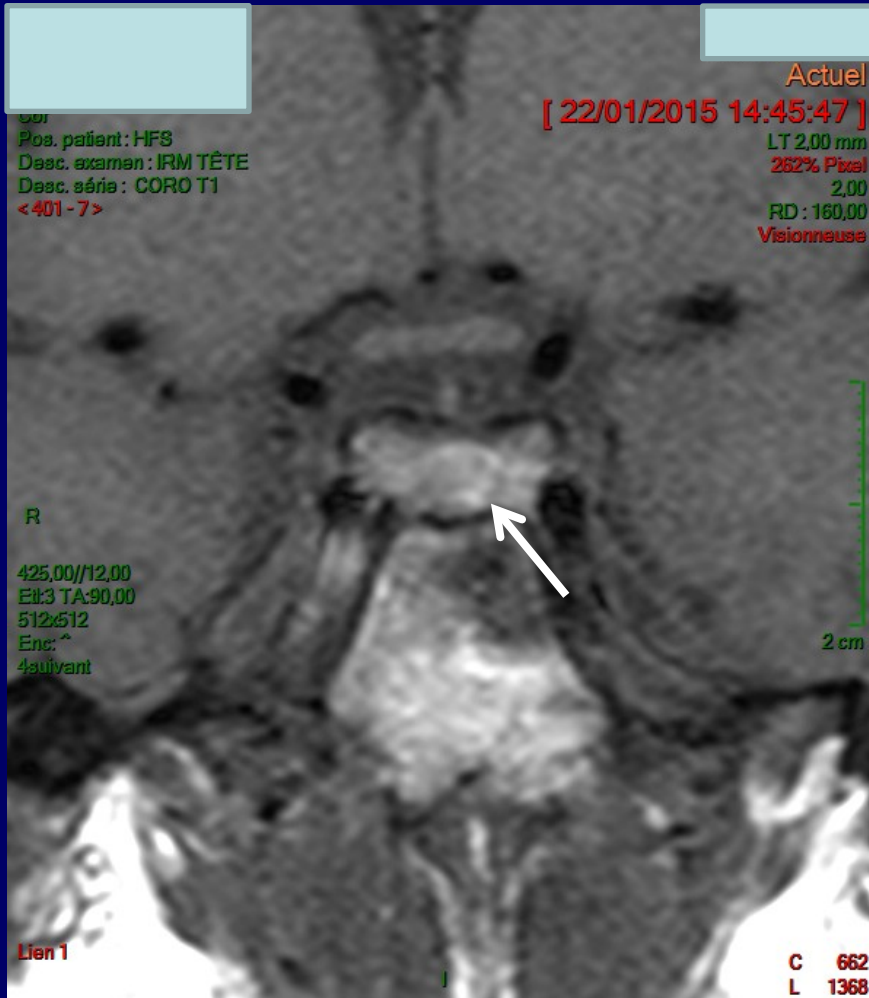
09.2012



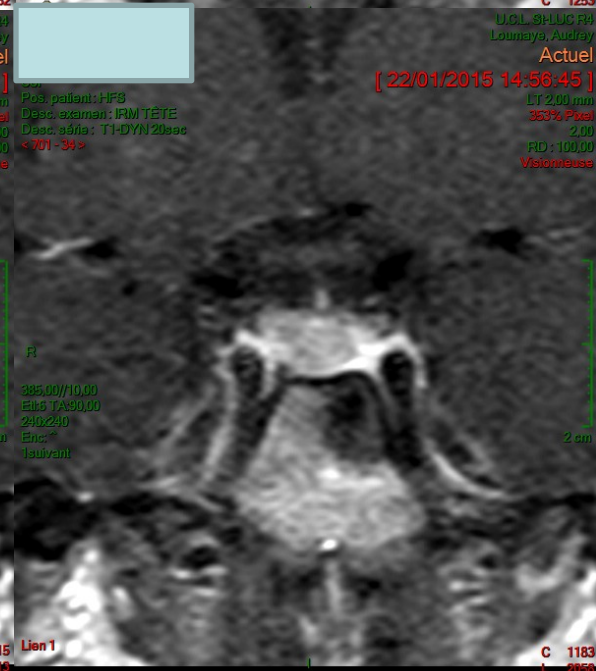
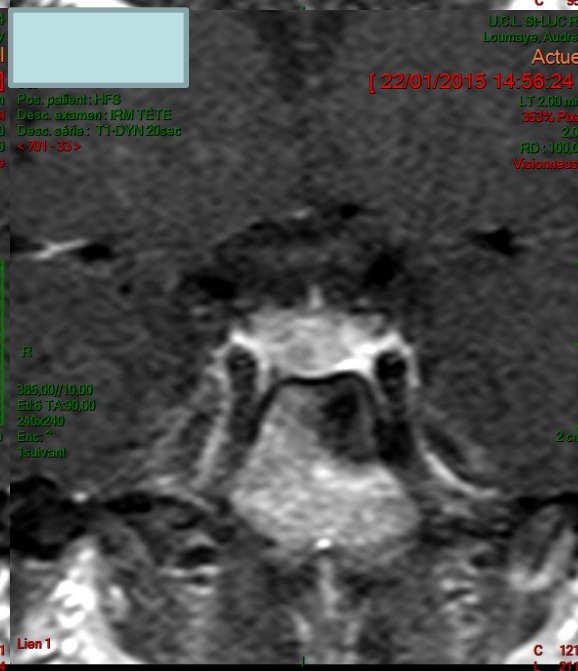
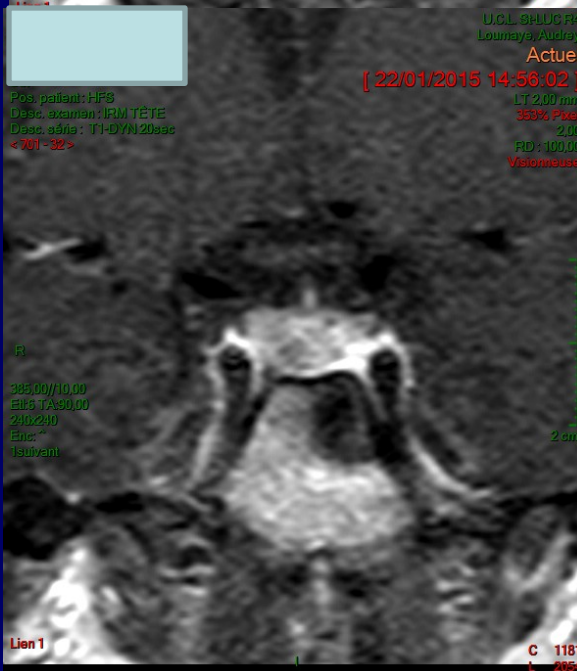
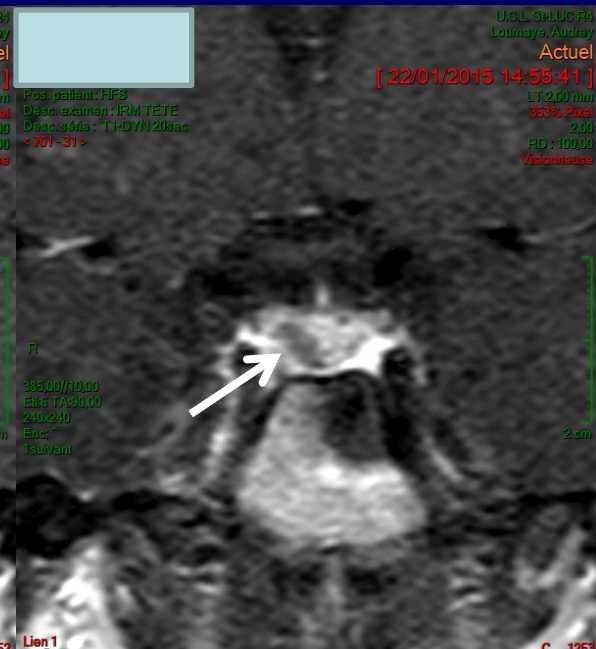
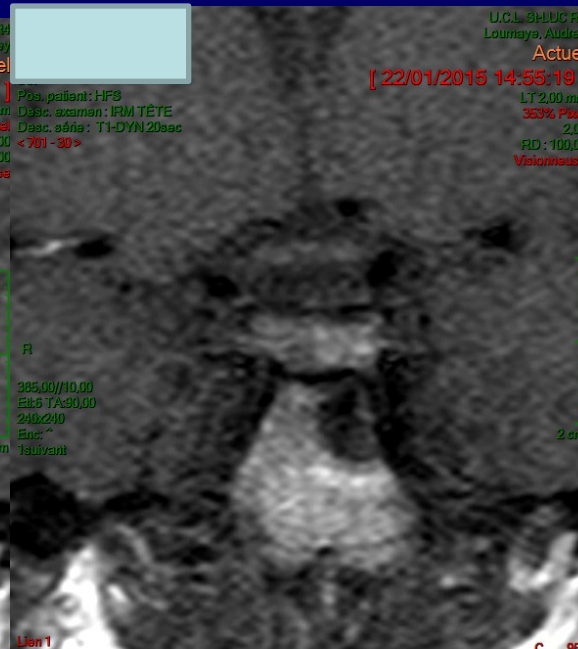
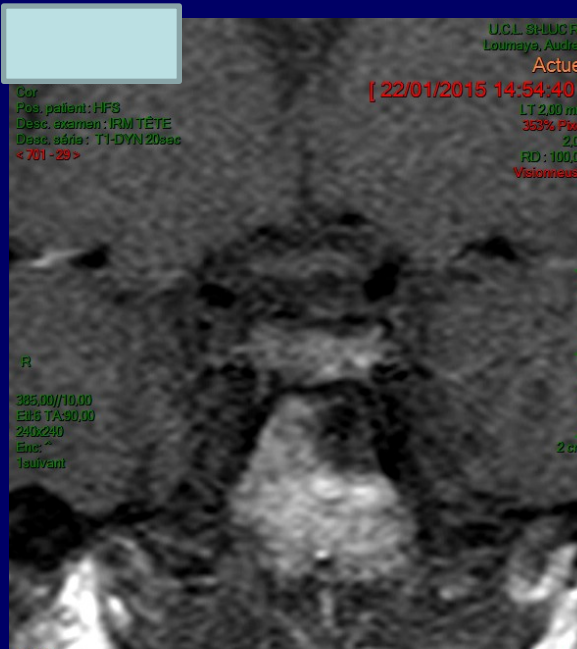
Cabergoline (Sostilar®)



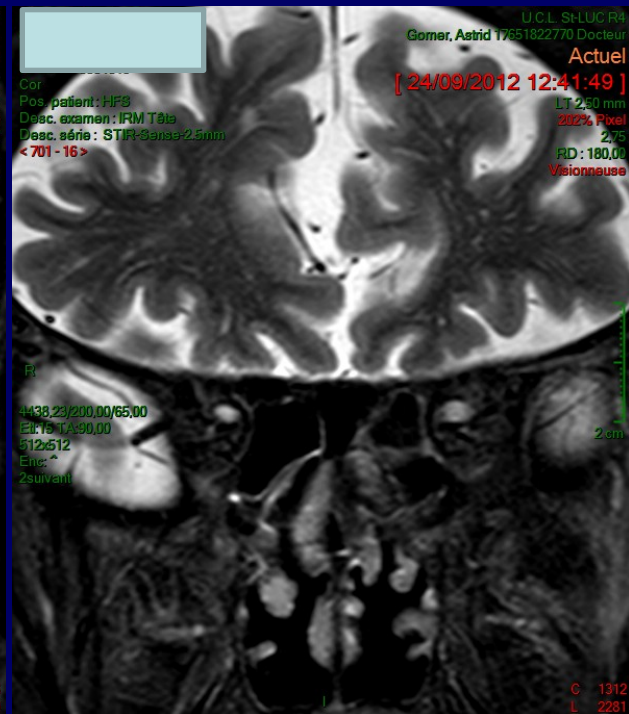
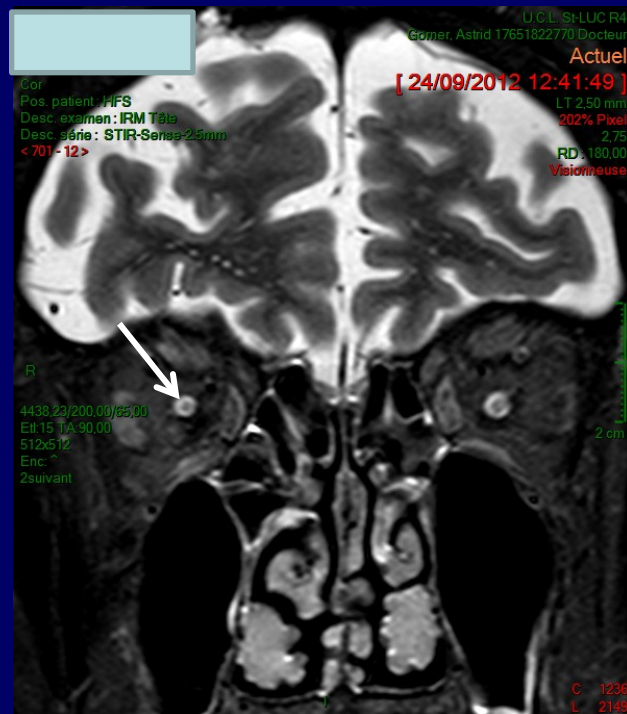
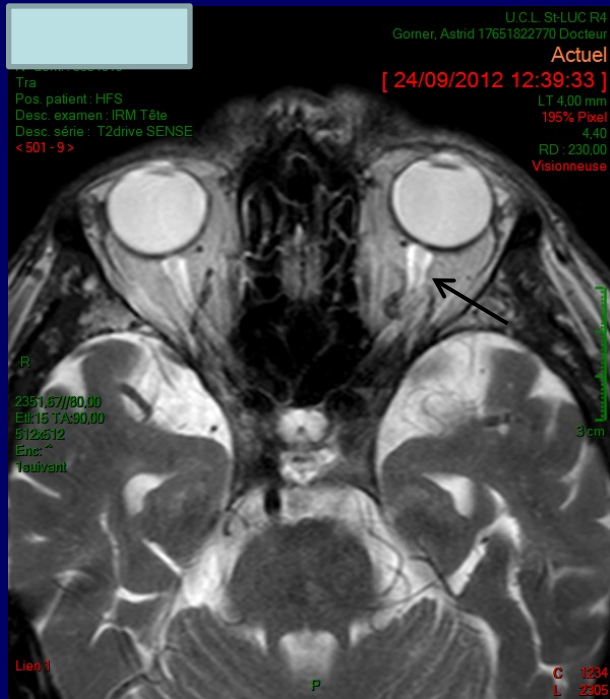
QUIZZ : CAS 3



De quel côté se trouve l'adénome ?

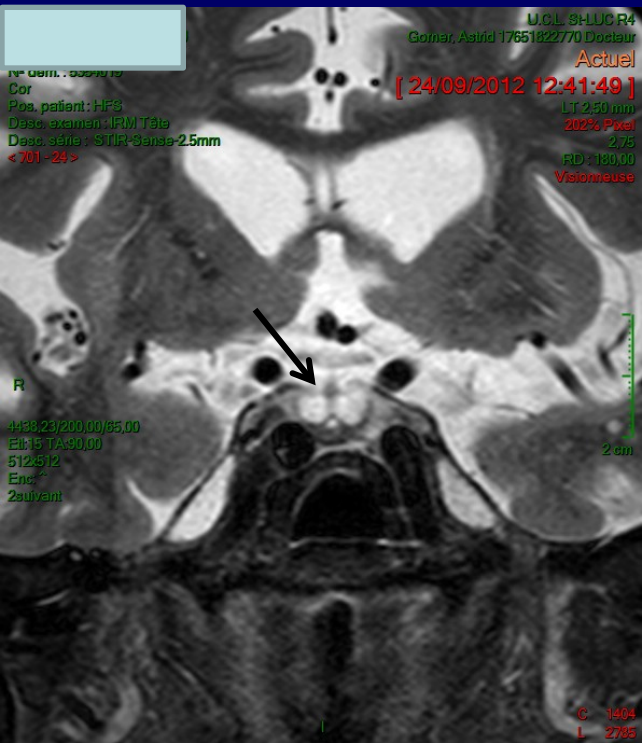
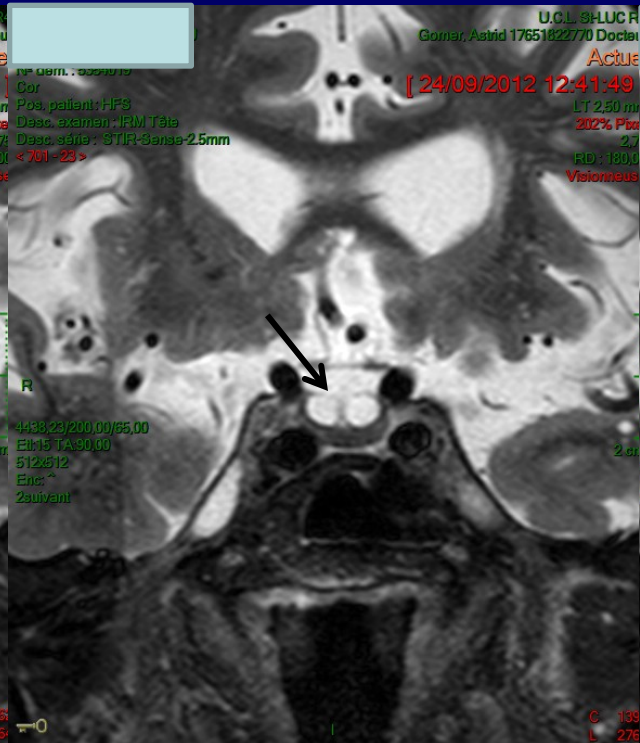
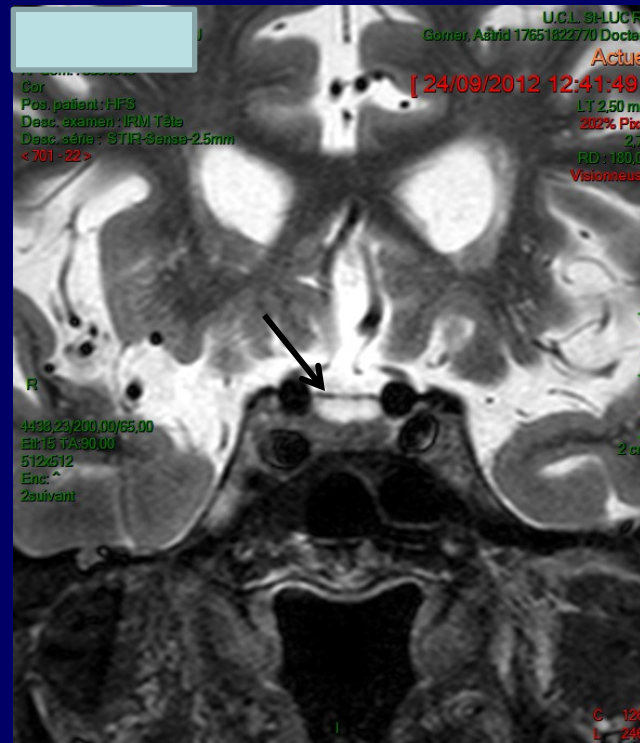


QUIZZ : CAS 4

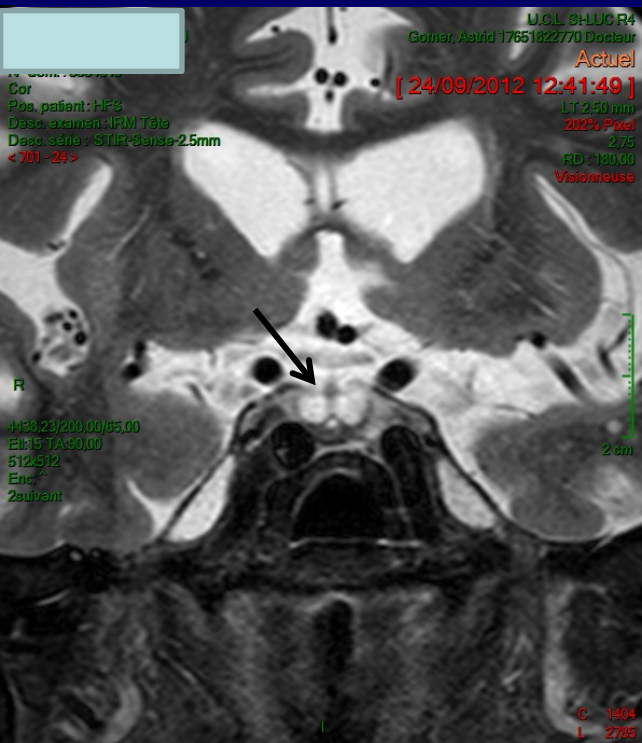
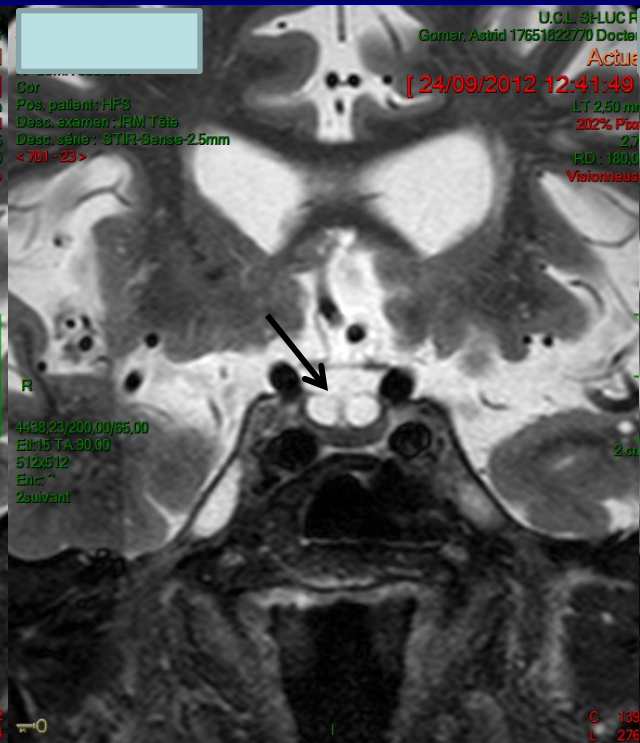
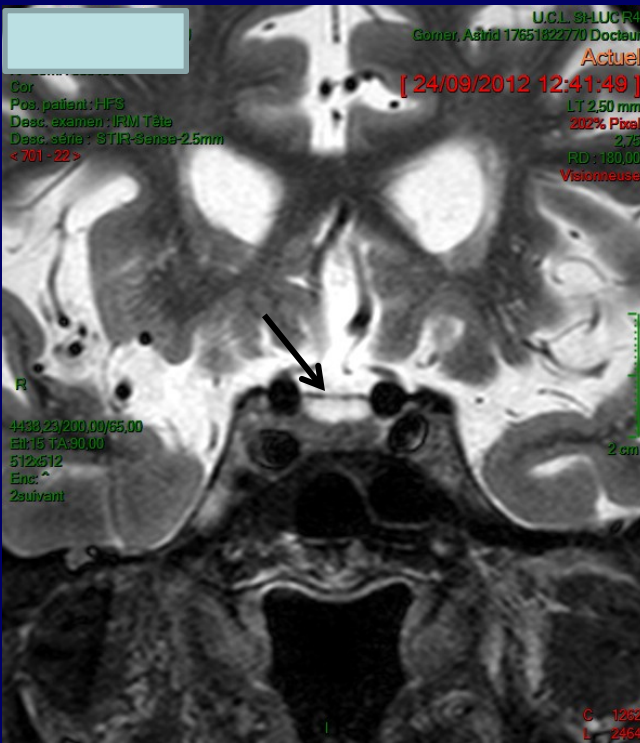


Hypertension intra-crânienne 'bénigne' ('sine materia')

Quelle structure anatomique ?

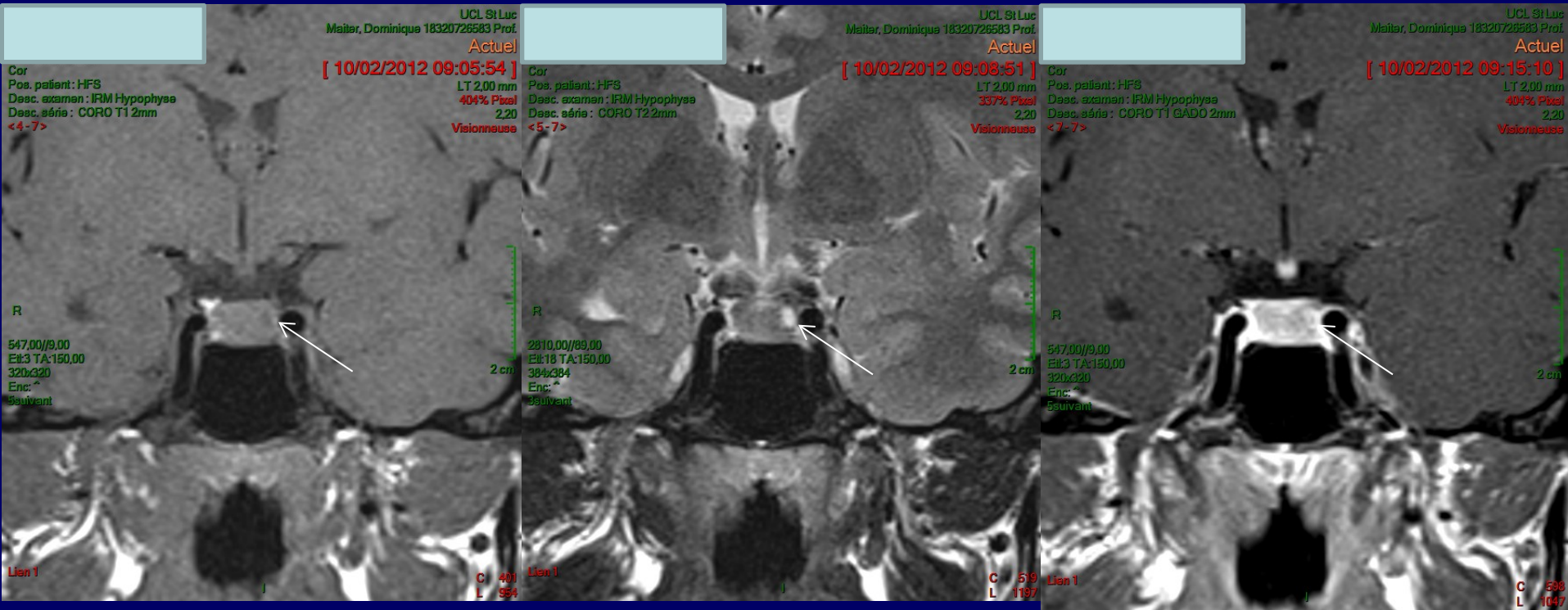


Quelle structure anatomique ?



Diaphragme sellaie

QUIZZ : CAS 5



De quoi s'agit-il ?

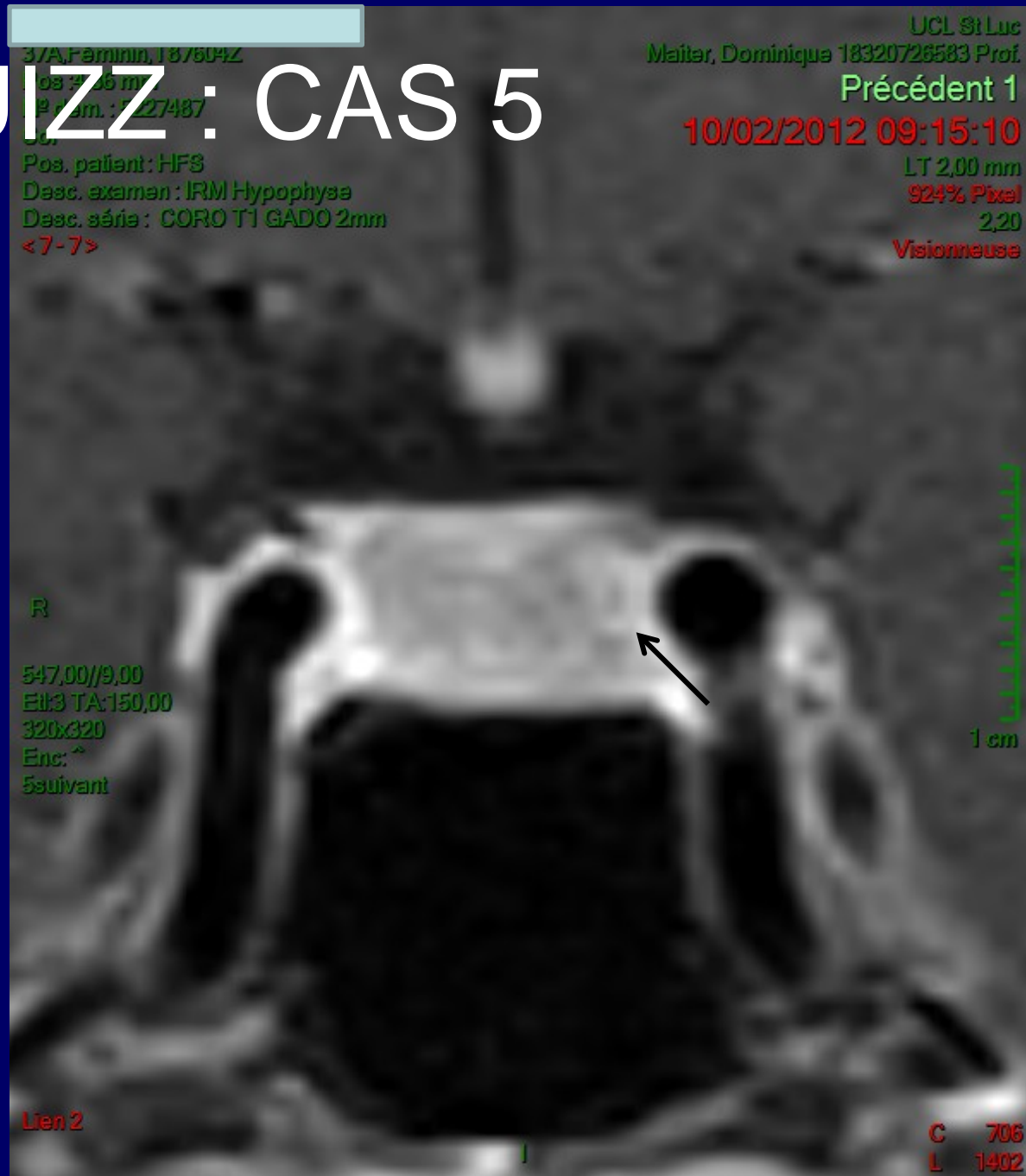
QUIZZ : CAS 5

37A.Féminin,1876U4Z
Pos. patient : HFS
Desc. examen : IRM Hypophyse
Desc. série : CORO T1 GADO 2mm
<7-7>

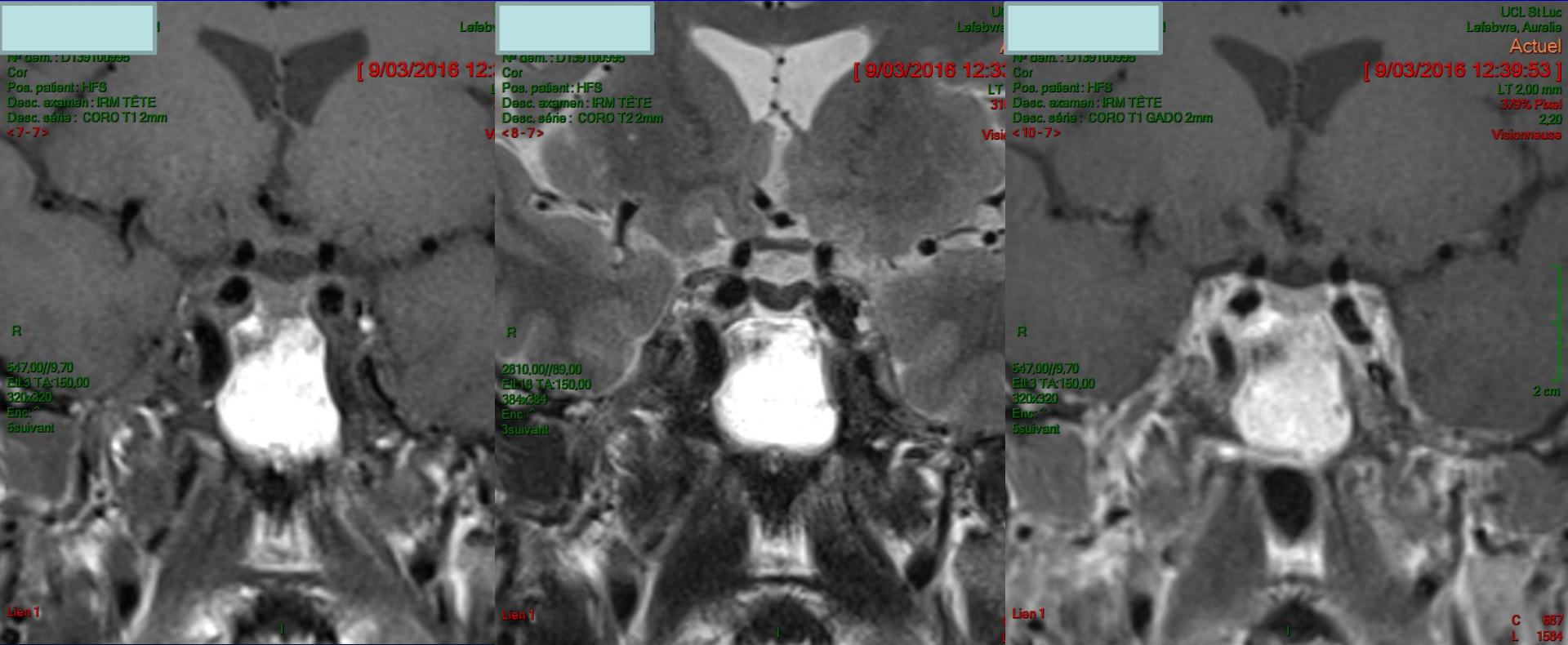
UCL St Luc
Maître, Dominique 18320726583 Prof.
Précédent 1
10/02/2012 09:15:10
LT 2,00 mm
924% Pixel
2,20
Visionneuse

De quoi s'agit-il ?

Adénome
'inflammatoire'

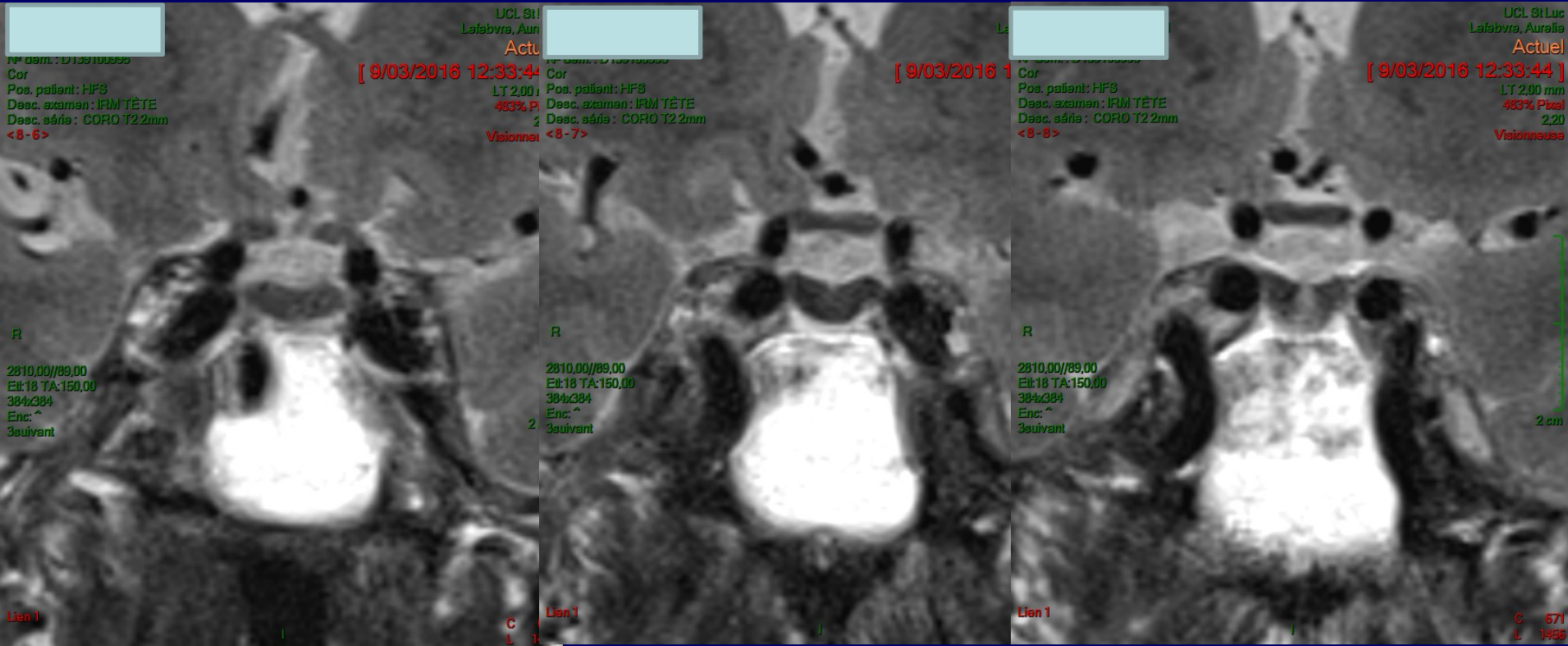


QUIZZ : CAS 6



Hypogonadisme

QUIZZ : CAS 6



hémochromatose