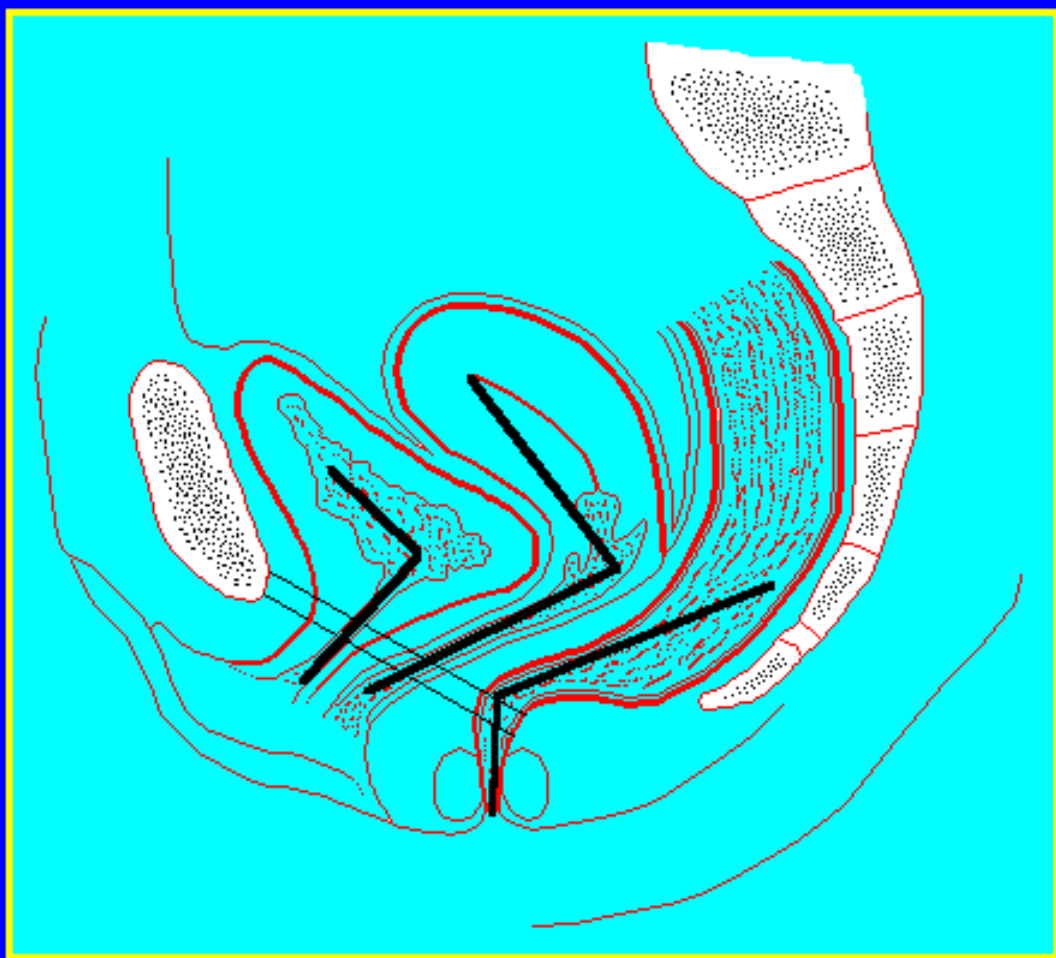


**PELVIC FLOOR'S INSTABILITY**  
**SEEN BY DIGITALIZED**  
**COLPO - CYSTO - DEFECOGRAPHY**

Dr. Marc-H. TANCREDI  
Service d'Imagerie Médicale  
Clinique Saint Luc    Bouge

---

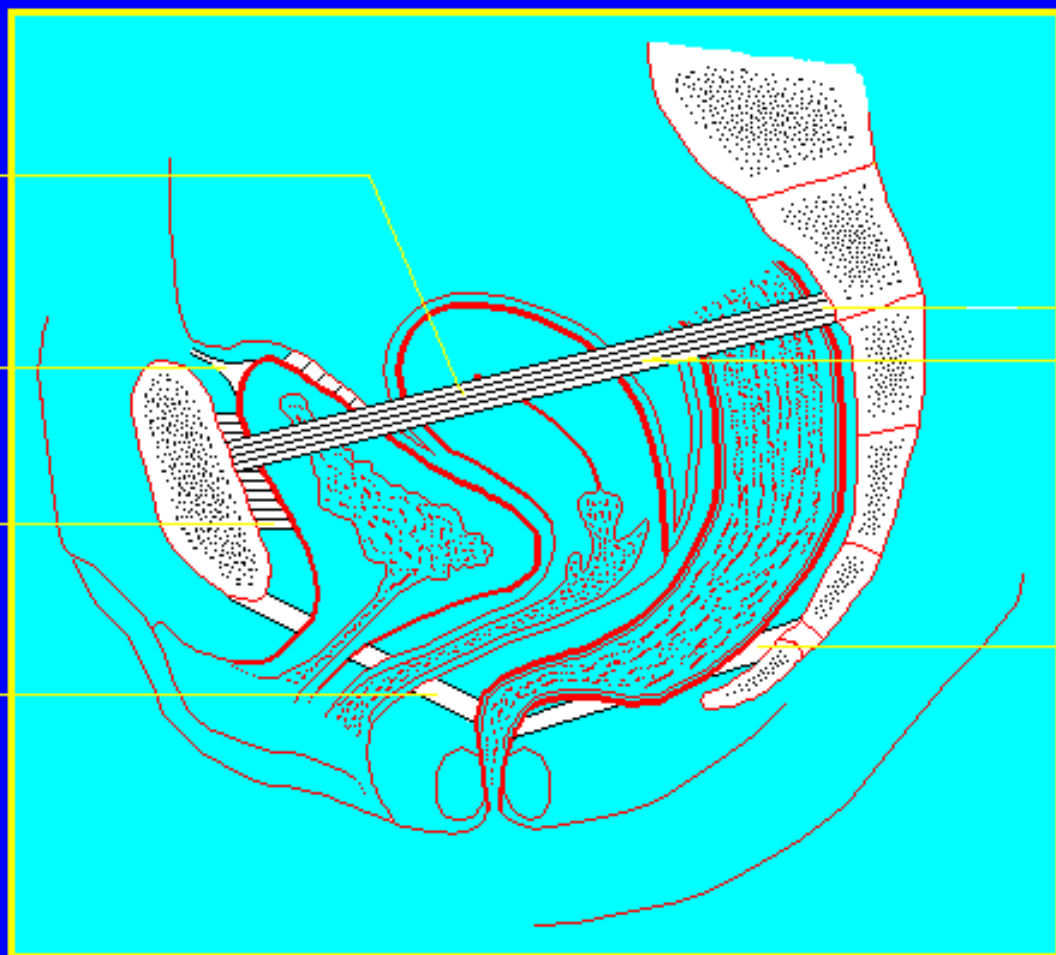


Lamina  
Sacrogenitopubalis

Urachus

Lig Pubovesicale

Diaphragma  
Urogenitale

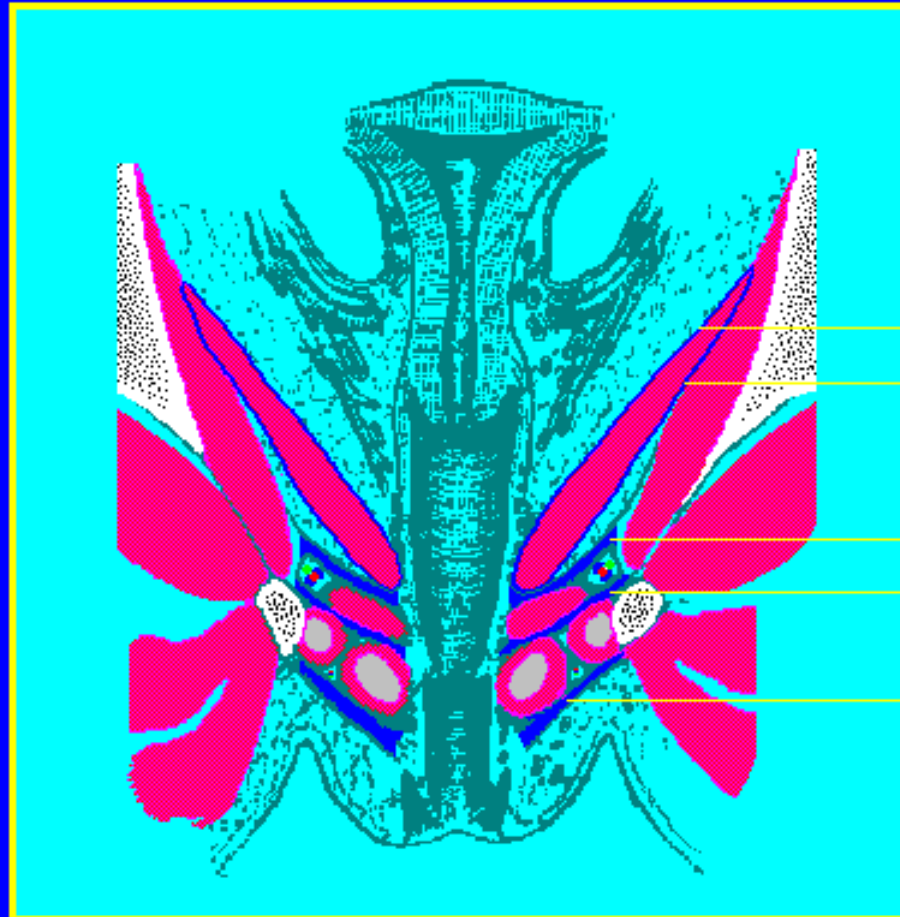


"Lig Uterosacralis" :

Plica Sacro-rectalis

Plica Recto-uterina

Diaphragma  
Pelvis



*Diaphragma pelvis*

Fascia superior

Fascia inferior

*Diaphragma urogenitale*

Fascia superior

Fascia inferior  
(membrana perinei)

Fascia perinei  
superficialis



M. Levator ani

M. Transversus perinei  
profundus

M. Ischiocavernosus

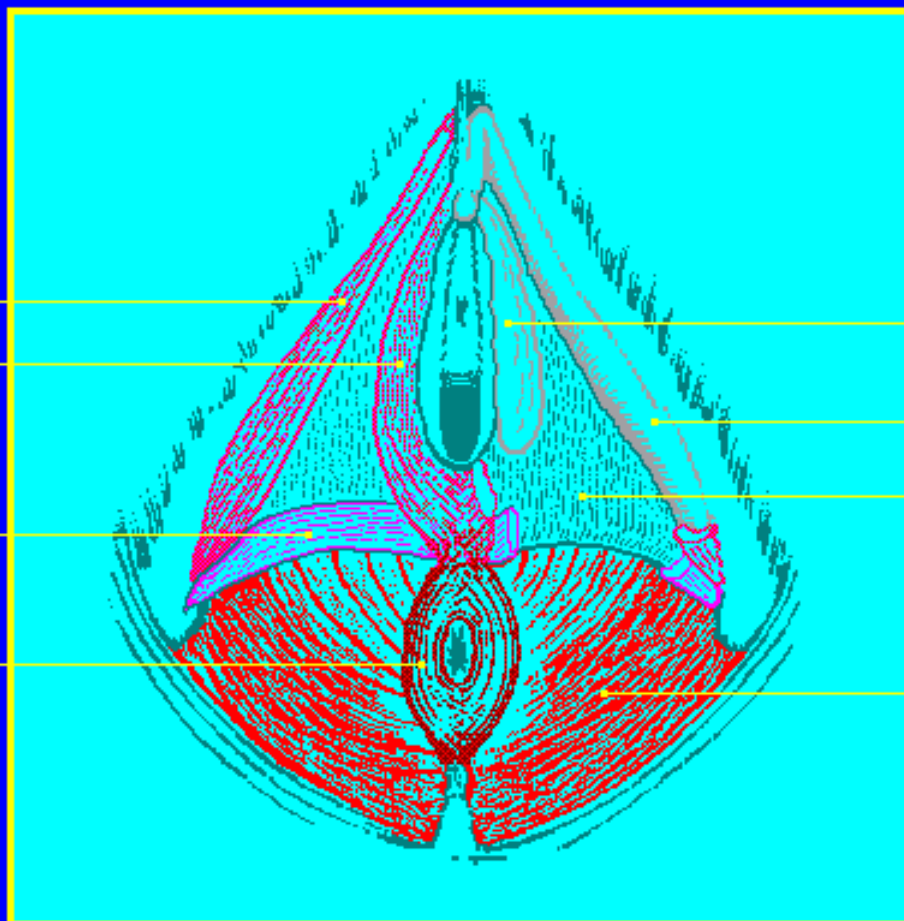
M. Bulbospongiosus

**M. Ischiocavernosus**

**M. Bulbospongiosus**

**M. Transversus  
perinei  
superficialis**

**M. Sphinter ani  
externus**



**Bulbus vestibuli  
vaginae**

**Corpus cavernosum  
clitoridis**

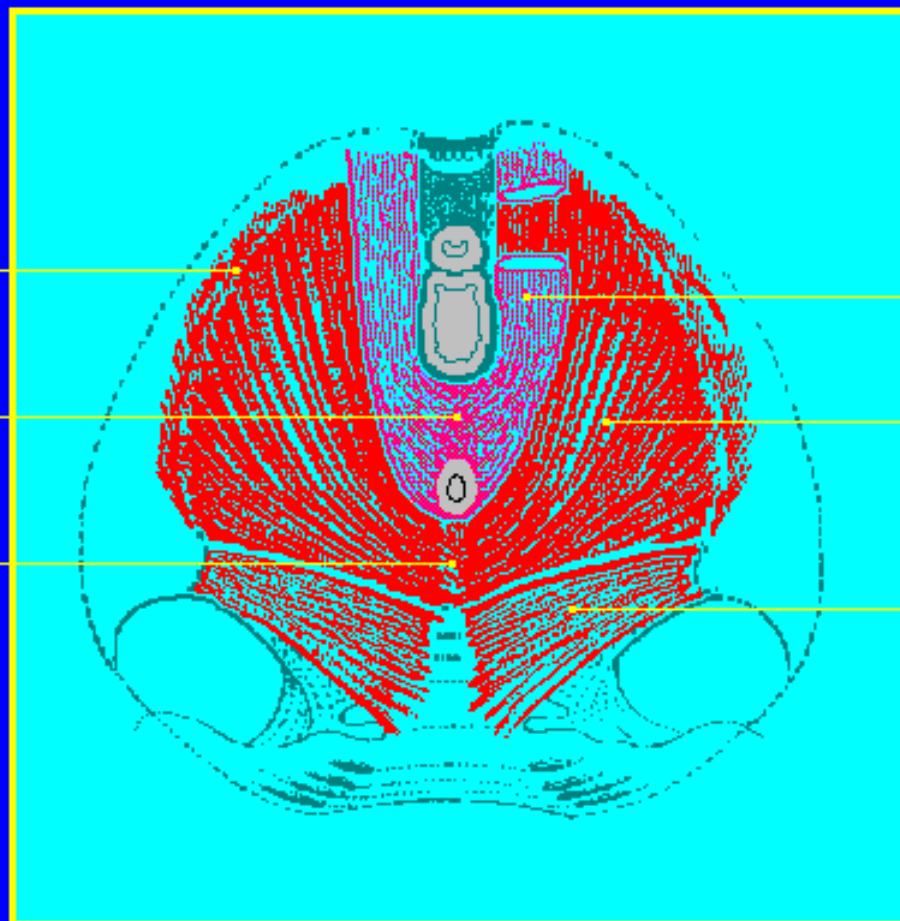
**Fascia diaphragmatis  
urogenitalis inferior  
(membrana perinei)**

**Levator ani**

Arcus tendineus  
m. levatoris ani

Raphe tendinea  
perinei

Lig anococcygeum



M. Levator ani :

pars interna  
[levator]


pars externa  
[sphinct]

M. Ischiococcygeus

Spatium Retropubicum  
(Retzius)

Excavatio Vesicouterina

Excavatio Rectouterina  
(Douglas)



Lig Pubovesicale

Lig Teres Uteri

Lig Latum

Plica Rectouterina

↳ "Lig Uterosacralis"

Plica Sacrorectalis



## **CAUSES :**

**Constitutional**

**Age - Menopause**

**Pregnancies - Deliveries - Episiotomies**

**Pelvic Surgery**

## **SYMPTOMS :**

### **Rectal Sympt.**

**Constipation**  
**Exoneration Difficulty**  
**Laxatives**  
**Incomplete Emptying**  
**False Needs**  
**Pain**  
**Manual Aid**

### **Urinary Sympt.**

**Effort Losses**  
**Emergencies**  
**Dysuria**  
**Incontinence**

## **TREATMENT :**

**Dietetic**

**Hormono-therapy (menopause)**

**Physiotherapy**

**Surgery**

## ***Remarks :***

**Importance of a real multi-disciplinary staff**

**Role of the preventive cares thanks to CCD**

**THE  
DIGITALIZED  
COLPO CYSTO  
DEFECOGRAPHY**

## **INDICATIONS :**

**Suspicion of a pelvic prolapse**

**Suspicion of a functional disorder in exoneration**

**Pre-operative work-up in pelvic surgery**

*For female patients, the CCD should supersede the conventional defecography which leads to incomplete conclusions.*

## **METHODS :**

**Bladder - vagina and rectum opacification**

**Setting patient on the defecography stool-chair**

**Side views : one at rest**

**one during a squeezing effort**

**sequence during micturation and defecation**

*Table : G.E. Prestilix 1600 X*

*Digitalized - Matrix 1024*



Service d'Imagerie Médicale  
Clinique Saint Luc Bouge

# ADVANTAGES OF NUMERISATION

*Images immediately available on the screen*

## About doses

- Number of views manually controled (max 1/sec)
- Exam's quality live evaluated

## About patient

- Strain's efficiency directly evaluable
- Exam's results immediately available (+ cine viewing)

.../...



## About Radiologist

- cine viewing (interaction's analysis)
- post-processing
- hard-copy mounting
- archiving (PACS)

## **RESULTS :**

*In one single procedure, CCD allows evaluation of :*

- **floor's sagging**
- **bladder neck competence**
- **urethrotrigonal angle**
- **puborectalis tonicity**
- **anal sphincter competence**
- **dynamic of micturation**
- **dynamic of defecation**
- **reciprocal influences**

## **PROLAPSE'S RATE :**

**Among 300 patients who had consulted a coloproctologist and underwent CCD :**

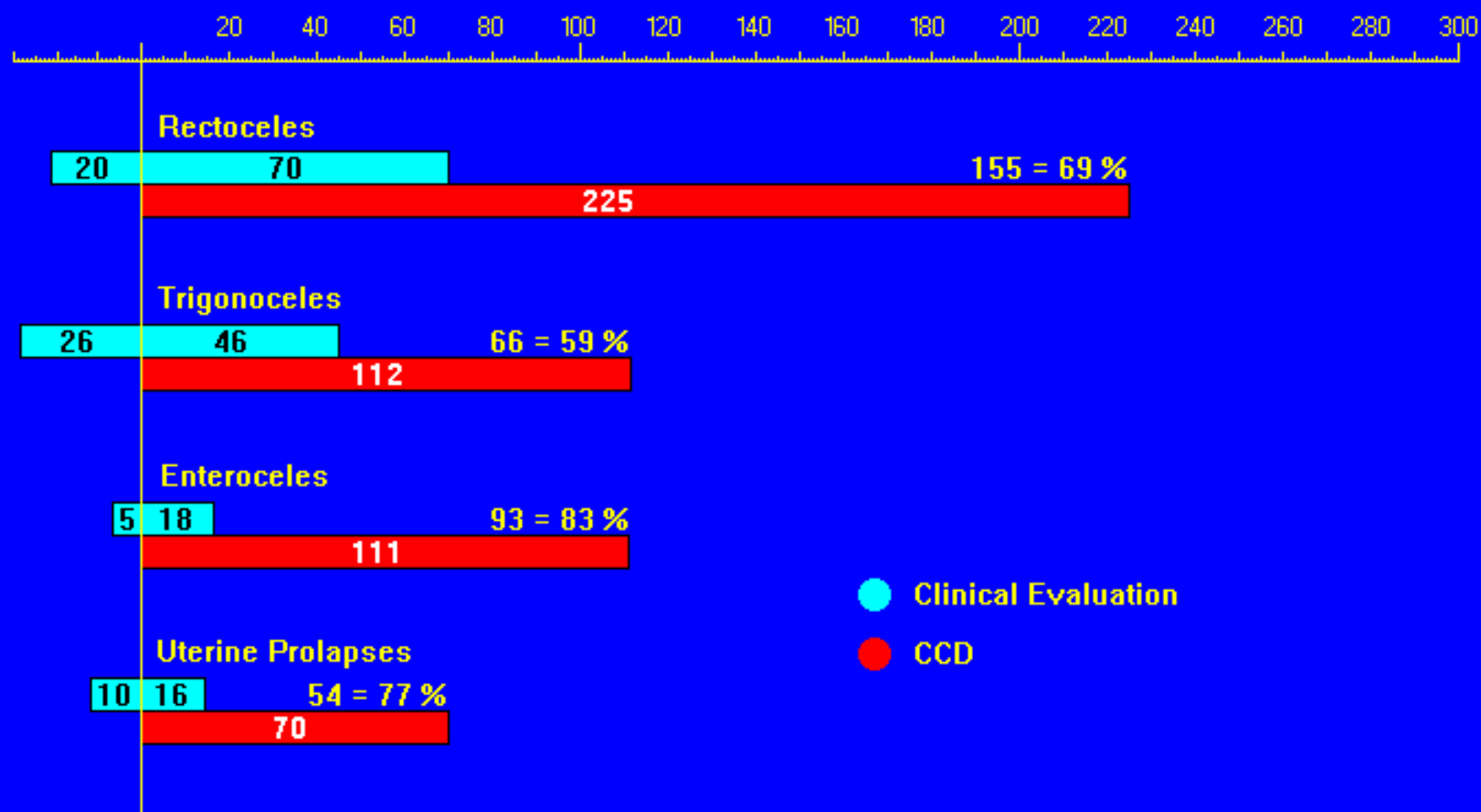
**225 rectoceles**

**112 trigonocèles**

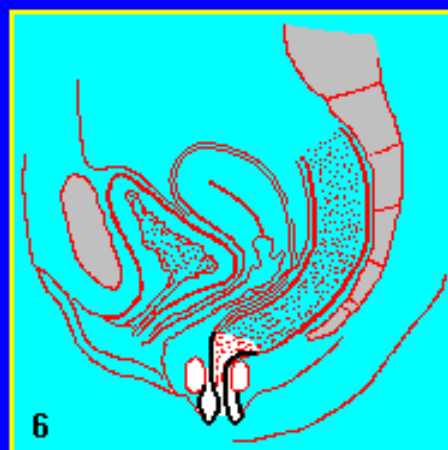
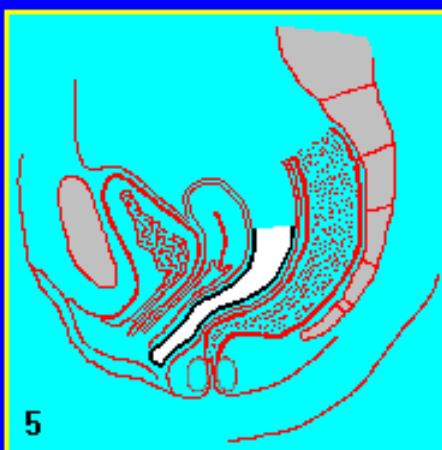
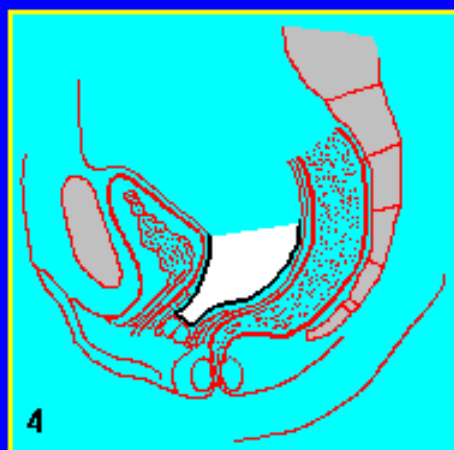
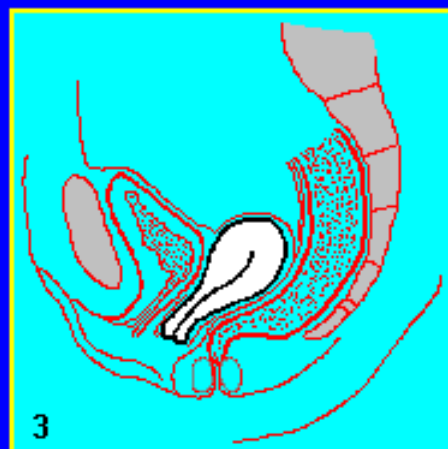
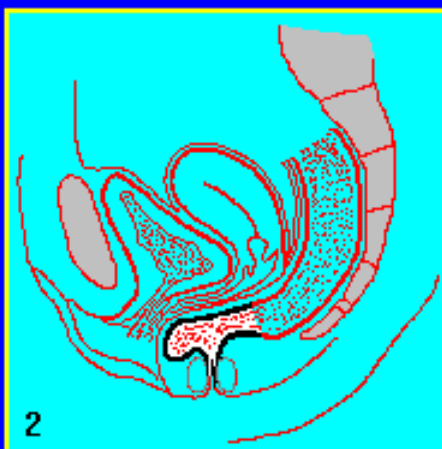
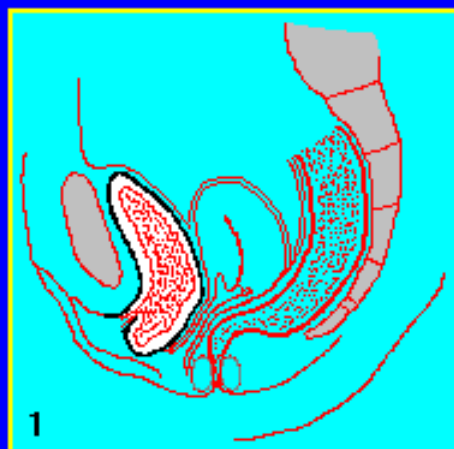**111 enteroceles**

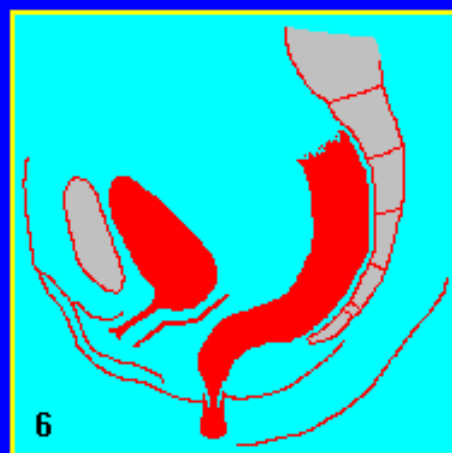
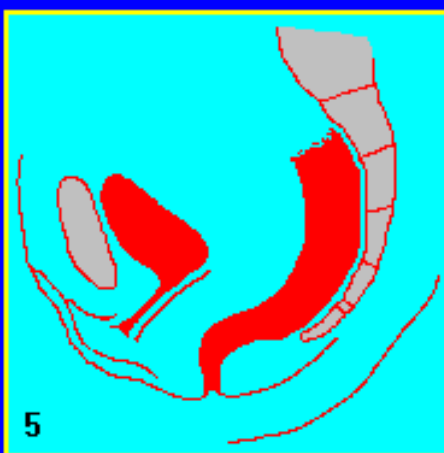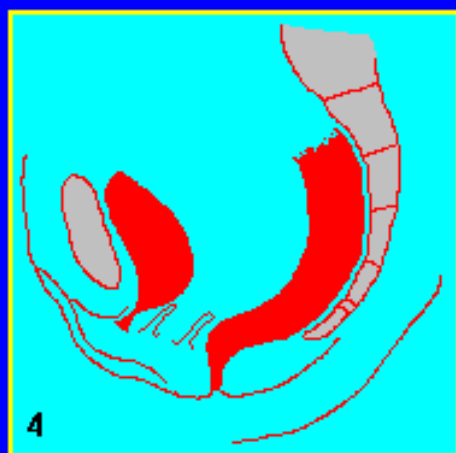
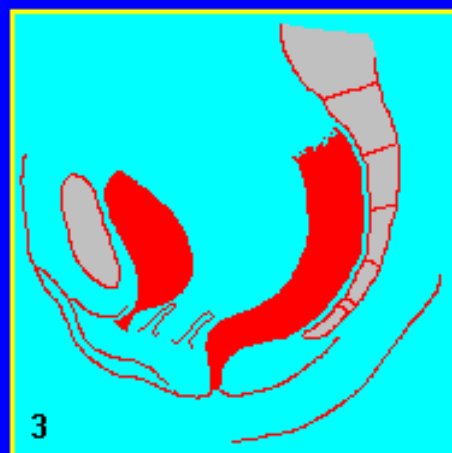
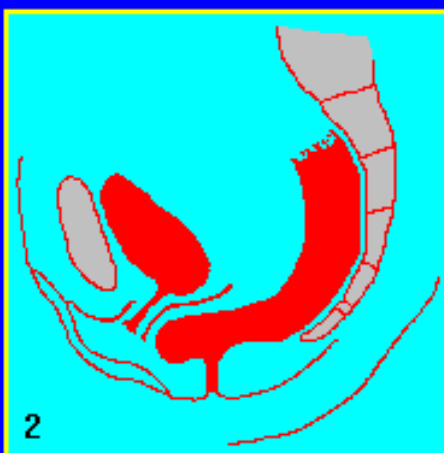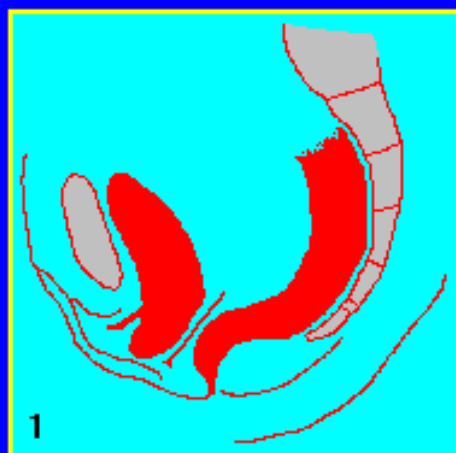**70 uterine prolapses**

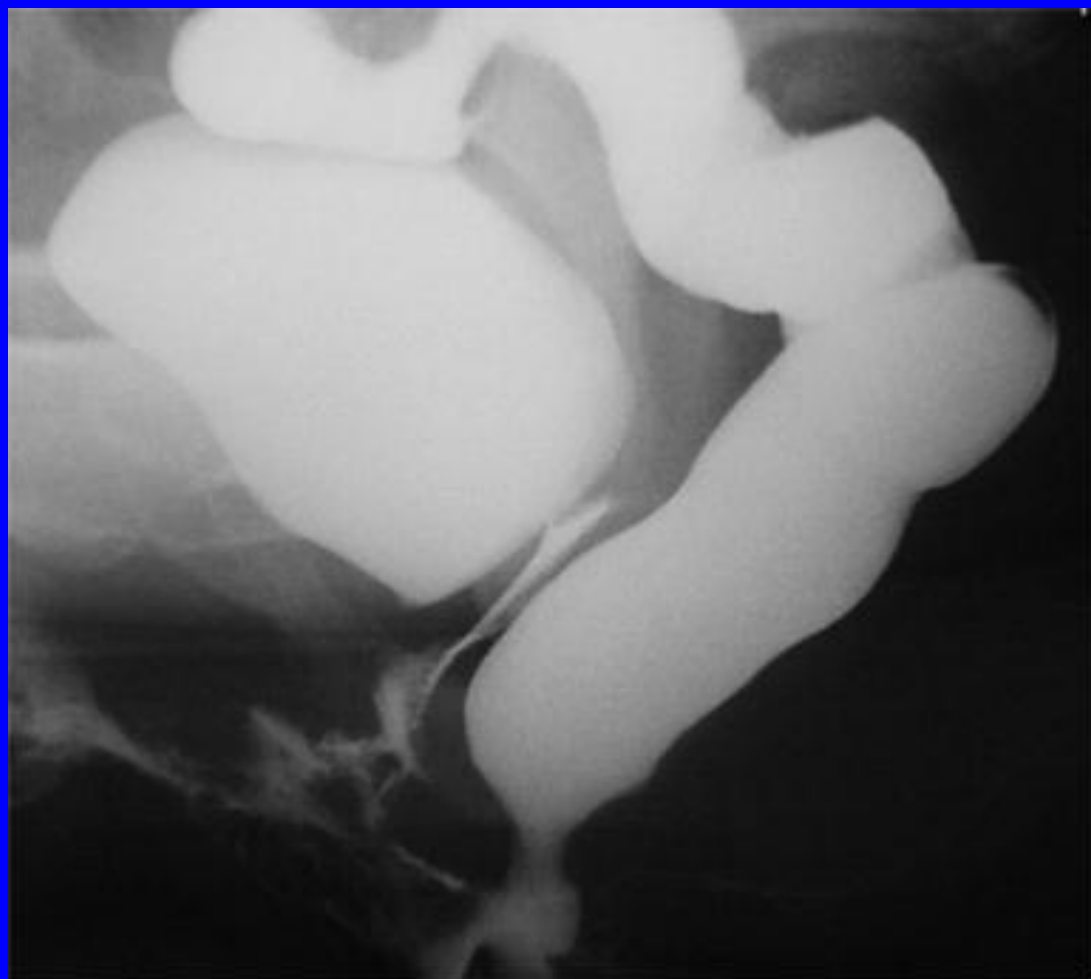Ref : Hock D. Colpocystodefecography Dis Colon Rectum 1993

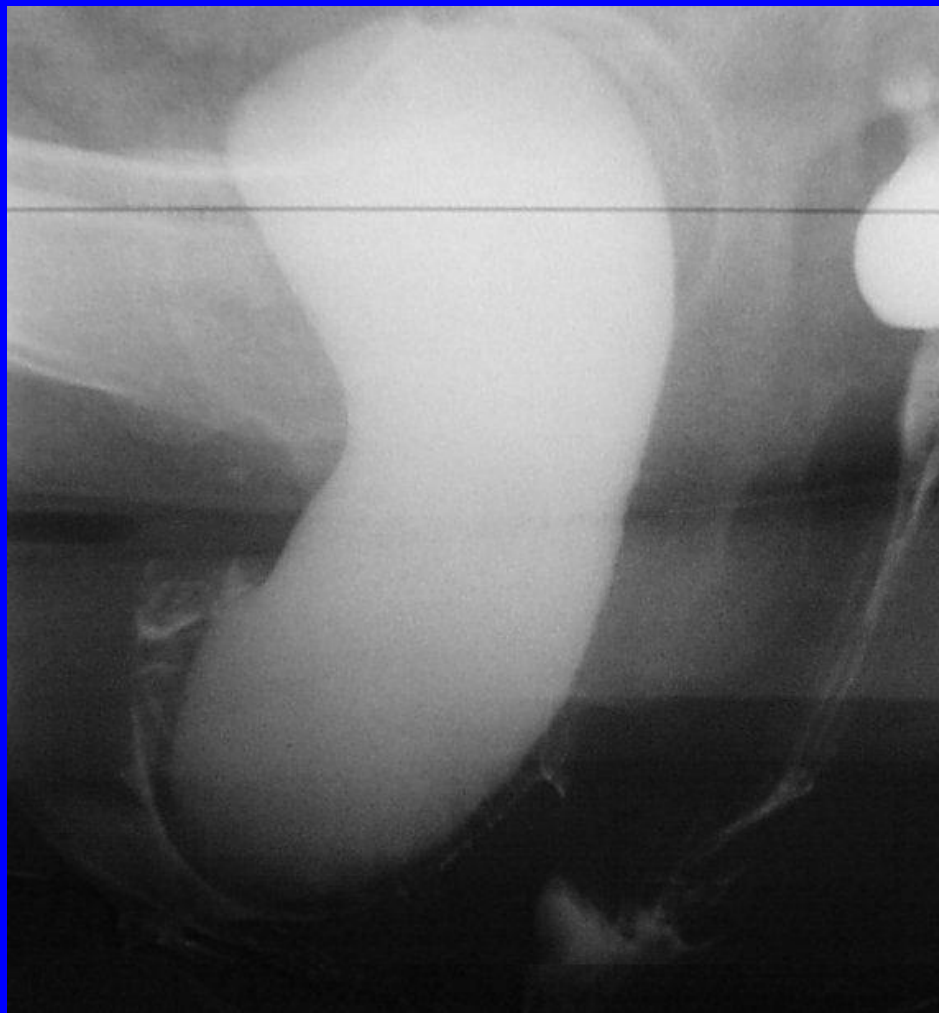


Ref : Hock D. Colpocystodefecography Dis Colon Rectum 1993

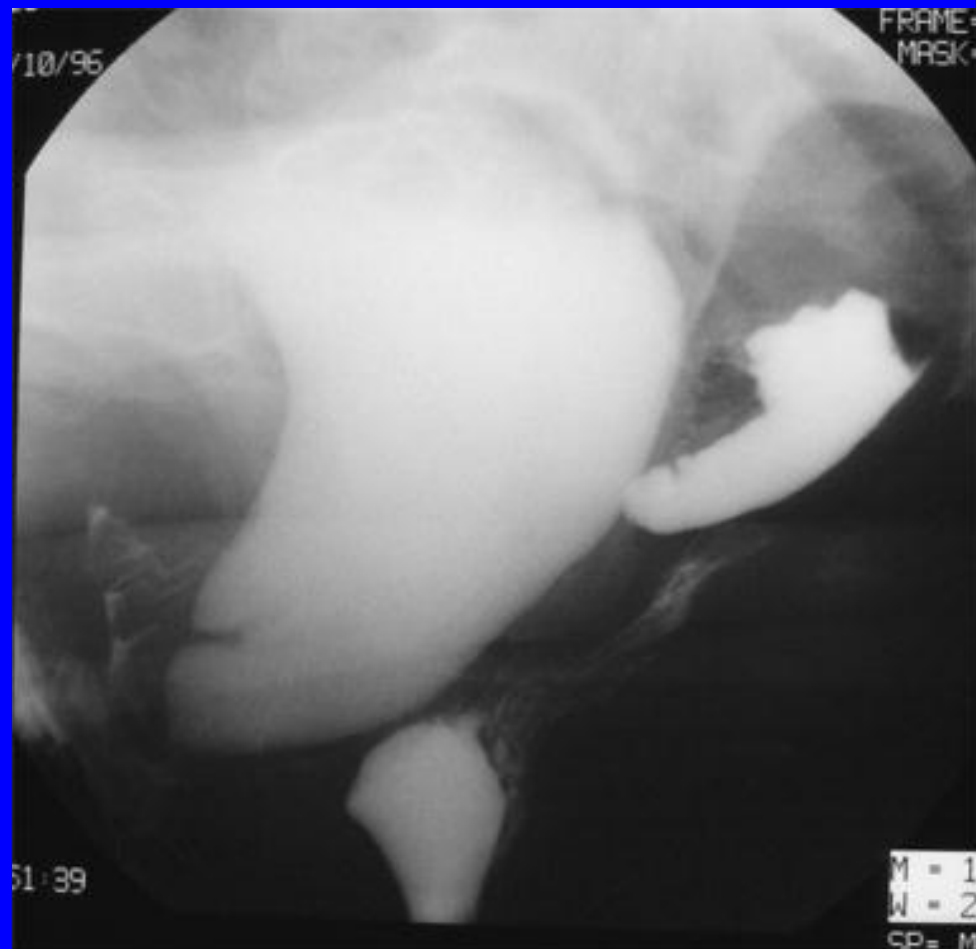

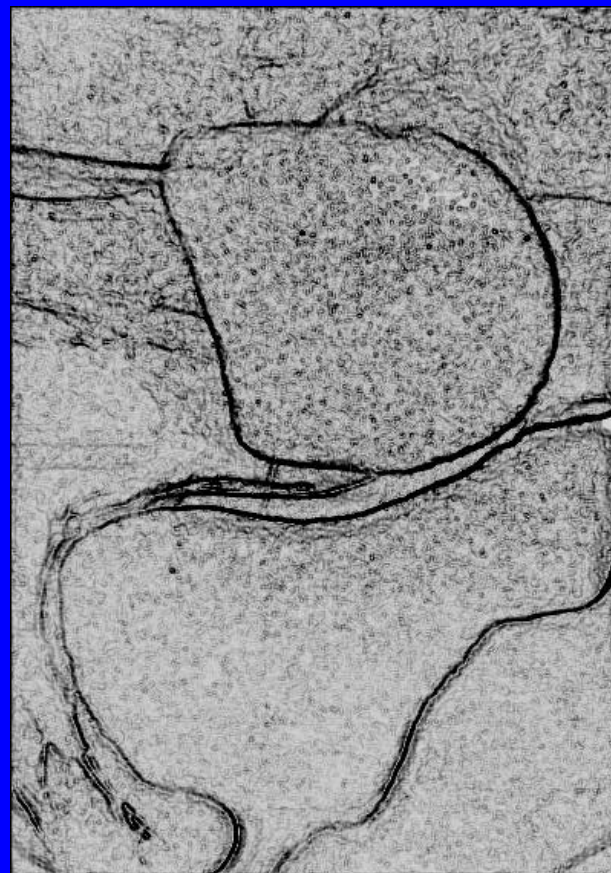
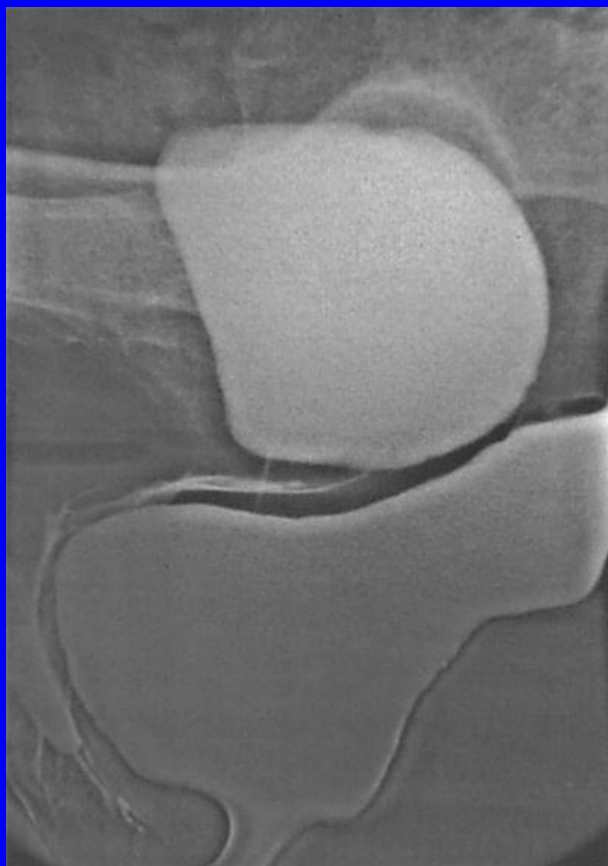



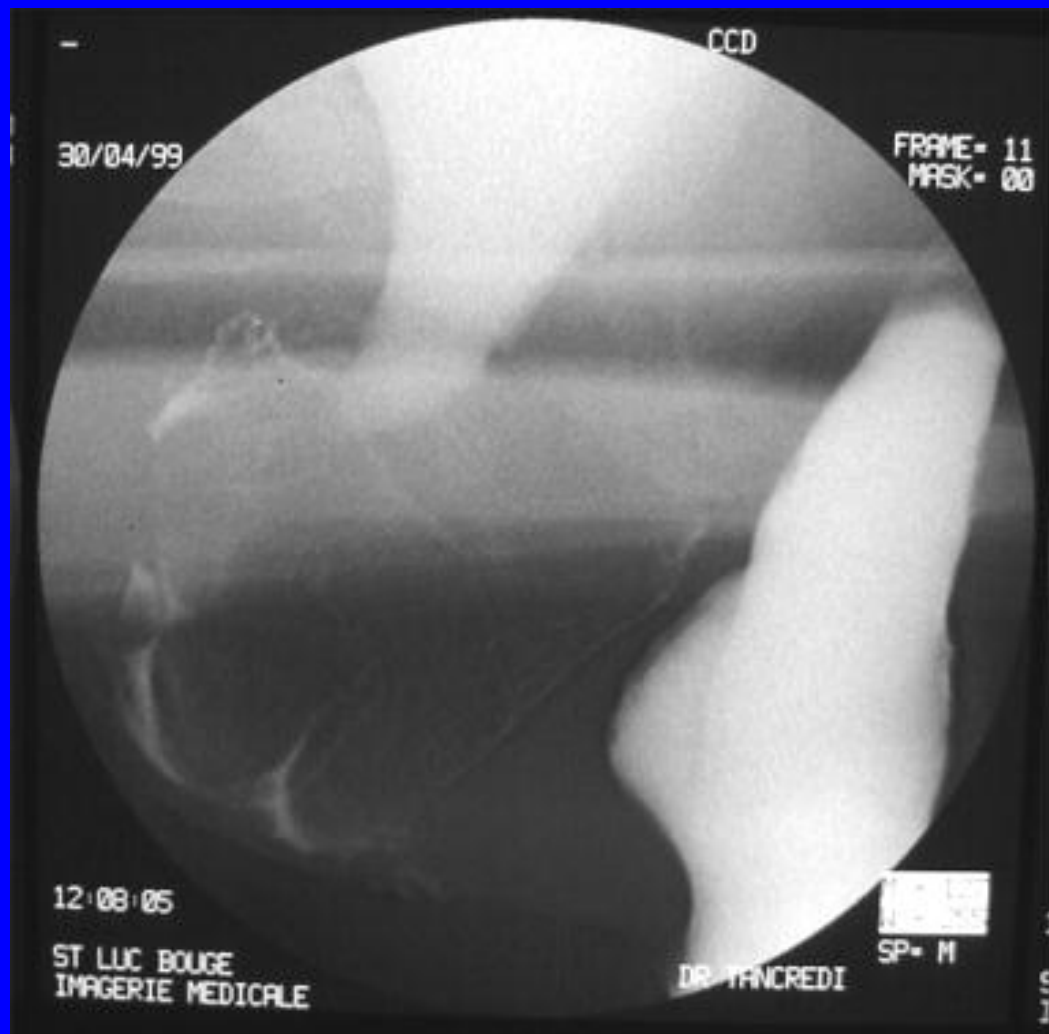




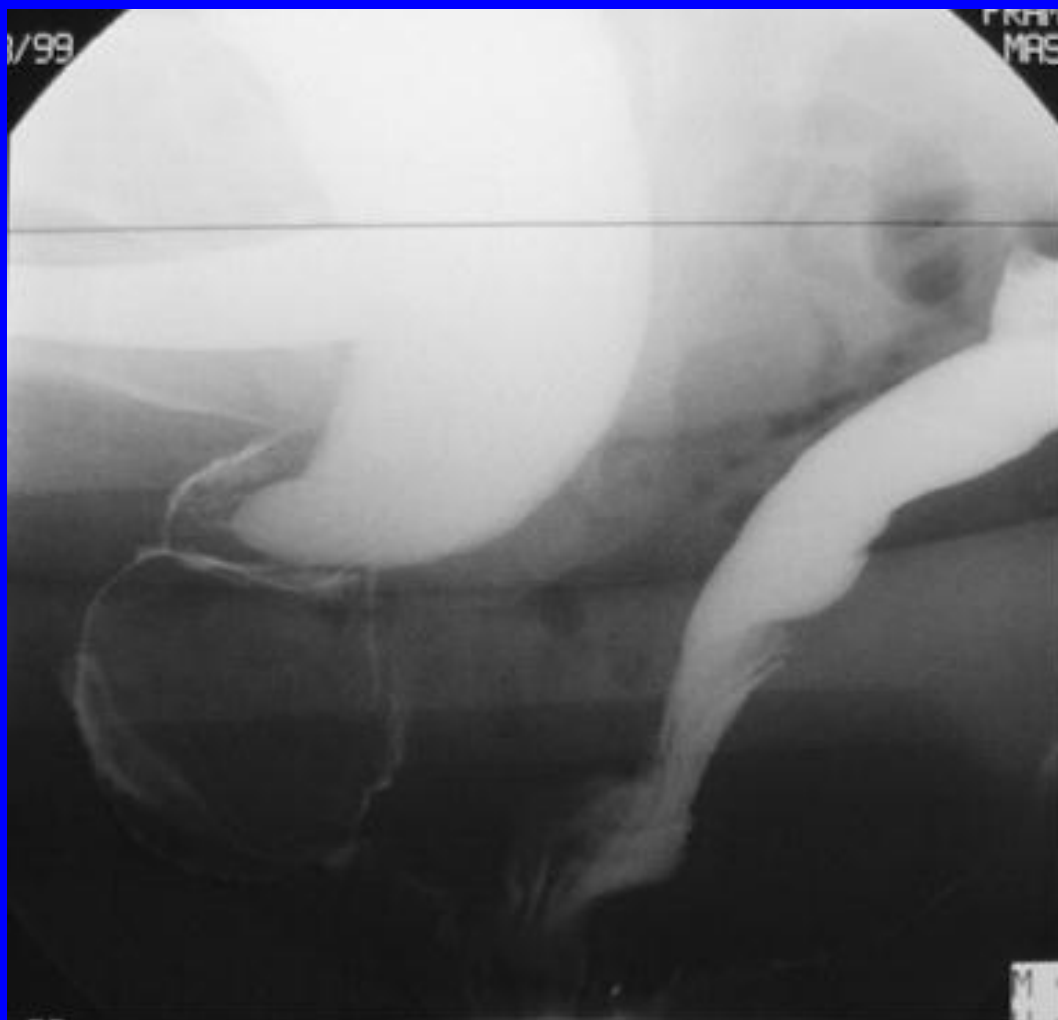


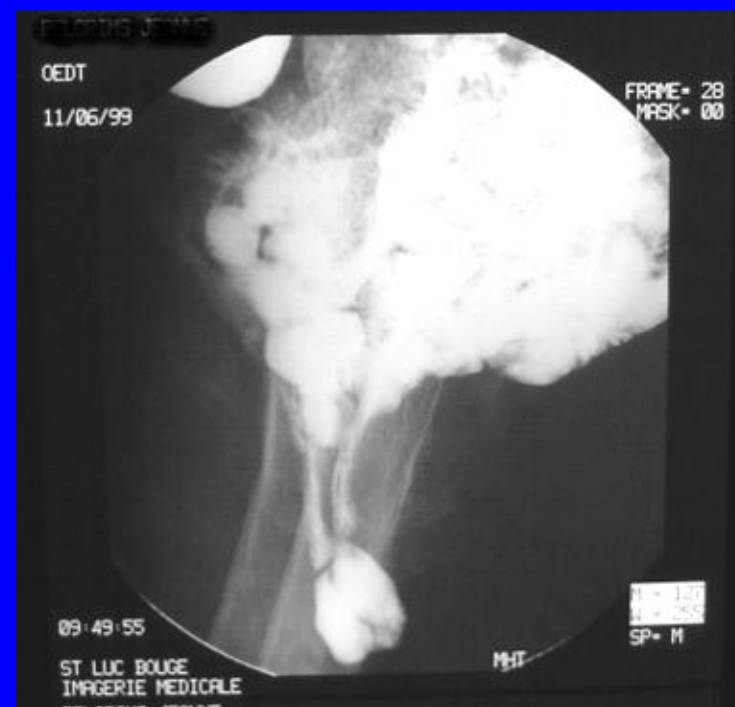
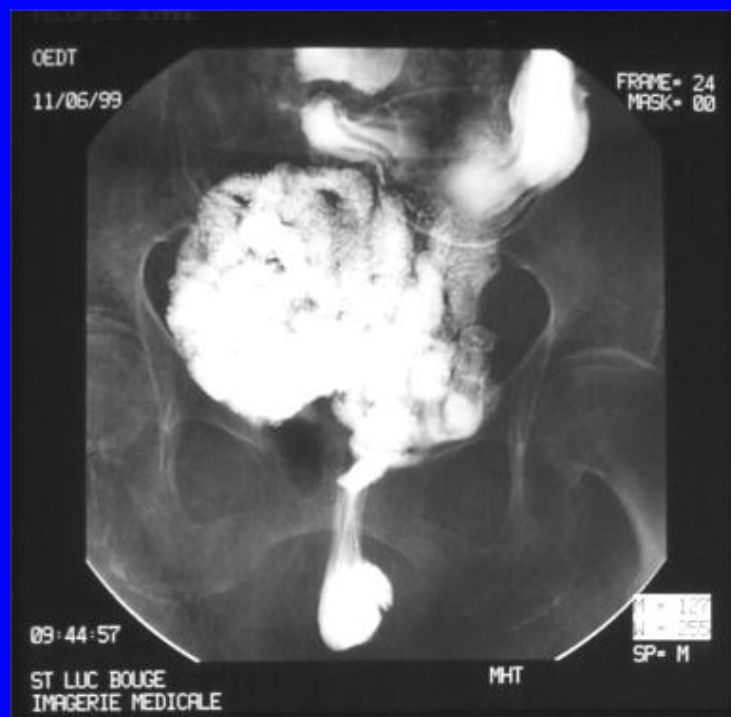

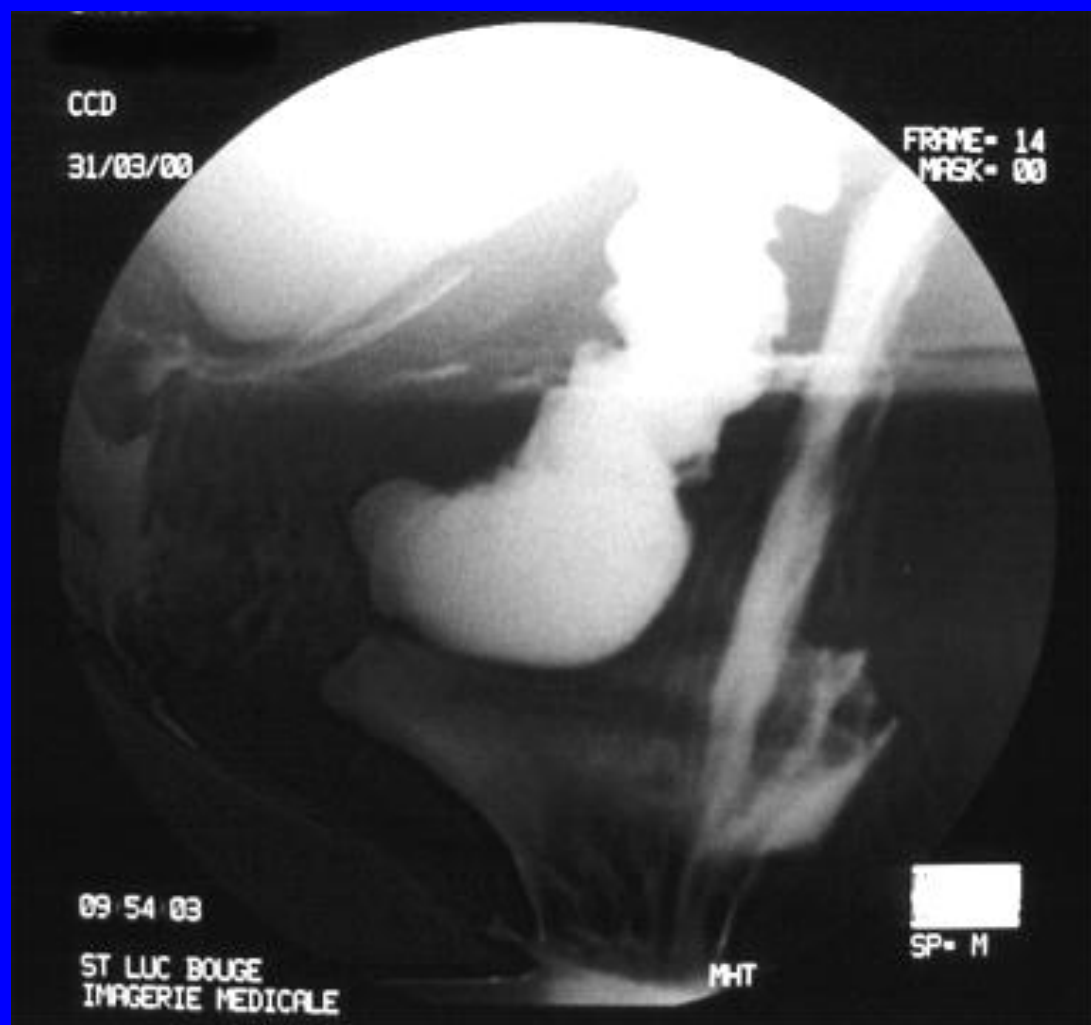Service d'Imagerie Médicale  
Clinique Saint Luc Bouge

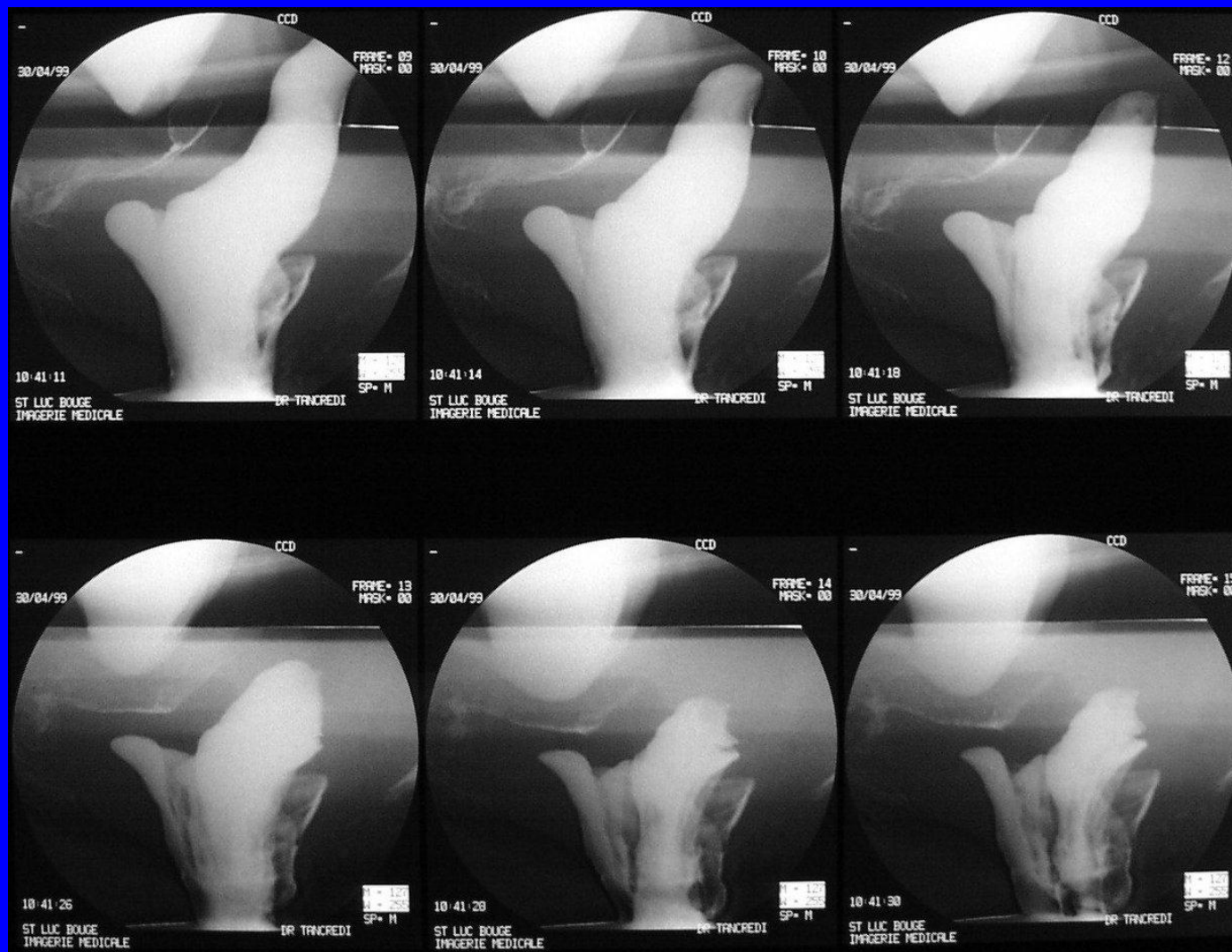




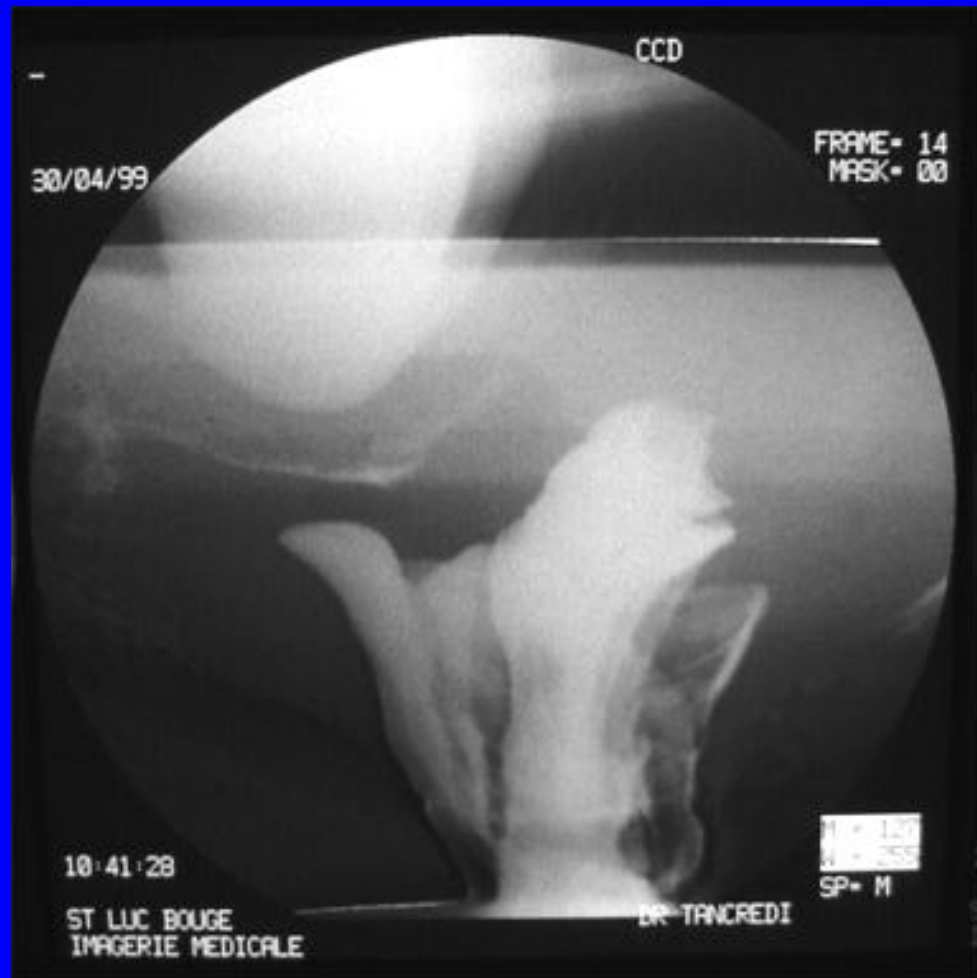

Service d'Imagerie Médicale  
Clinique Saint Luc Bouge



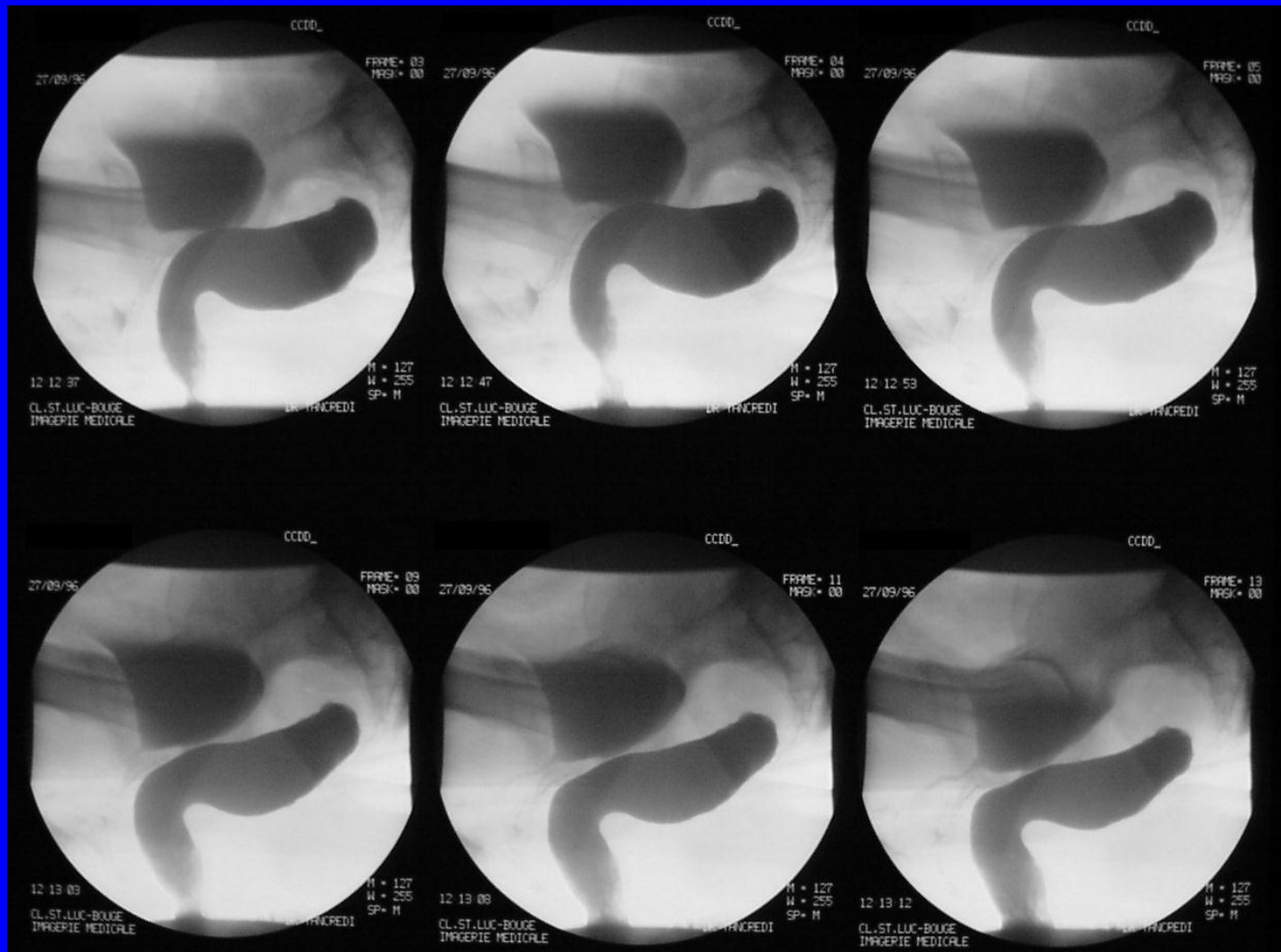


Service d'Imagerie Médicale  
Clinique Saint Luc Bouge

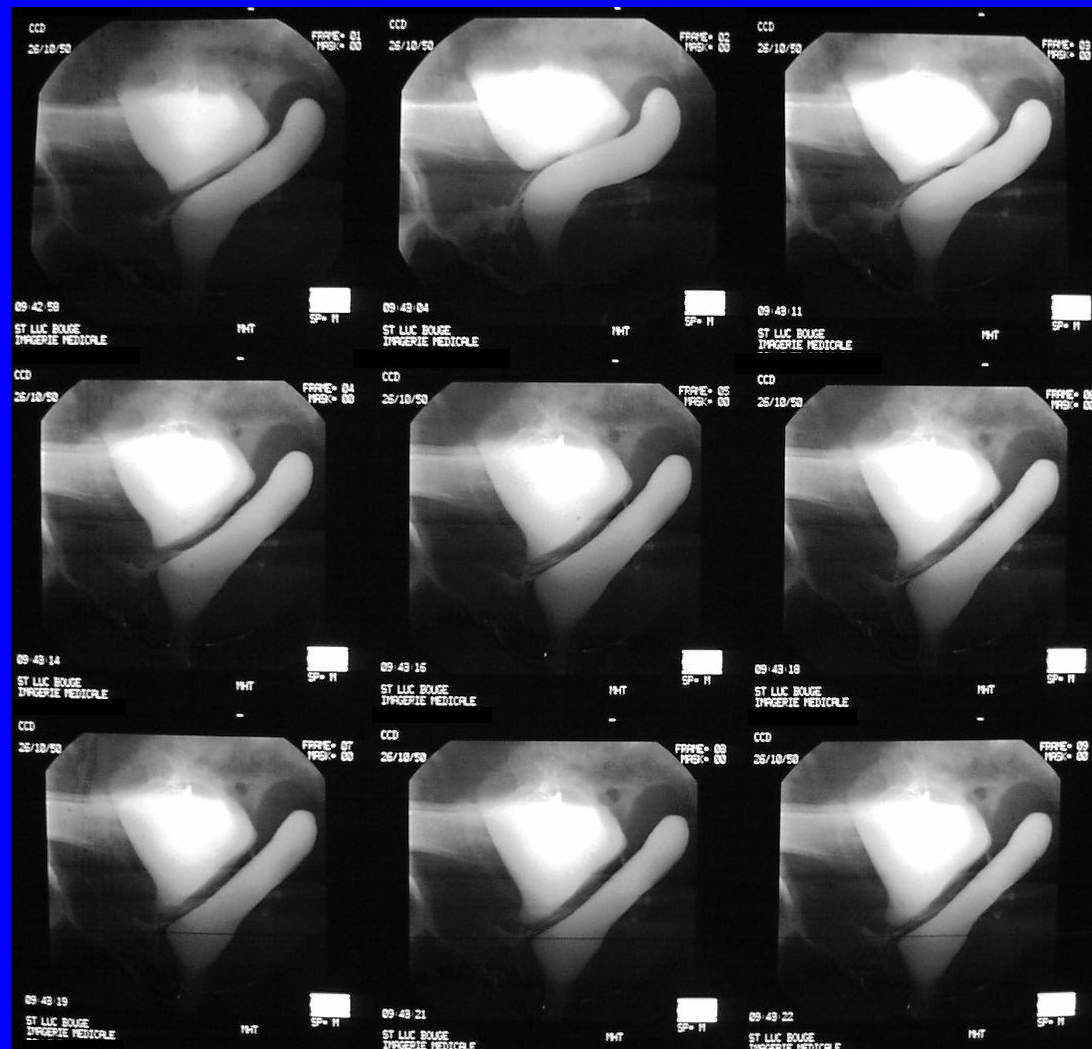


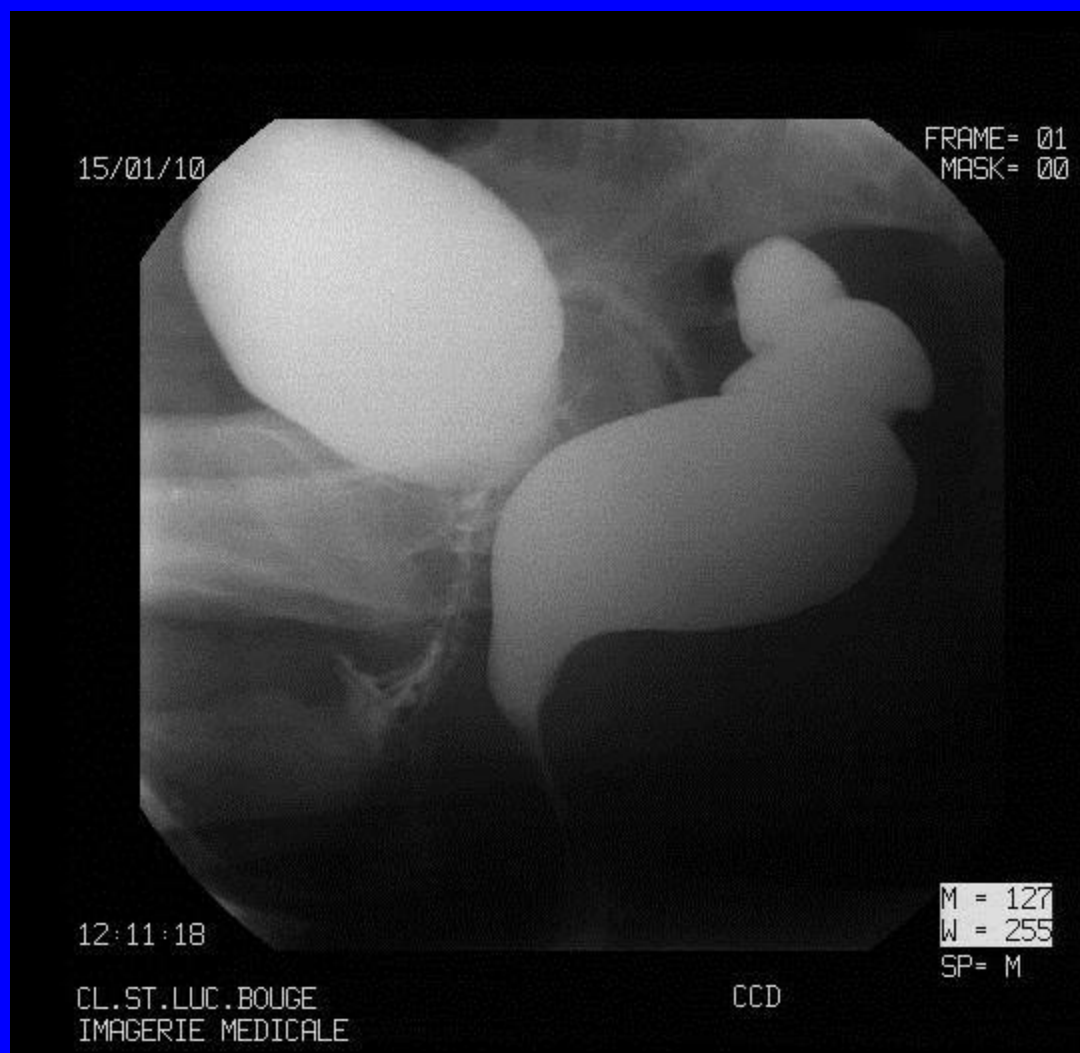

Service d'Imagerie Médicale  
Clinique Saint Luc Bouge

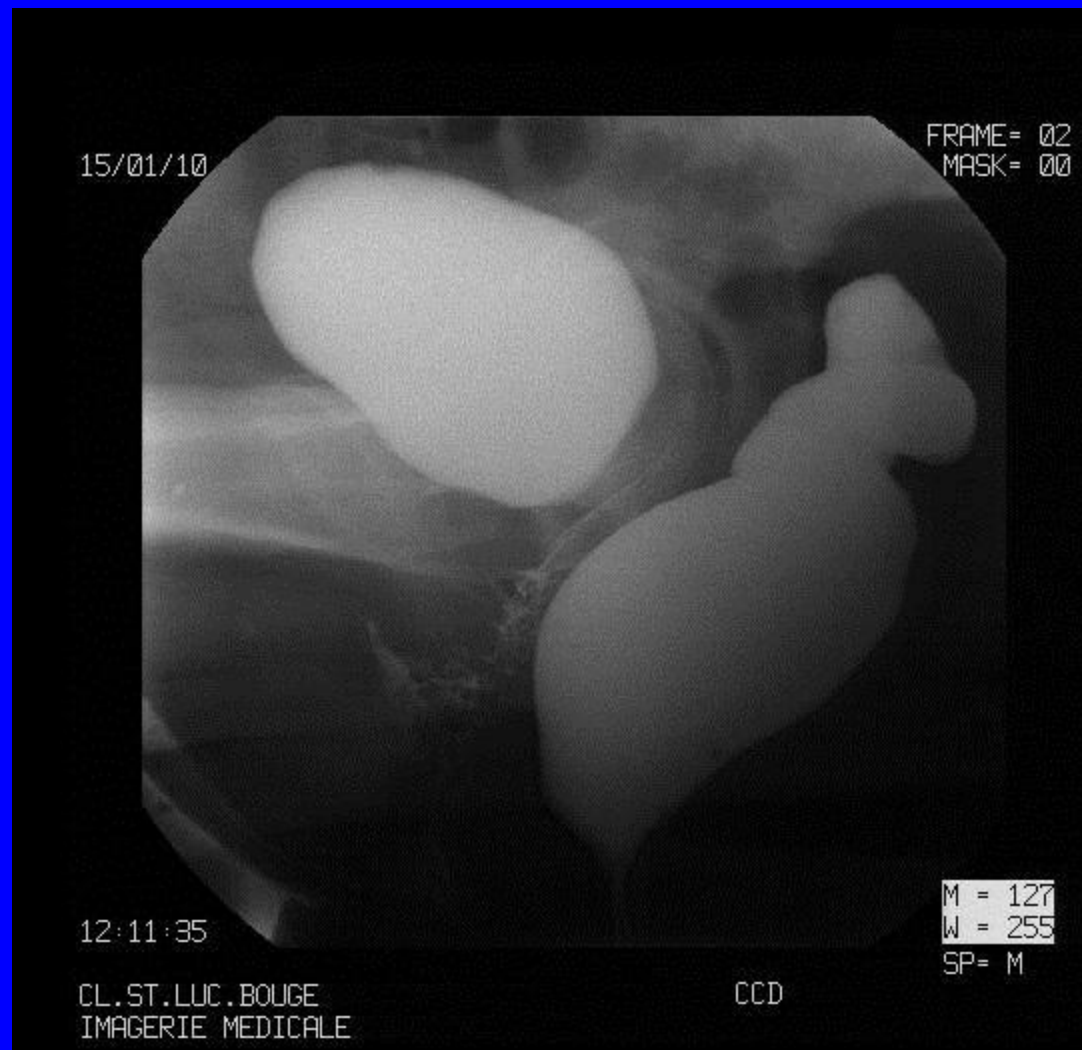




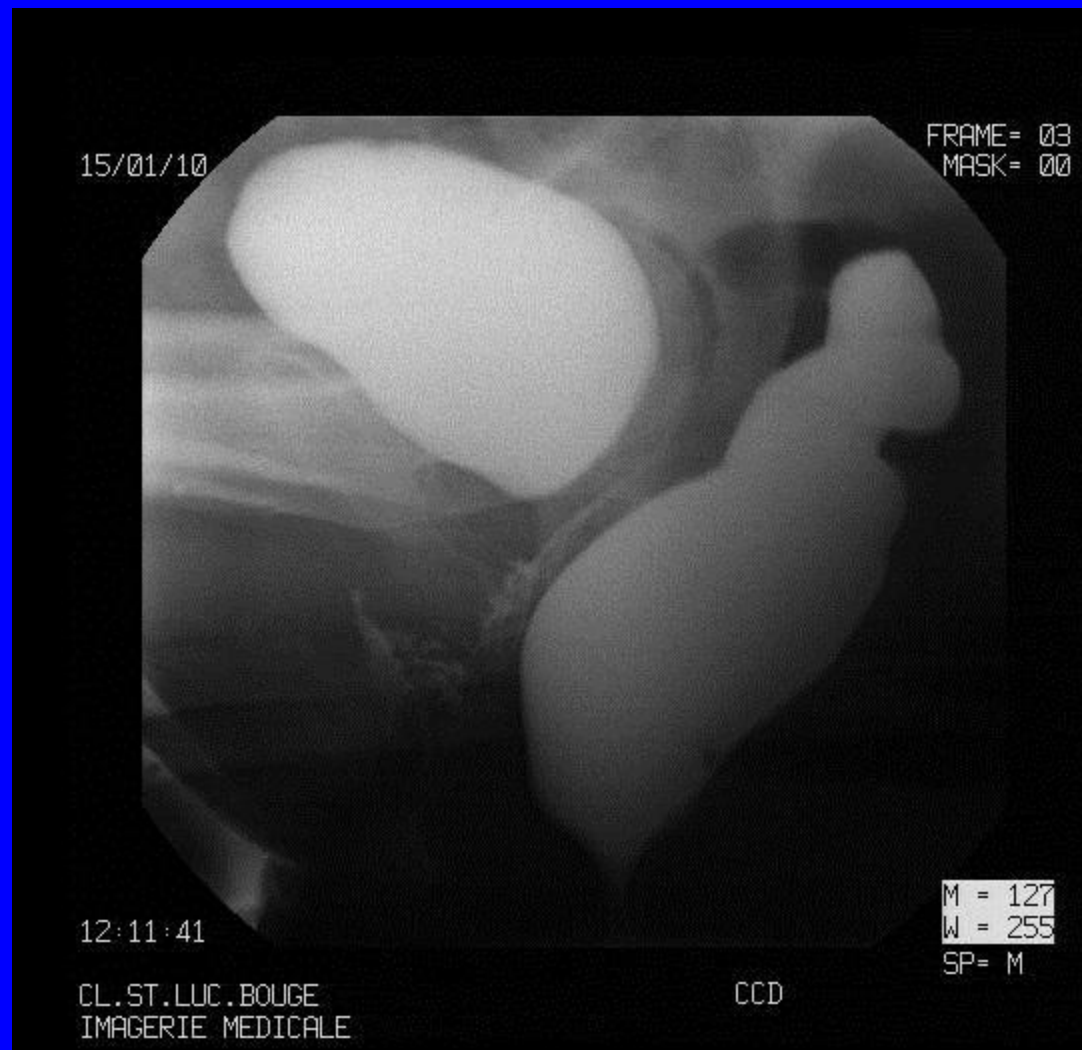
Service d'Imagerie Médicale  
Clinique Saint Luc Bouge



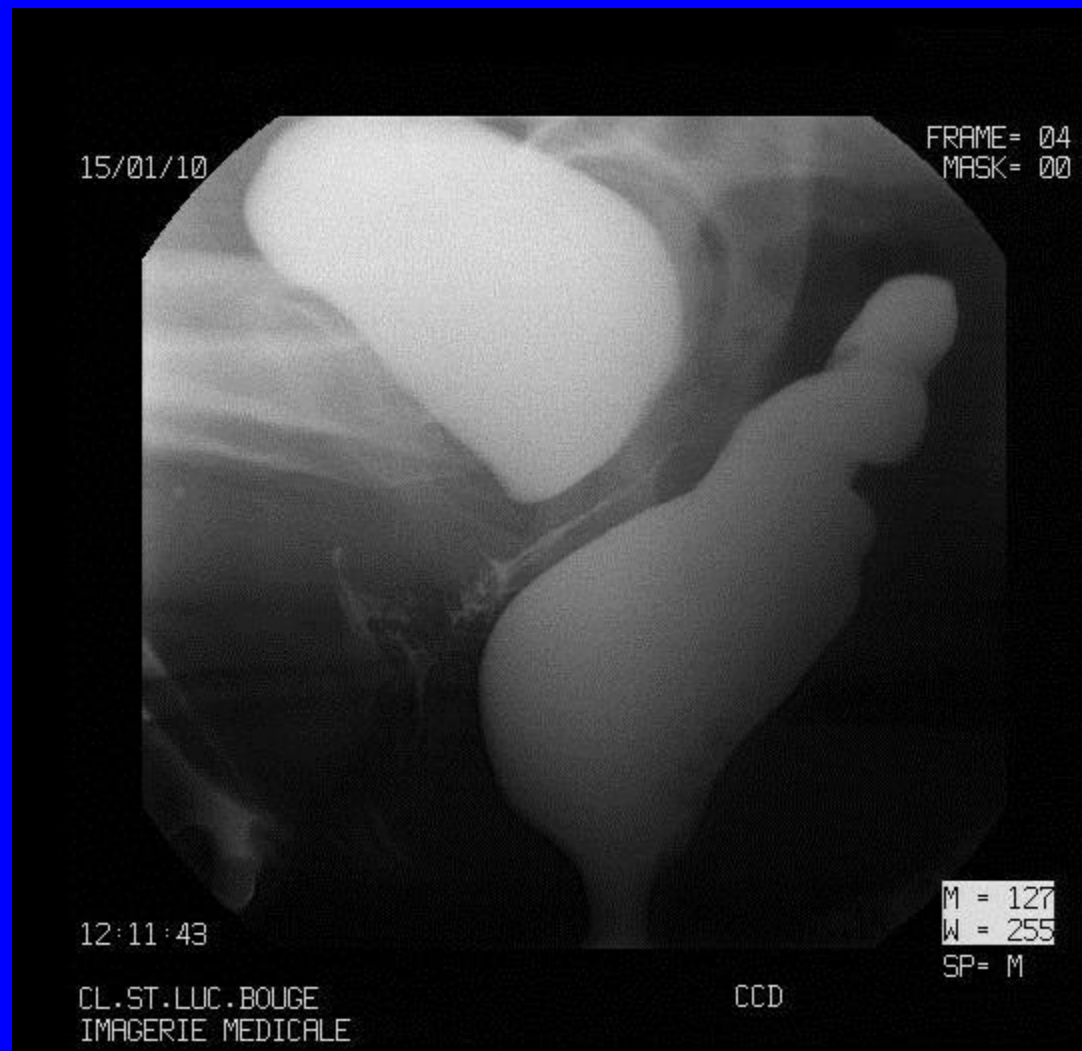


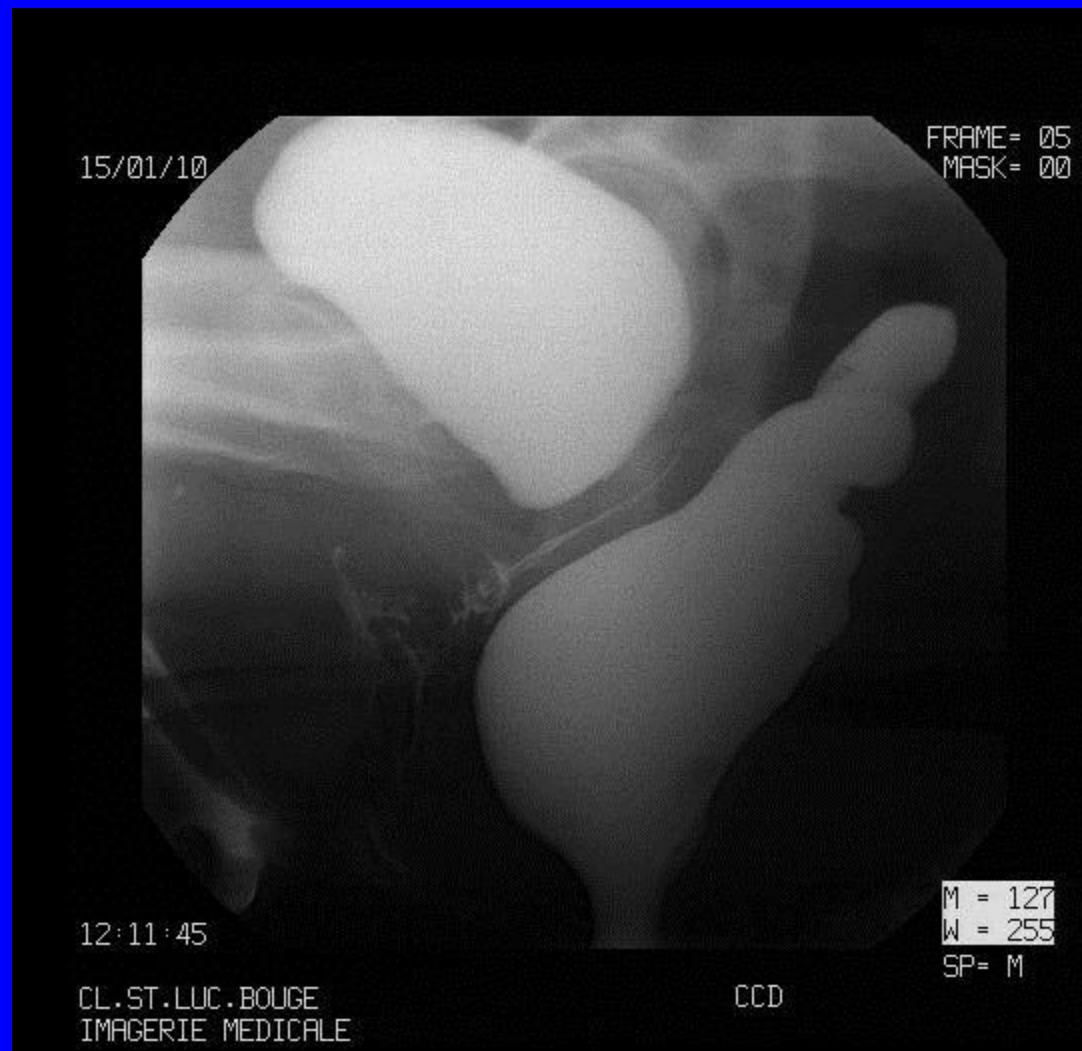
Service d'Imagerie Médicale  
Clinique Saint Luc Bouge

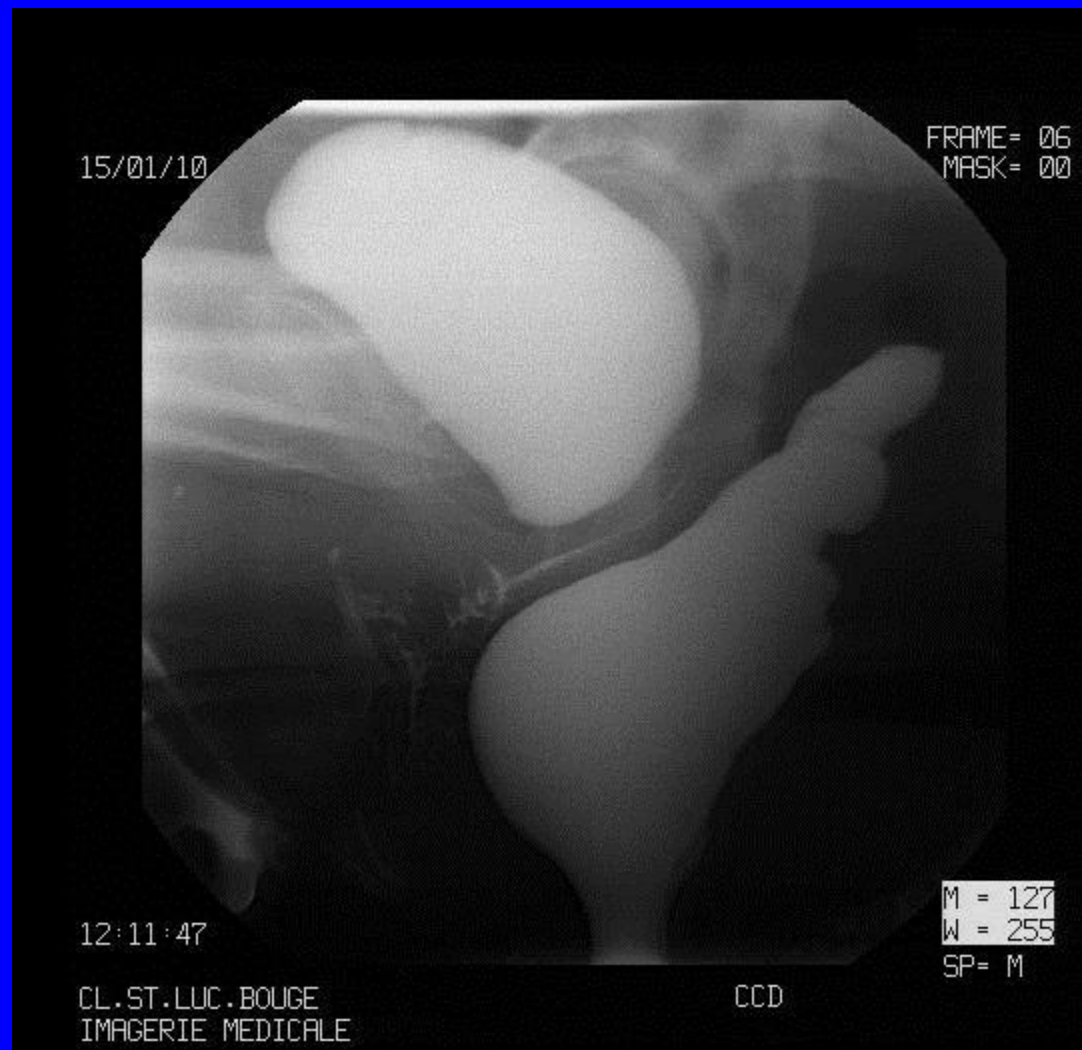




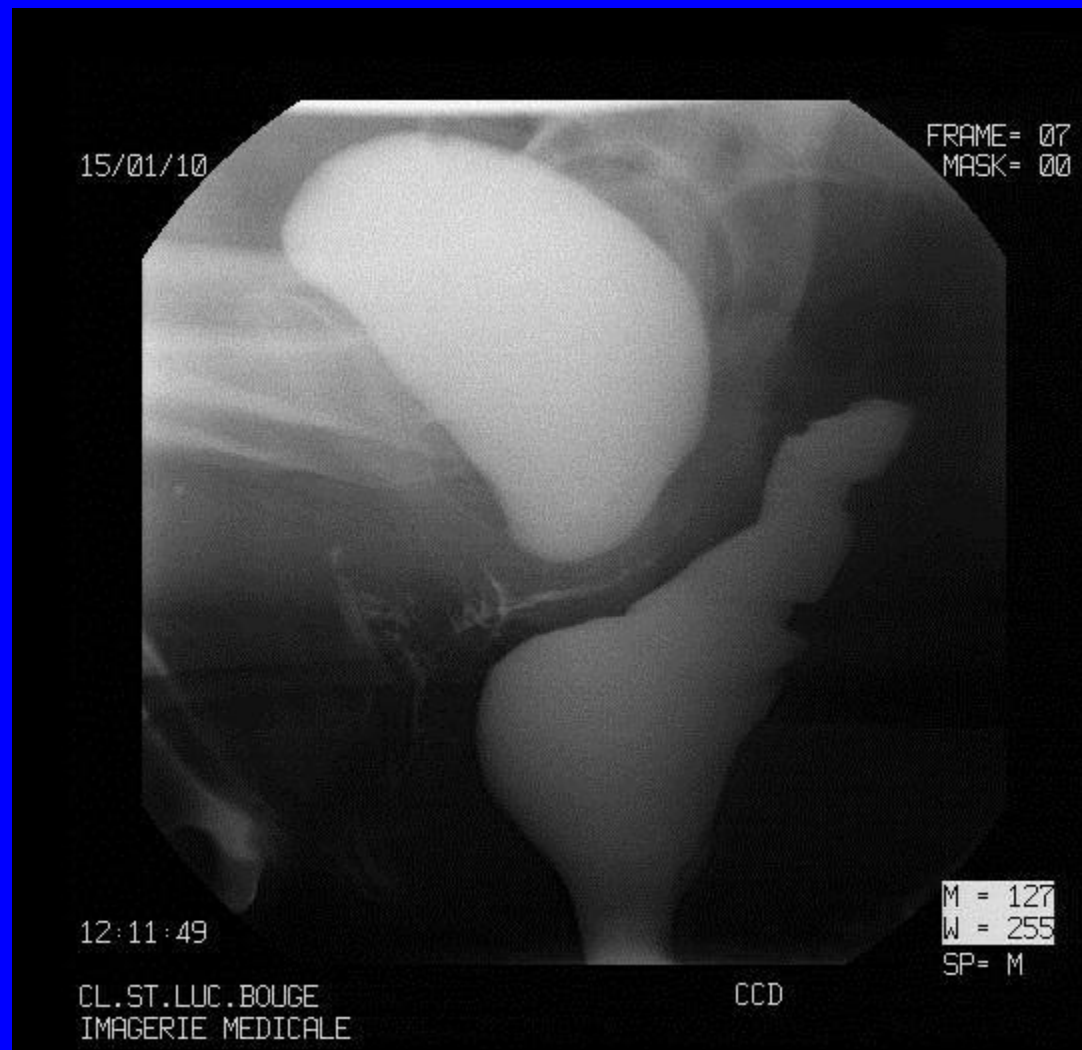


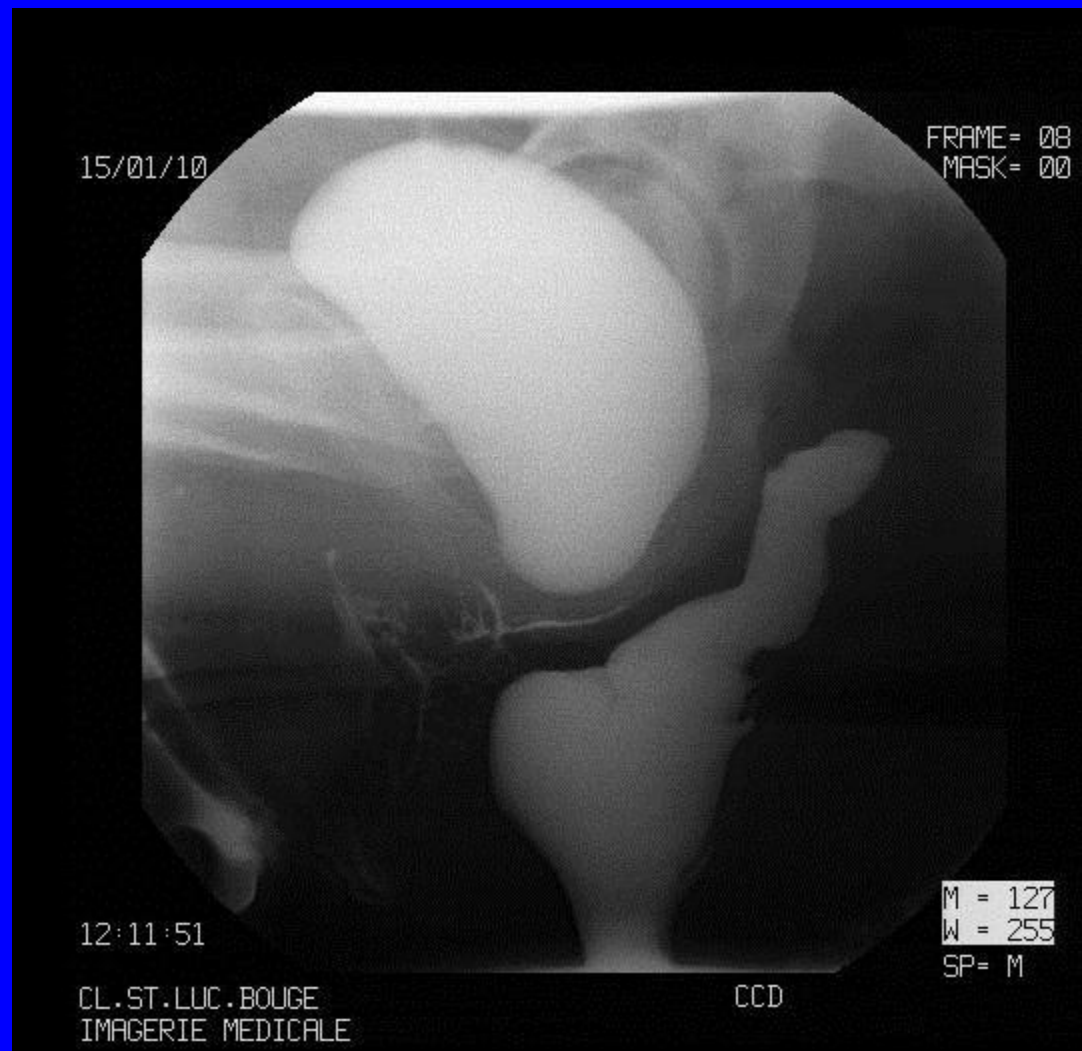Service d'Imagerie Médicale  
Clinique Saint Luc Bouge



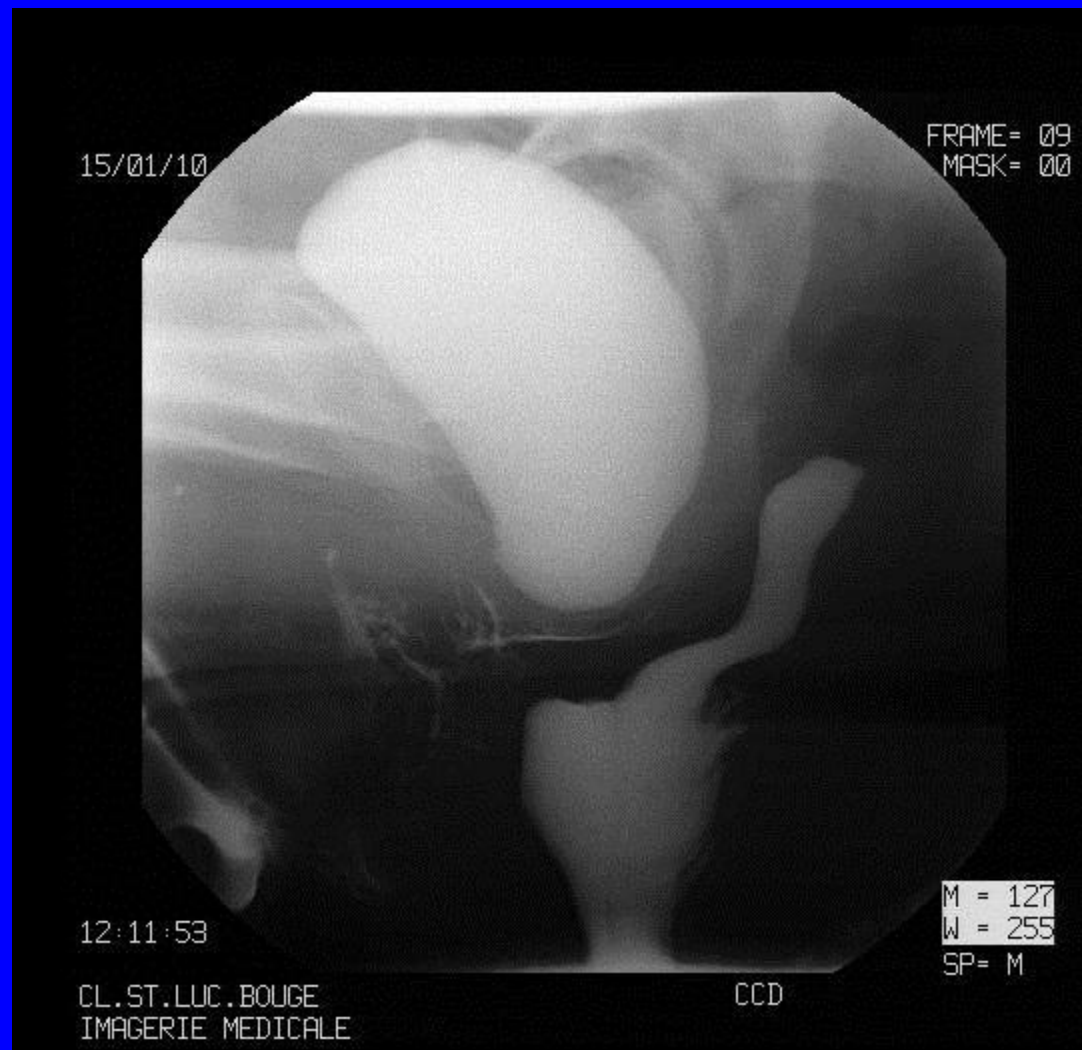



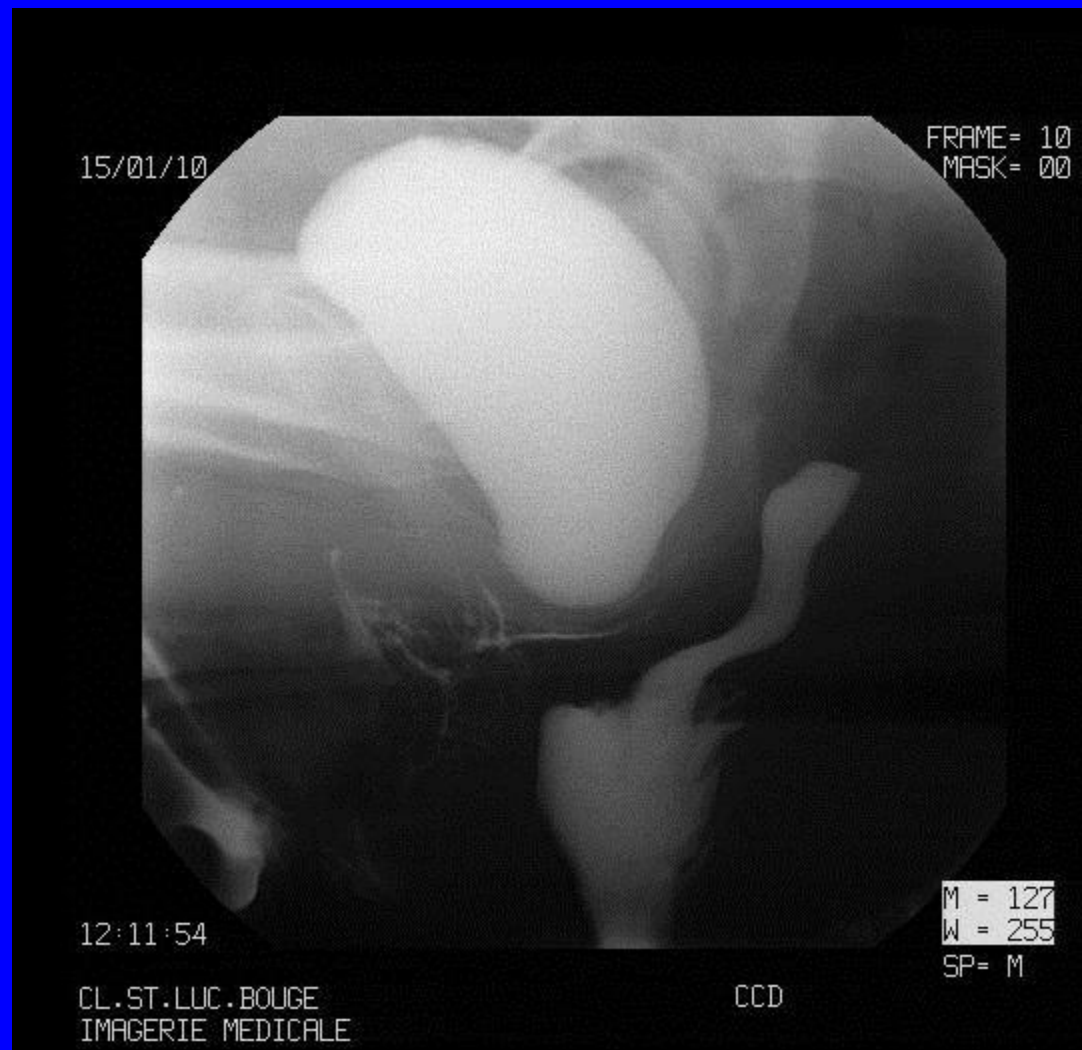Service d'Imagerie Médicale  
Clinique Saint Luc Bouge



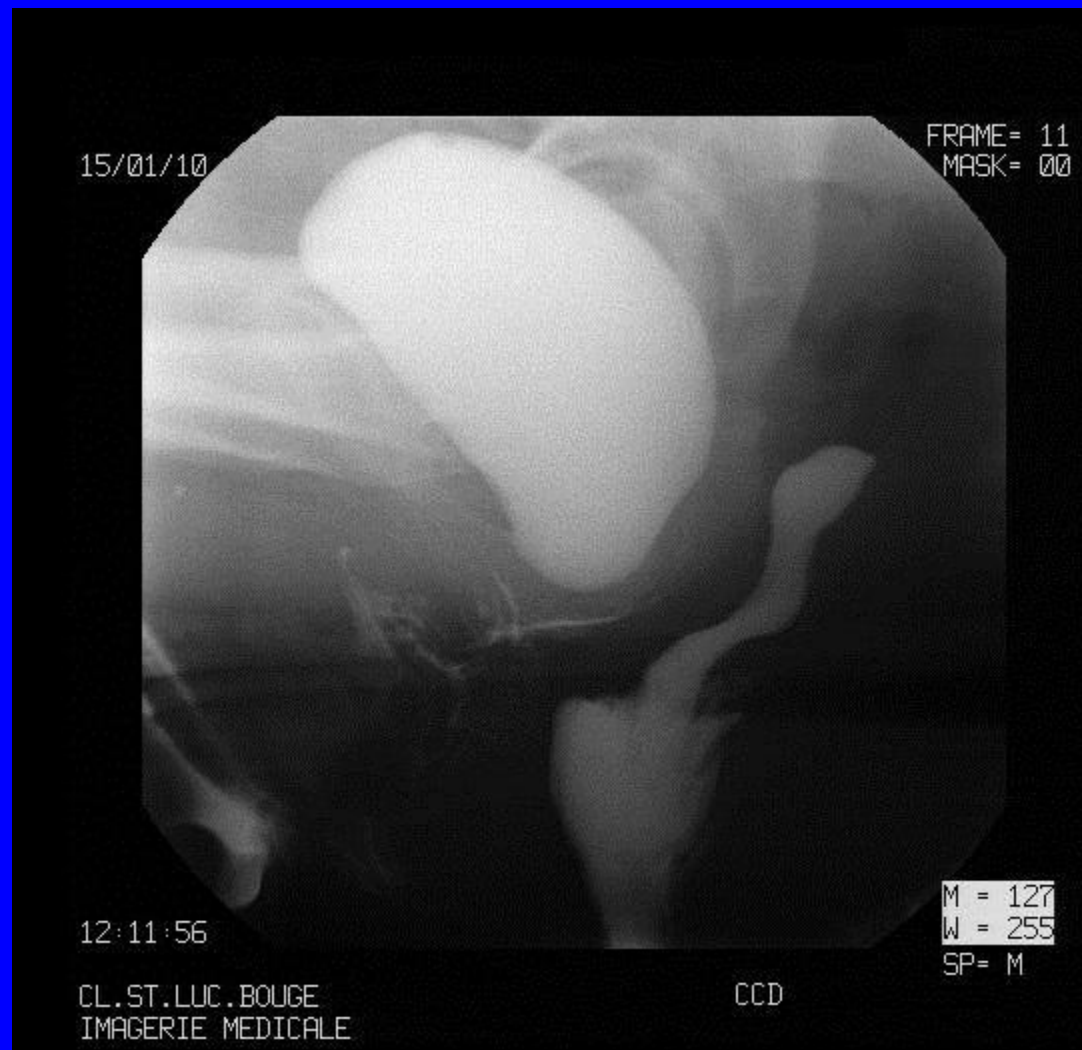Service d'Imagerie Médicale  
Clinique Saint Luc Bouge



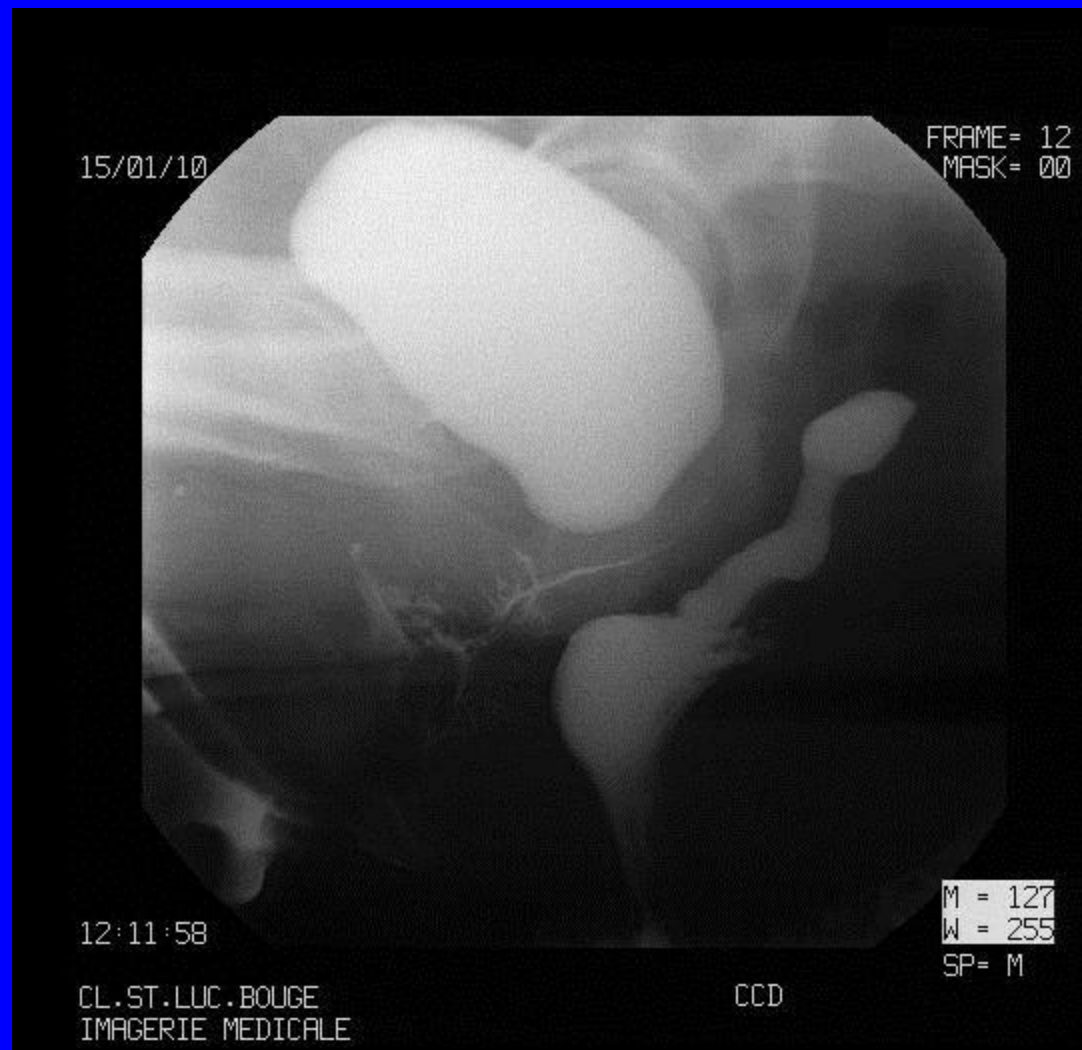Service d'Imagerie Médicale  
Clinique Saint Luc Bouge



Service d'Imagerie Médicale  
Clinique Saint Luc Bouge

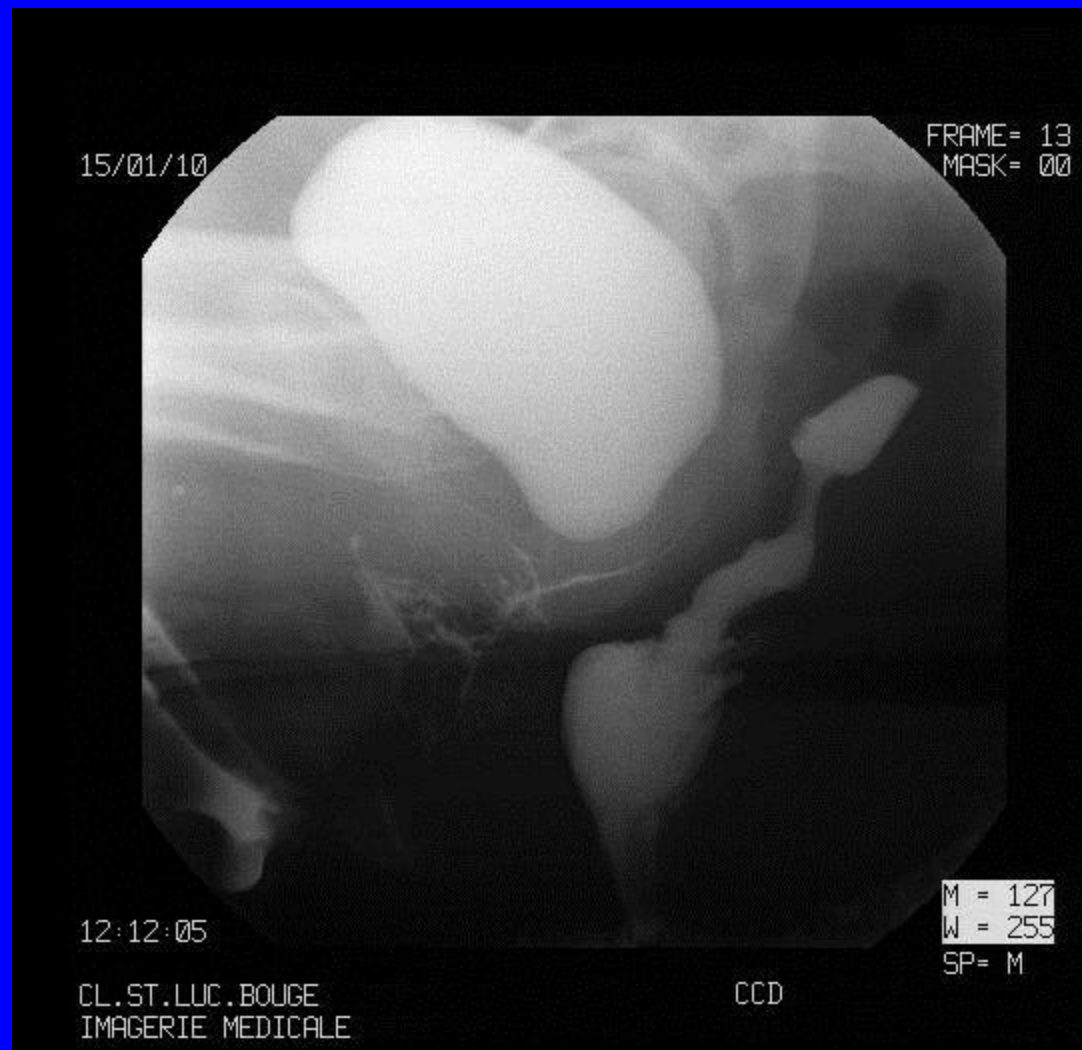

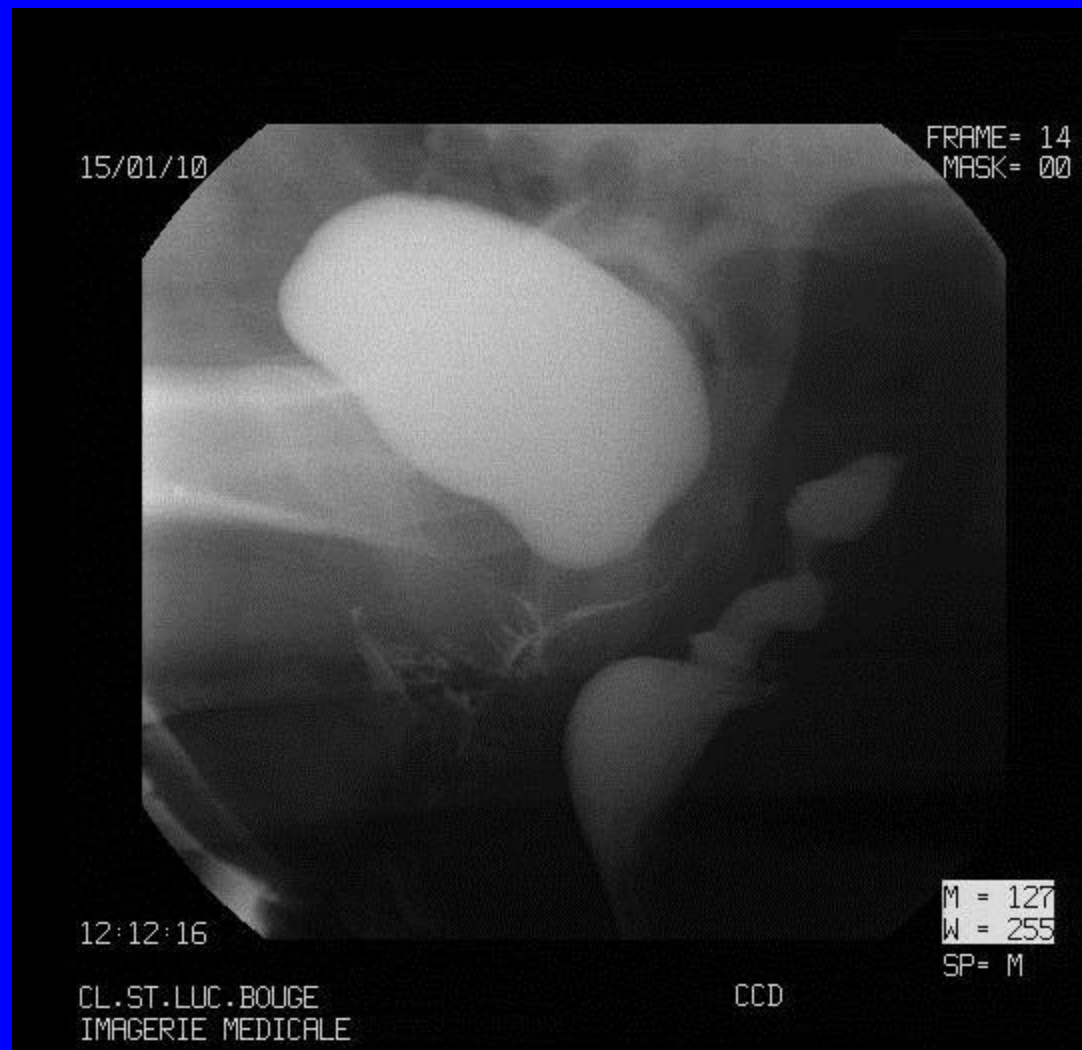
Service d'Imagerie Médicale  
Clinique Saint Luc Bouge



Service d'Imagerie Médicale  
Clinique Saint Luc Bouge

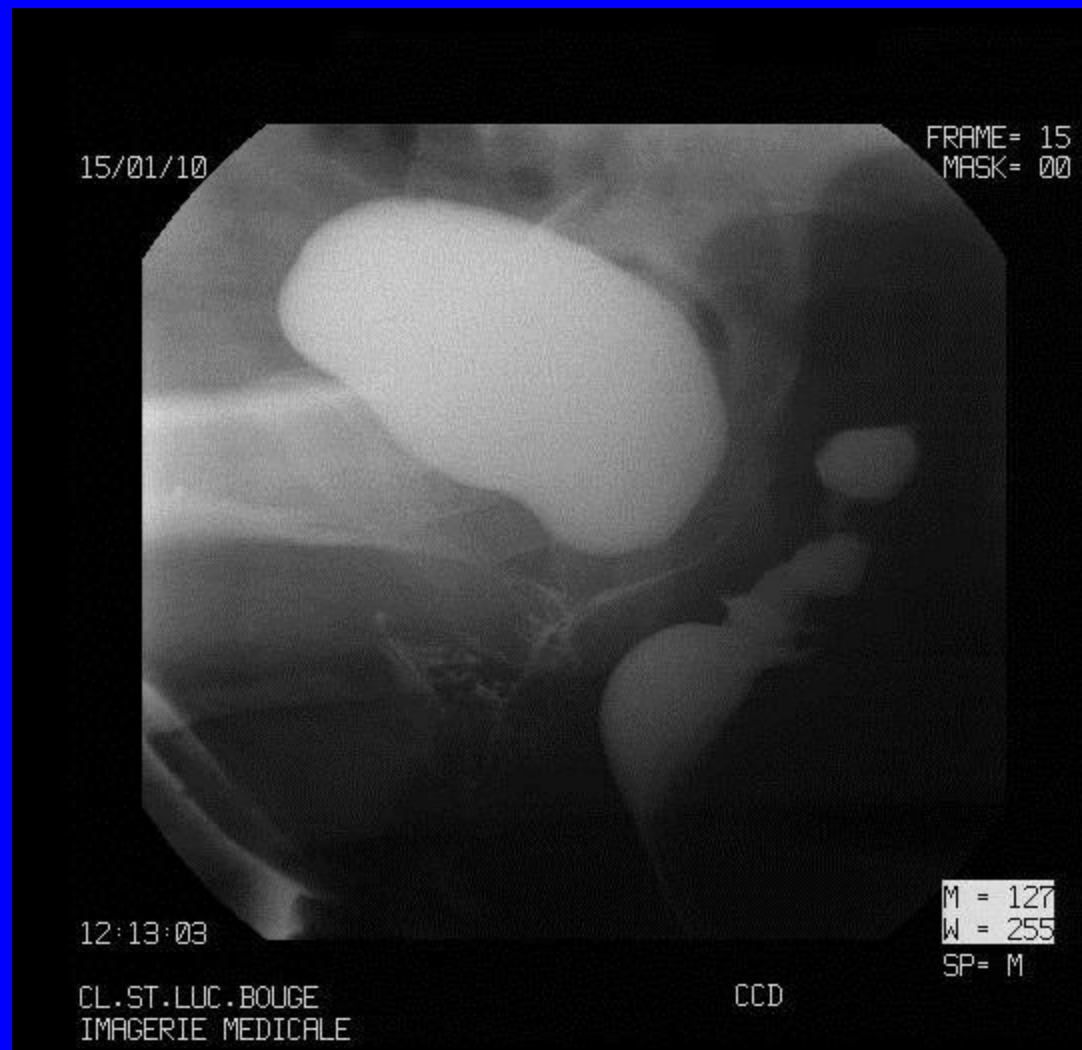




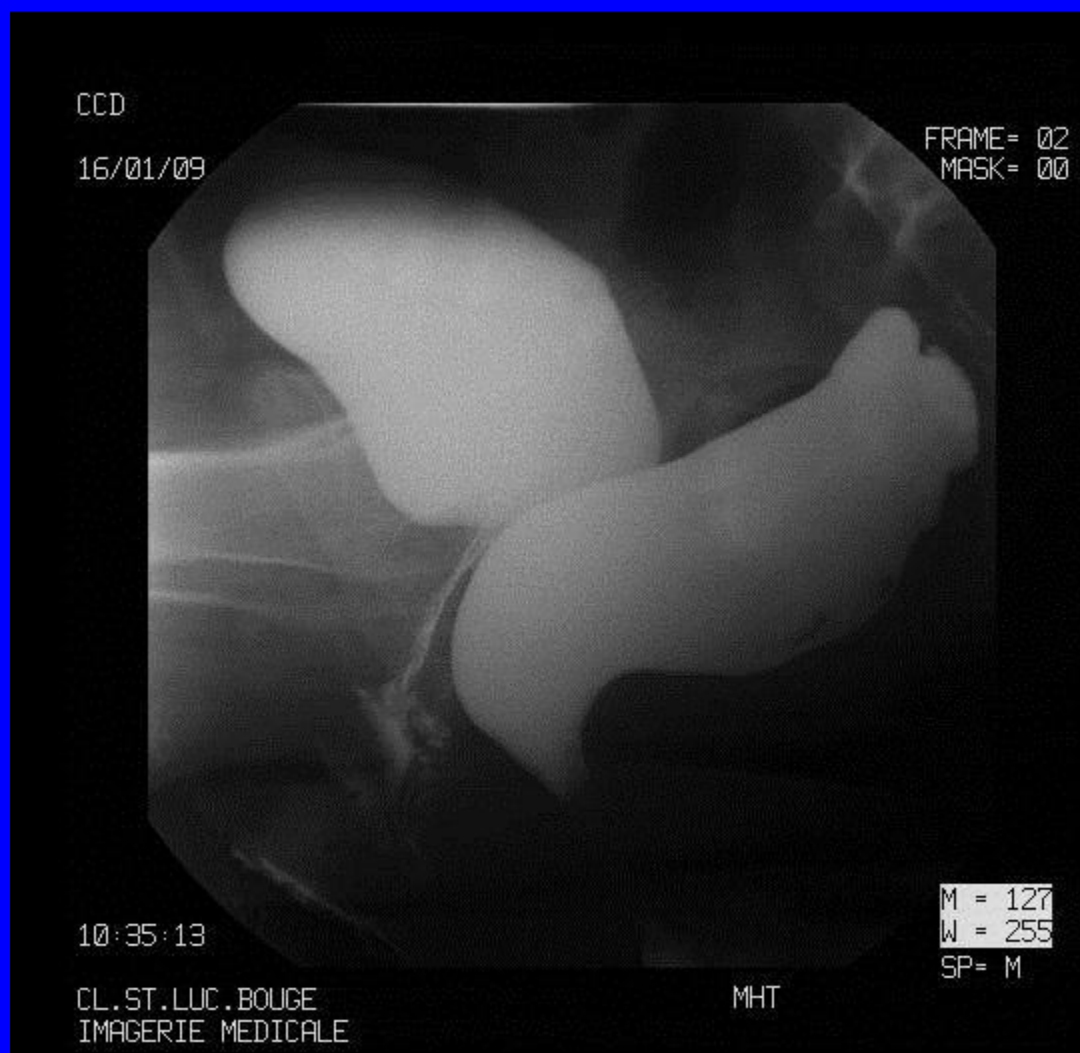


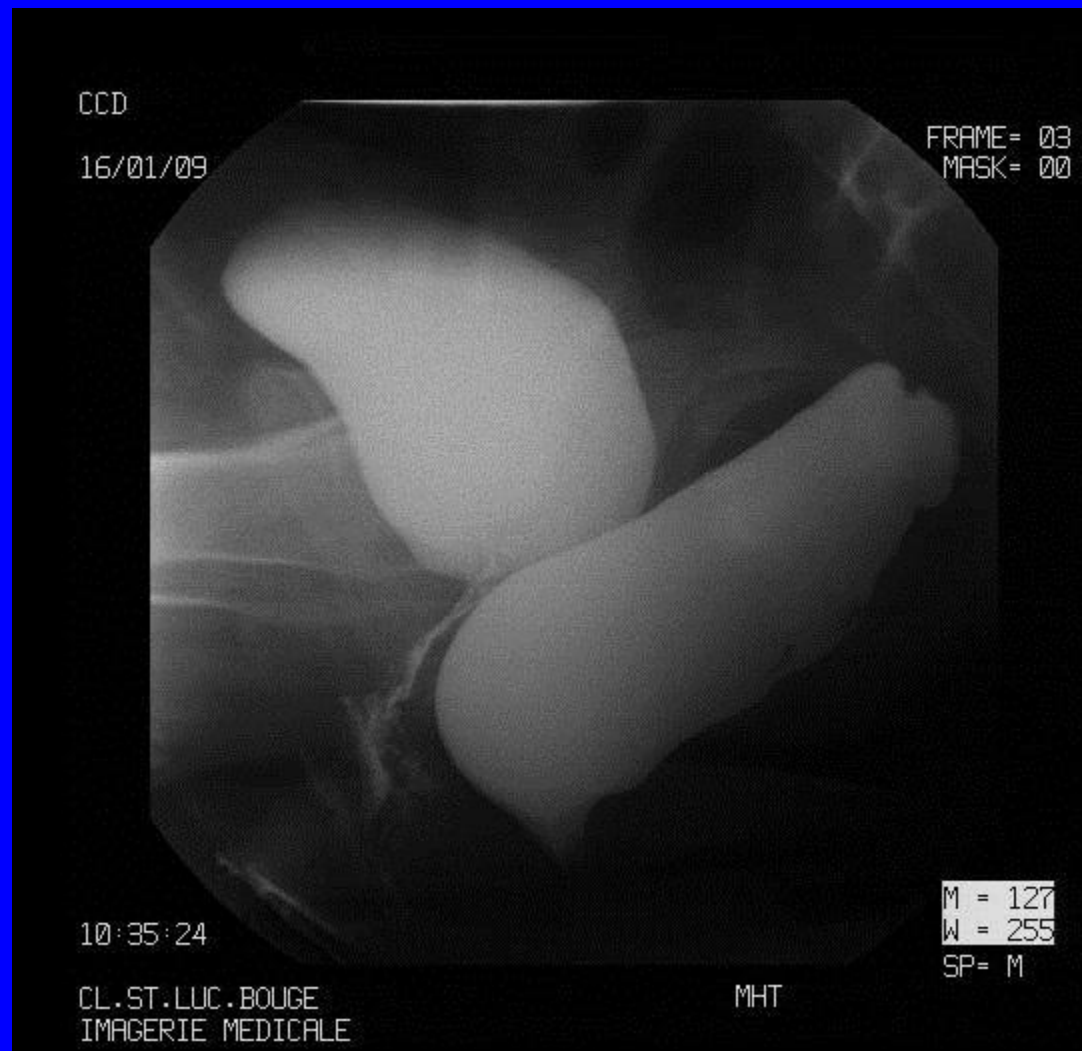Service d'Imagerie Médicale  
Clinique Saint Luc Bouge

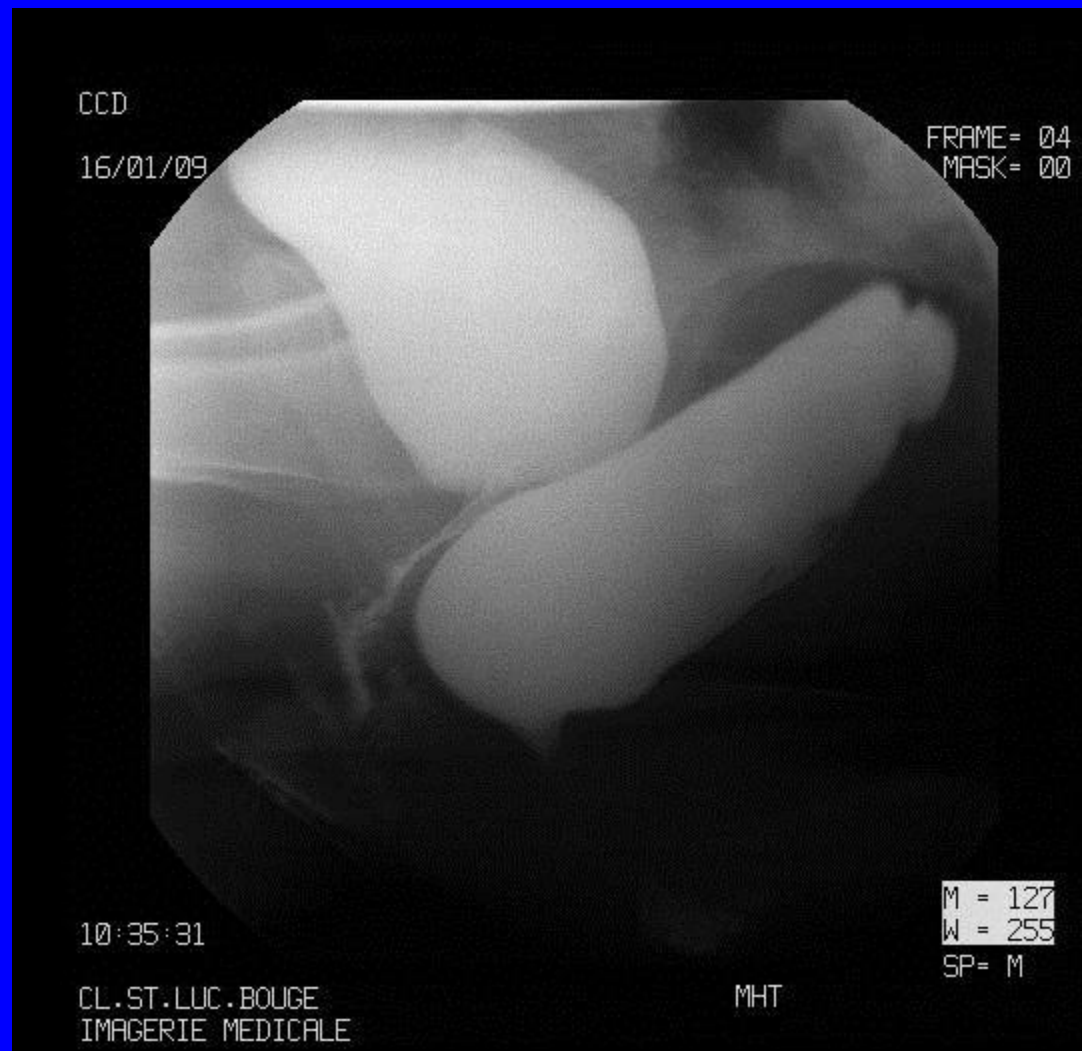

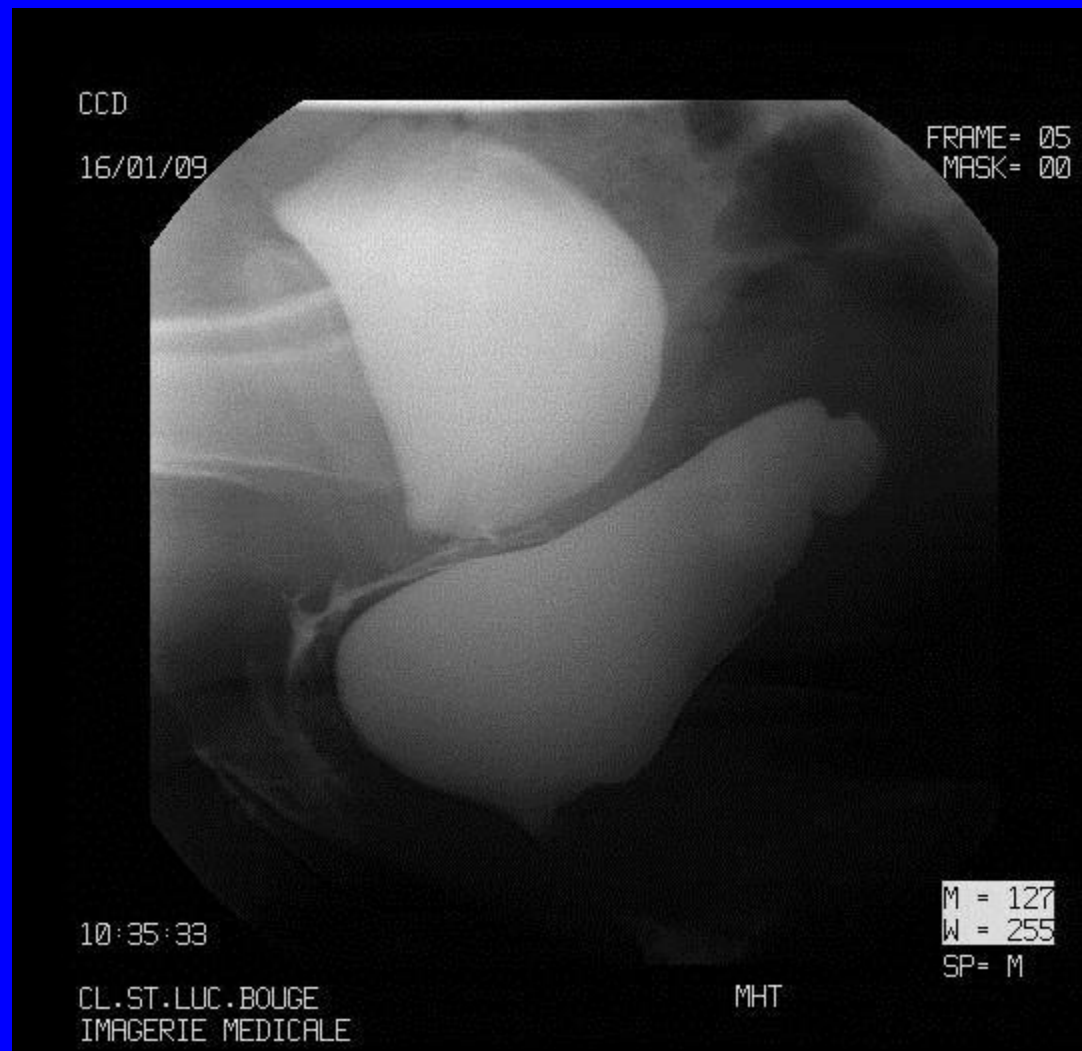



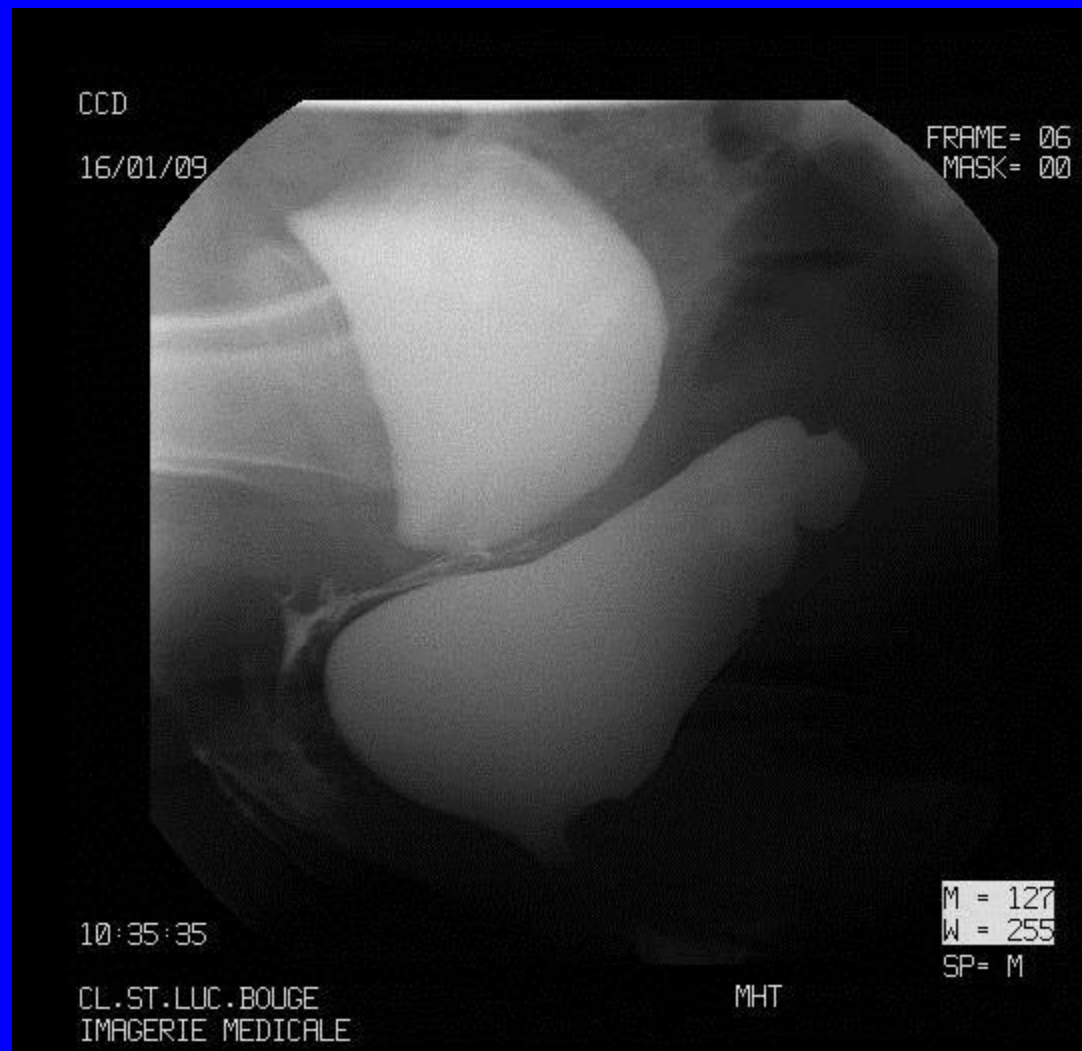




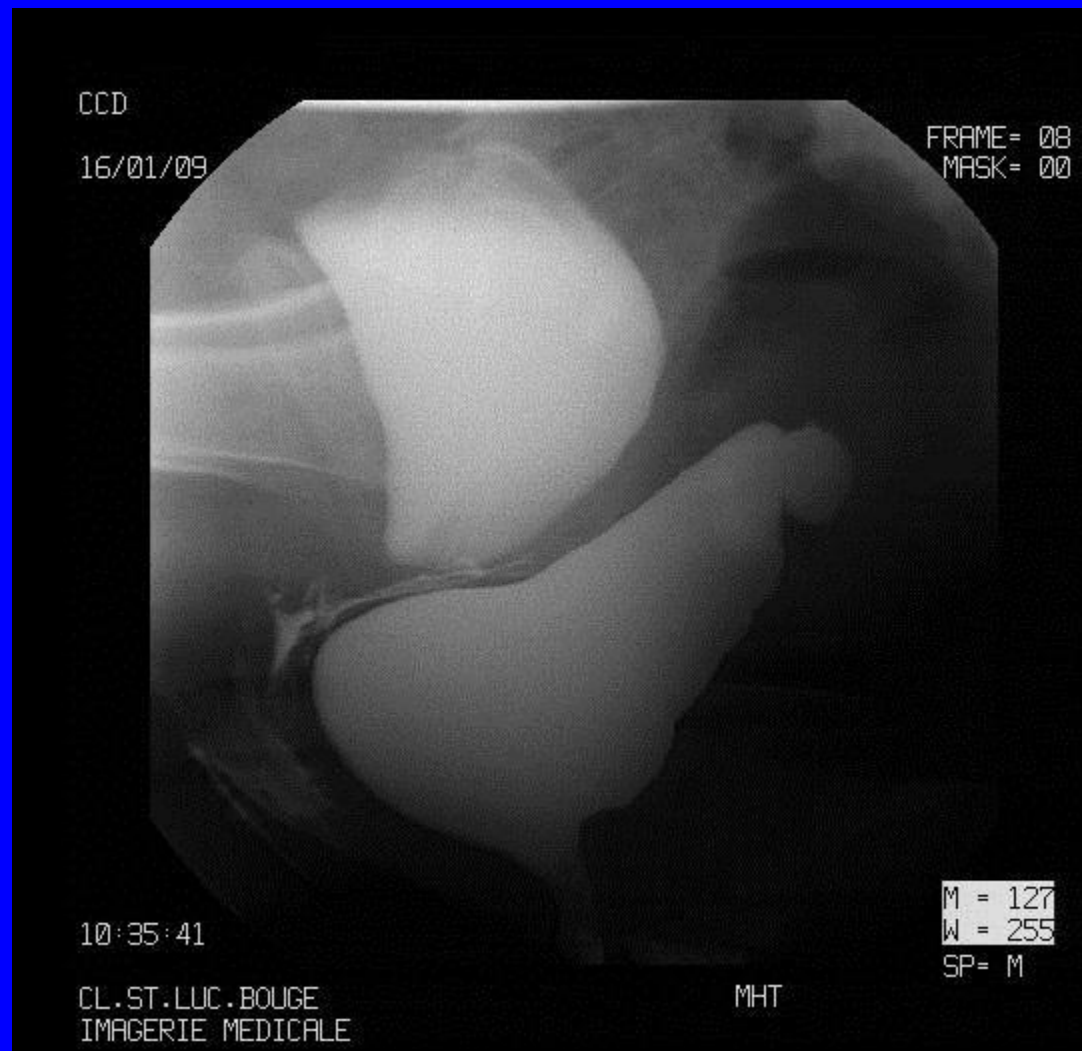




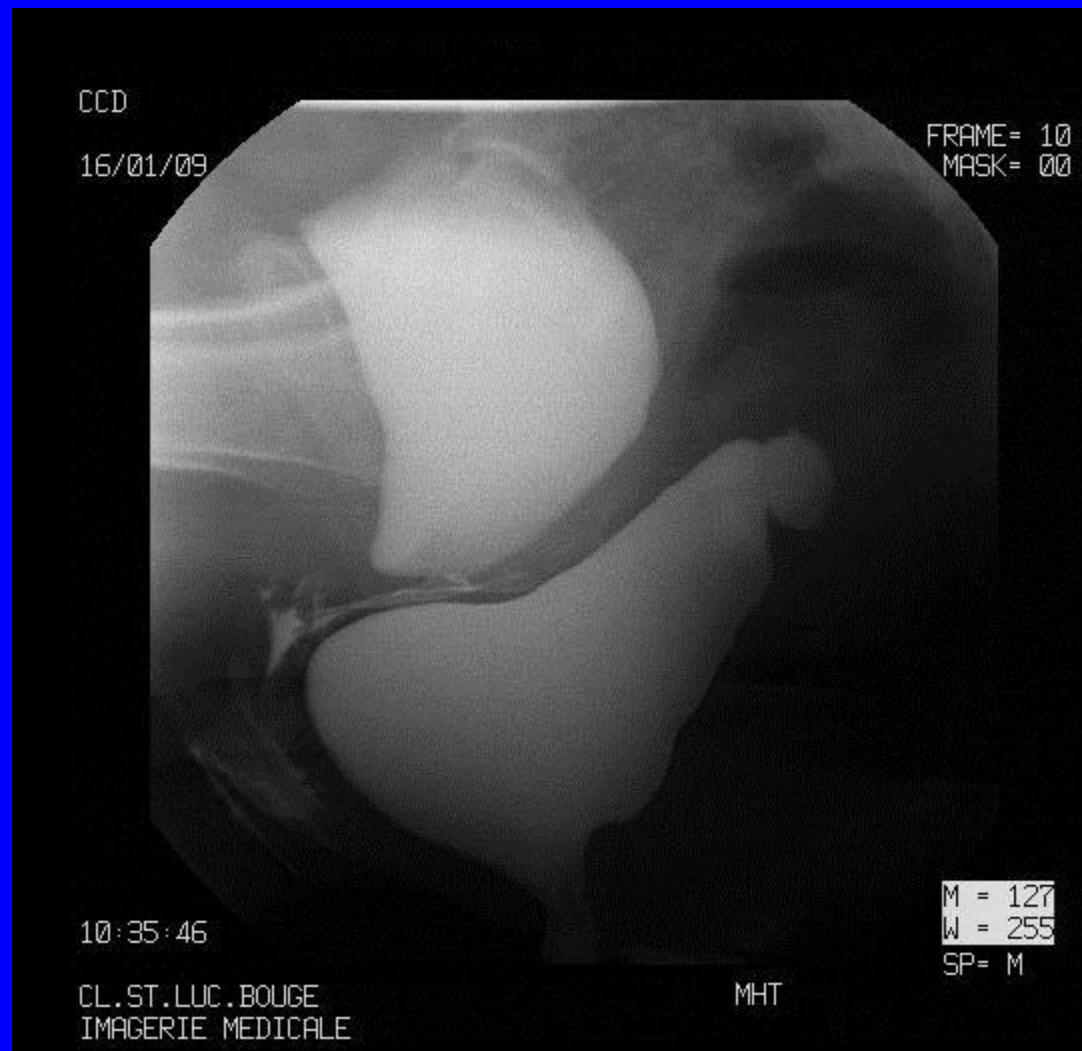




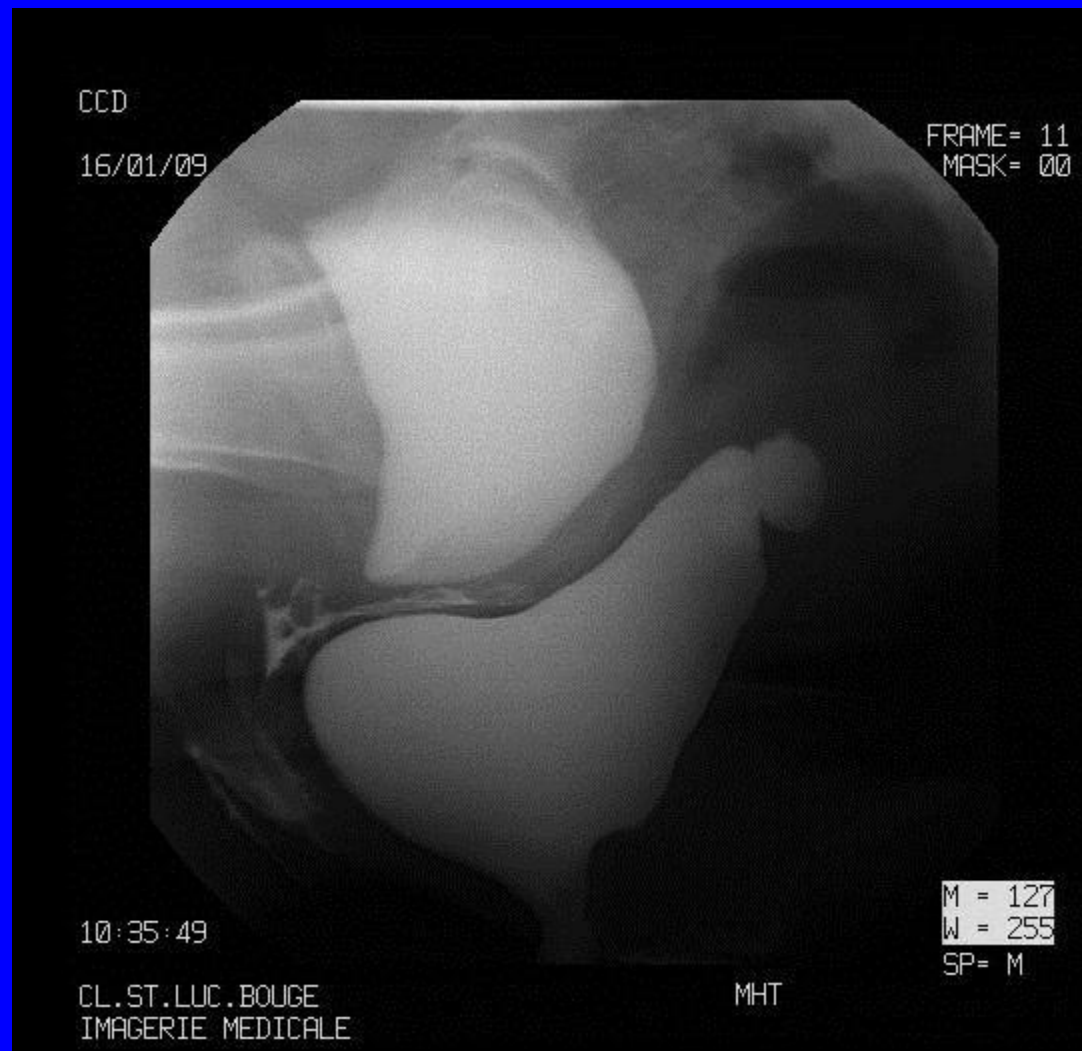


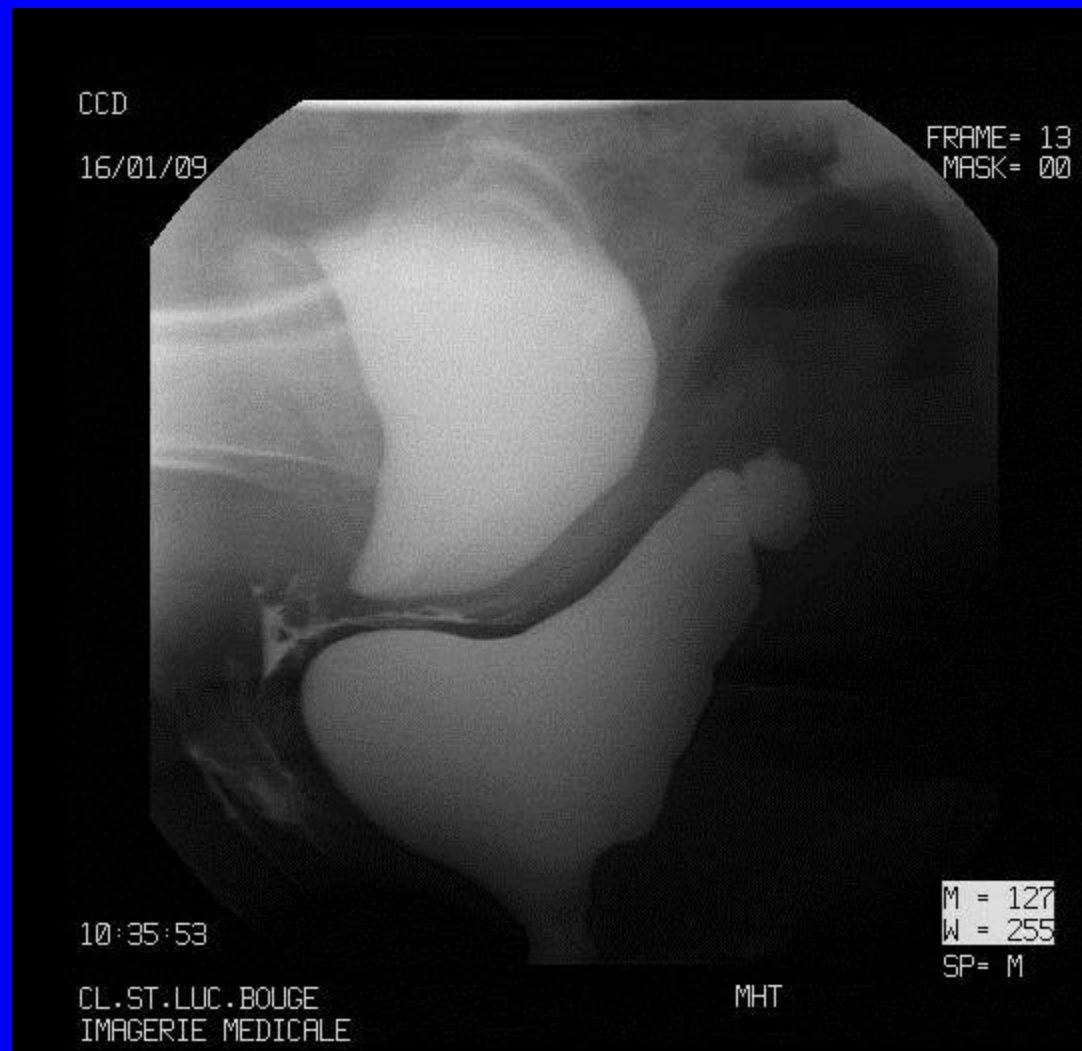
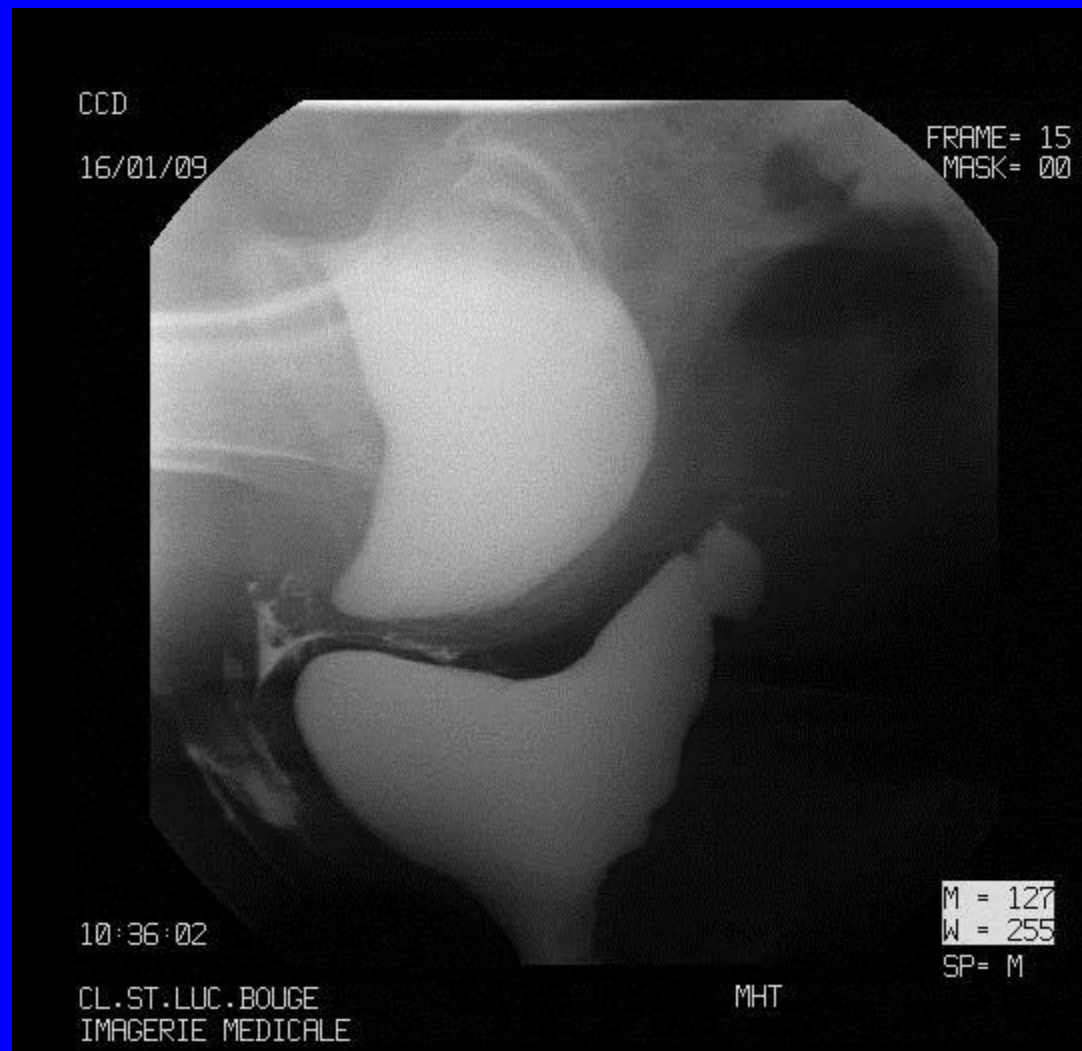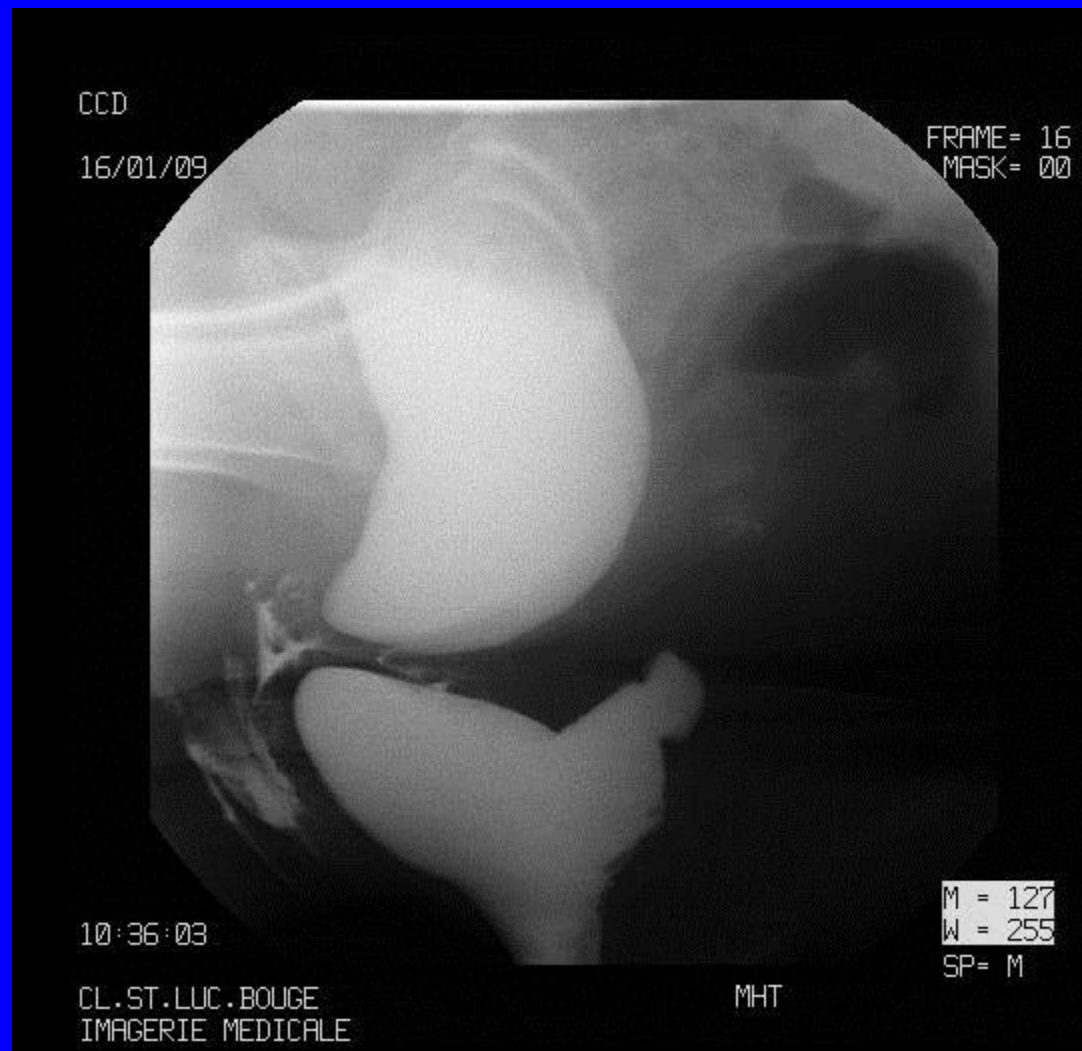Service d'Imagerie Médicale  
Clinique Saint Luc Bouge

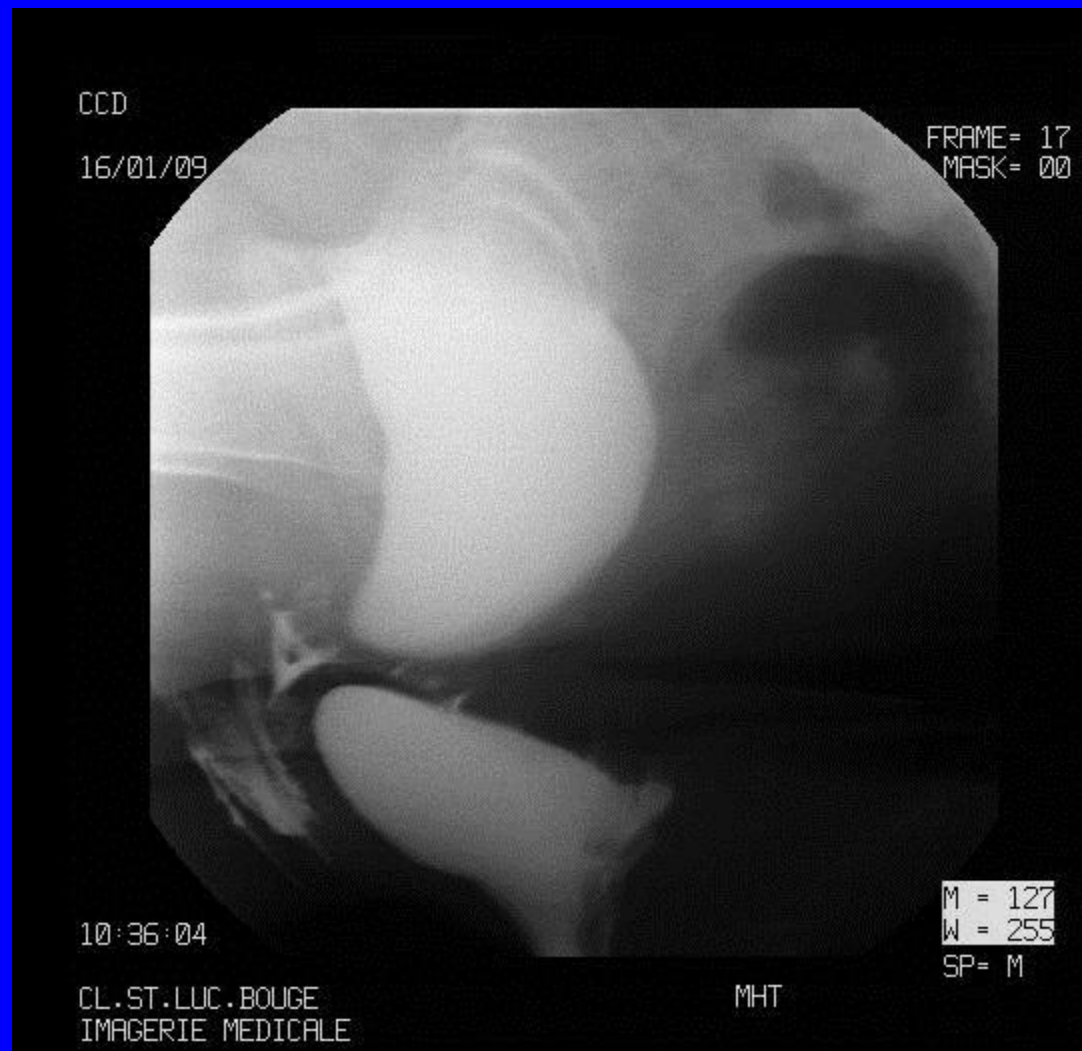




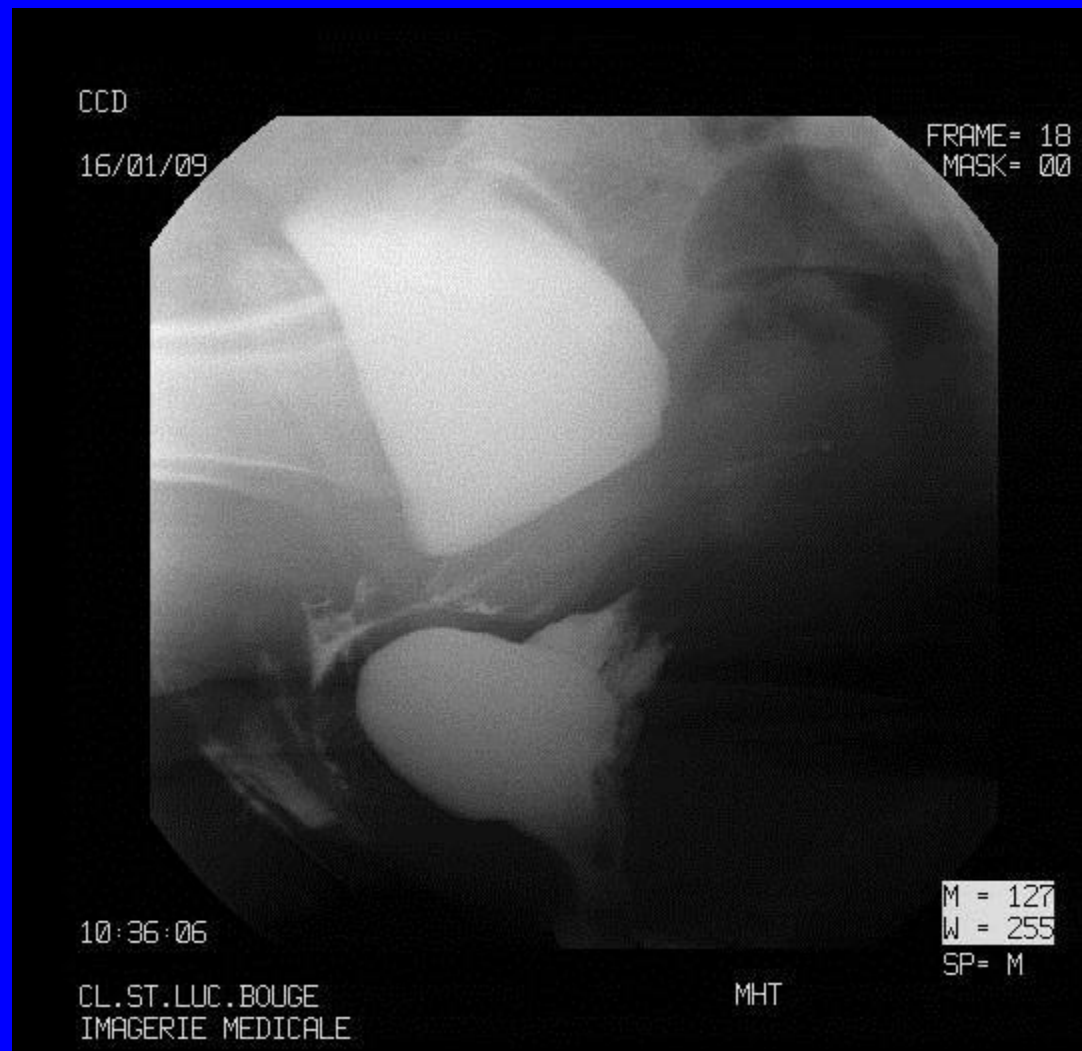


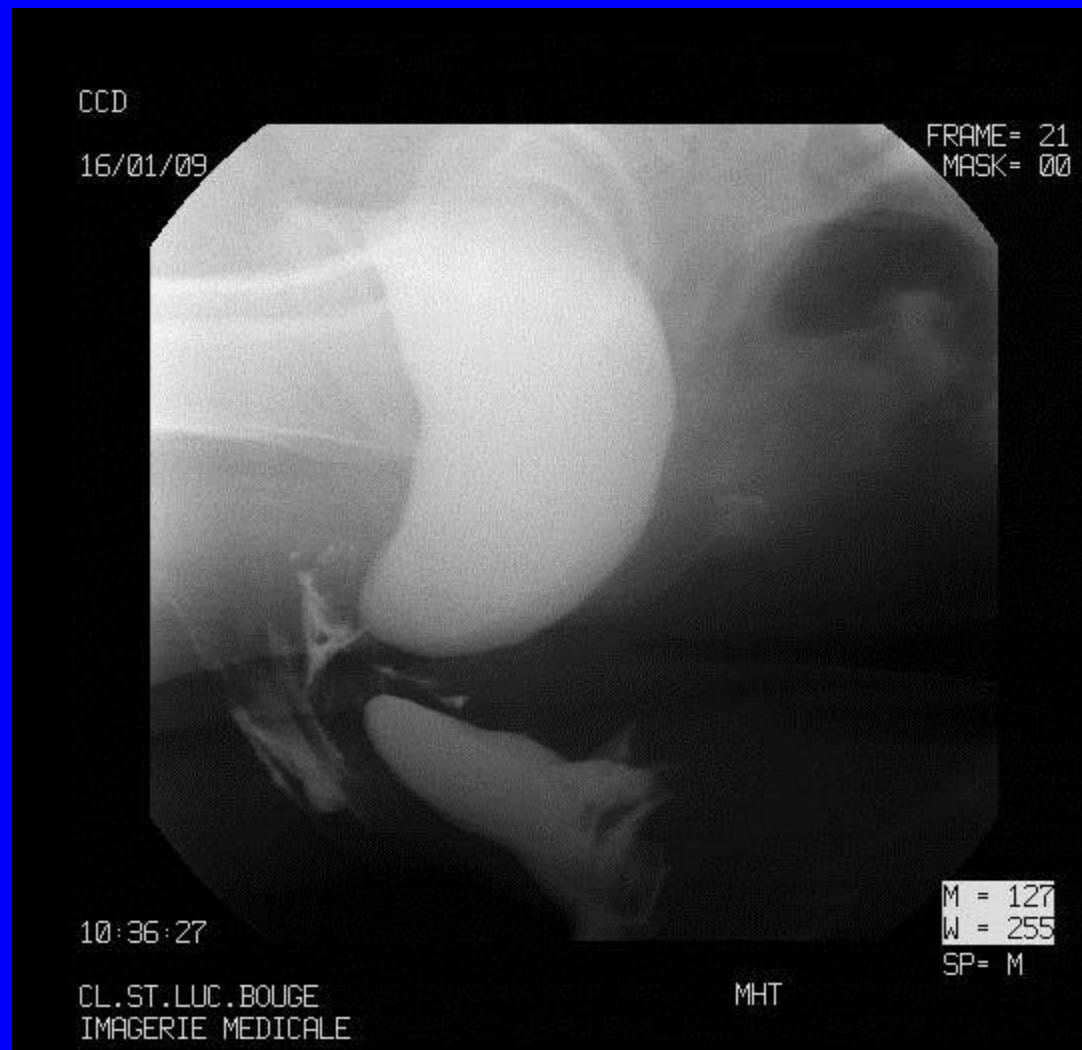Service d'Imagerie Médicale  
Clinique Saint Luc Bouge

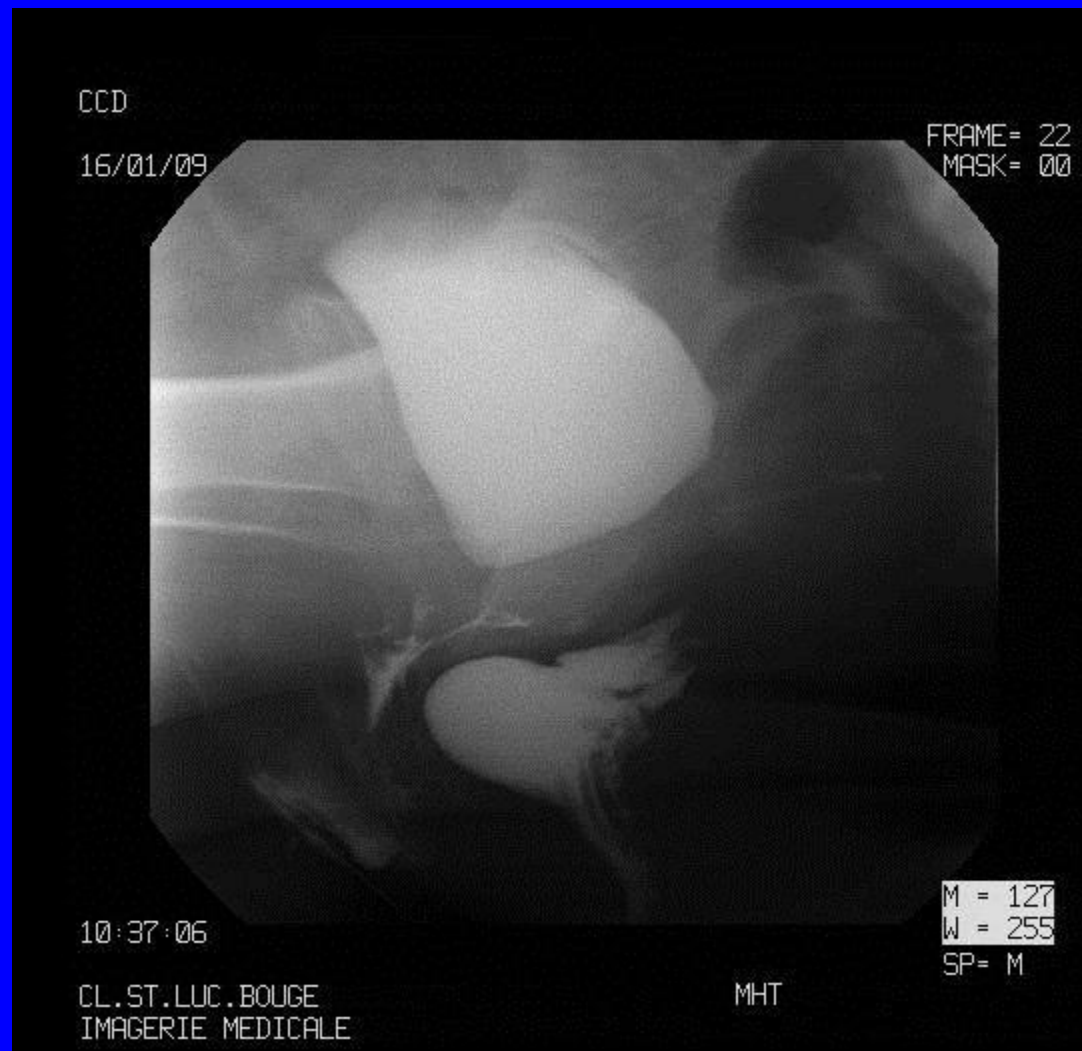


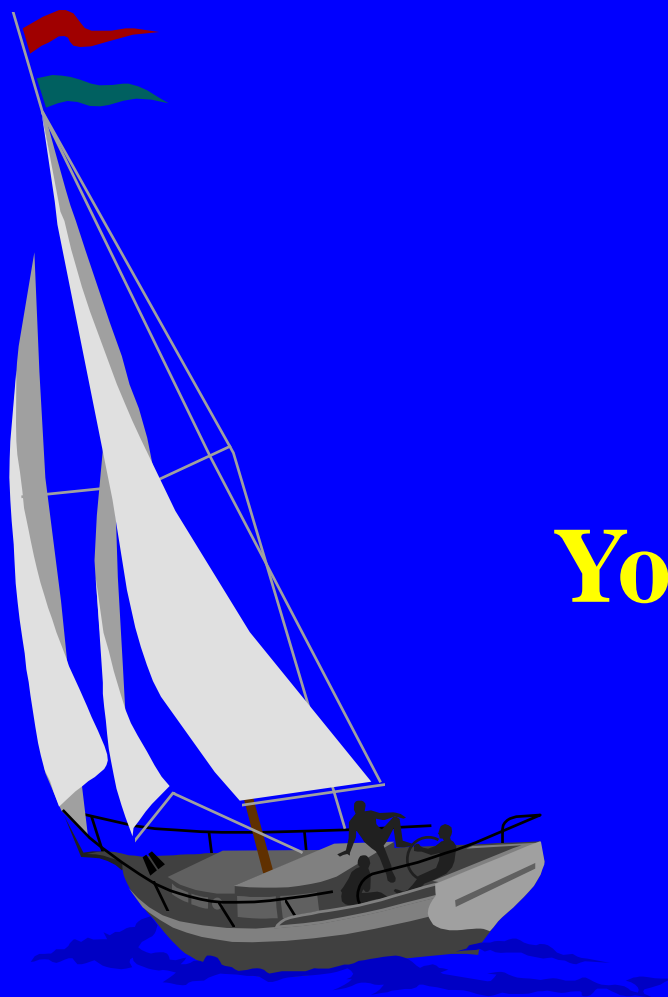











**Thanks  
for  
Your Attention !**